This is a digital copy of a book that was preserved for generations on library shelves before it was carefully scanned by Google as part of a project to make the world's books discoverable online.

It has survived long enough for the copyright to expire and the book to enter the public domain. A public domain book is one that was never subject to copyright or whose legal copyright term has expired. Whether a book is in the public domain may vary country to country. Public domain books are our gateways to the past, representing a wealth of history, culture and knowledge that's often difficult to discover.

Marks, notations and other marginalia present in the original volume will appear in this file - a reminder of this book's long journey from the publisher to a library and finally to you.

Usage guidelines

Google is proud to partner with libraries to digitize public domain materials and make them widely accessible. Public domain books belong to the public and we are merely their custodians. Nevertheless, this work is expensive, so in order to keep providing this resource, we have taken steps to prevent abuse by commercial parties, including placing technical restrictions on automated querying.

We also ask that you:

+ *Make non-commercial use of the files* We designed Google Book Search for use by individuals, and we request that you use these files for personal, non-commercial purposes.
+ *Refrain from automated querying* Do not send automated queries of any sort to Google's system: If you are conducting research on machine translation, optical character recognition or other areas where access to a large amount of text is helpful, please contact us. We encourage the use of public domain materials for these purposes and may be able to help.
+ *Maintain attribution* The Google "watermark" you see on each file is essential for informing people about this project and helping them find additional materials through Google Book Search. Please do not remove it.
+ *Keep it legal* Whatever your use, remember that you are responsible for ensuring that what you are doing is legal. Do not assume that just because we believe a book is in the public domain for users in the United States, that the work is also in the public domain for users in other countries. Whether a book is still in copyright varies from country to country, and we can't offer guidance on whether any specific use of any specific book is allowed. Please do not assume that a book's appearance in Google Book Search means it can be used in any manner anywhere in the world. Copyright infringement liability can be quite severe.

About Google Book Search

Google's mission is to organize the world's information and to make it universally accessible and useful. Google Book Search helps readers discover the world's books while helping authors and publishers reach new audiences. You can search through the full text of this book on the web at `http://books.google.com/`

UC-NRLF
B 3 960 208

THE HEALTH SCIENCES LIBRARY
UNIVERSITY OF CALIFORNIA, DAVIS

THE

TRANSACTIONS

OF THE

AMERICAN OTOLOGICAL SOCIETY.

VOLUME I.

1868-1874.

BOSTON:
FOR SALE BY JAMES CAMPBELL. 18 TREMONT ST.
1875.

Medical
RF1
A56
v. 1
1868

PREFACE.

UNTIL within a very few years, the science and art of Otology had been almost entirely neglected by the medical profession of the United States. In this respect, however, we were not much behind most other parts of the civilized world.

In its very best position, Otology was an appendage, not always very gracefully worn, to the Department of Opthalmology; for in this country, as in Ireland, diseases of the Eye and Ear have always been connected, both in the minds of the profession and the laity. The Ophthalmological Society of the City of New York thus has for its object the cultivation of both ophthalmic and aural science.

After the American Ophthalmological Society had proved itself a useful organization, and had become firmly established, the question of amending its constitution so as to admit of the discussion of aural subjects, was considered by the members, nearly all of whom were engaged in the practice of both Ophthalmology and Otology. It was proposed to devote one day of the annual sessions of the Society to aural medicine and surgery; but it was finally decided that such a union could not produce satisfactory results. Consequently, on the 22d of July, 1868, the American Otological Society was organized by certain members of the American Ophthalmological Society, who were then at Newport, Rhode Island, in attendance upon the fifth meeting of the latter. Their names will be found in the minutes of the first meeting, which are printed in this volume.

As will be seen by reference to the record, no scientific business was then transacted; but at each subsequent annual meeting papers have been read and discussions held. It is believed that these articles and debates have contributed essentially to the interest in aural science that now obtains in this country and abroad; and it is confidently hoped that the Otological Society has but just begun a career which is to continue so long as medical science is cultivated.

NOVEMBER 3, 1874.

THE AMERICAN OTOLOGICAL SOCIETY.

MINUTES FOR 1868.

NEWPORT, R. I., July 22, 1868.

AT the meeting for the formation of the American Otological Society, held July 22, 1868, at the Ocean House, Newport, R. I., the following gentlemen were present, viz. —

DRS	C. R. AGNEW	New York.
	H. D. NOYES	"
	D. B. ST. JOHN ROOSA	"
	F. J. BUMSTEAD	"
	O. D. POMEROY	"
	JOHN GREEN	St. Louis.
	E. WILLIAMS	Cincinnati.
	C. A. ROBERTSON	Albany.
	C. E. RIDER	Rochester.

Dr. E. Williams was elected Chairman, and Dr. C. E. Rider, Secretary.

A Constitution and By-Laws were adopted.

The following gentlemen were then elected members, viz. —

DRS.	SAMUEL L. FRANK	Baltimore.
	J. ORNE GREEN	Boston.
	W. W. MORLAND	"
	CHARLES E. HACKLEY	New York.
	R. F. WEIR	"
	FRANCIS SIMROCK	"
	W. S. LUDLUM	"
	W. F HOLCOMBE	"
	A. D. WILLIAMS	Cincinnati.
	J. F. NOYES	Detroit.
	JOHN H. DIX	Boston.
	E. L. HOLMES	Chicago.

Dr. E. Williams was elected President for the ensuing year, and Dr. C. E. Rider, Recording Secretary and Treasurer.

The President appointed Dr. D. B. St. J. Roosa the Committee on the Progress of Otology.

The Secretary was directed to procure the publication of the Constitution and By-Laws of the Society.

Adjourned, to meet at the Ocean House, Newport, July 20, 1869, at 11 A. M.

C. E. RIDER, *Secretary.*

TRANSACTIONS

of the

American Otological Society

INC.

ONE HUNDRED EIGHTH
ANNUAL MEETING

Hyatt Regency Atlanta
Atlanta, Georgia

April 11 and 12, 1975

VOL. LXIII

PUBLISHED BY THE SOCIETY
ST. LOUIS
1975

CONTENTS

PAGE

Annual Photograph 5

Officers of The American Otological Society, Inc. 7

Registration of the One Hundred Eighth Annual Meeting:
- Members 9
- Invited Speakers 10
- Guests 10

Remarks by the President: Lester A. Brown, M.D. 13

Introduction of the Guest of Honor, John E. Bordley, M.D. 14

Remarks by the Guest of Honor 15

SCIENTIFIC SESSION

The Cochlear Implant: Current Status. William F. House, M.D. (Abstract) 17

Present Status and Future Development of the Cochlear Prosthesis.
Robin P. Michelson, M.D., Robert A. Schindler, M.D., Michael M. Merzenich, Ph.D., David N. Schindler, M.D. 18

Cochlear Potentials and Oxygen Associated with Hypoxia. Merle Lawrence, Ph.D., Alfred L. Nuttall, Ph.D., Paul A. Burgio, A.B. 23

Conservative Management of Ménière's Disease: Furstenberg Regimen Revisited.
Roger Boles, M.D., Dale H. Rice, M.D., Roger Hybels, M.D., Walter P. Work, M.D. 36

Discussion:
- Lester A. Brown, M.D. 40
- Juergen Tonndorf, M.D. 40
- William F. House, M.D. (closing) 41
- Robin P. Michelson, M.D. (closing) 41

Grafting Materials and Methods in Reconstructive Ear Surgery. Rodney Perkins, M.D. 42

Otology and Industrial Hearing Conservation. Joseph Sataloff, M.D. 51

Complications in Acoustic Neuroma Surgery. Michael E. Glasscock III, M.D., James W. Hayes, M.D., James P. Murphy, M.D. 54

Electronystagmography: A Review of 17 Years Experience. Wallace Rubin, M.D. 64

Sensorineural Hearing Loss Due to Cochlear Otospongiosis: Theoretical Considerations of Etiology. Fred H. Linthicum, Jr., M.D., Roberto Filipo, M.D., Sidney Brody, P.E. 67

Reconstruction of the Open Mastoidectomy Ear: A Six Year Progress Report. Mansfield F. W. Smith, M.D. 75

Experimental Aural Cholesteatoma Causing Bone Resorption. Maxwell Abramson, M.D., Richard G. Asarch, M.D., Ward B. Litton, M.D. 80

Discussion:

Juergen Tonndorf, M.D. 87

Shirley Baron, M.D. 87

Idiopathic Facial Paralysis, Pregnancy, and the Menstrual Cycle. Raymond L. Hilsinger, Jr., M.D., Kedar K. Adour, M.D., H. E. Doty 88

Discussion:

Robert J. Ruben, M.D. 97

Jack W. Pou, M.D. 97

Innervation of the Cochlea of the Guinea Pig by Use of the Golgi Stain. Catherine A. Smith, Ph.D. 98

Discussion:

Juergen Tonndorf, M.D. 113

Lester A. Brown, M.D. 113

Moses H. Lurie, M.D. 113

Catherine A. Smith, Ph.D. (closing) 113

Temporal Bone Histopathological Findings in Trisomy 13 Syndrome. Isamu Sando, M.D., Alberto Leiberman, M.D., LaVonne Bergstrom, M.D., Soji Izumi, M.D., Raymond P. Wood II, M.D. (Abstract) 114

Discussion:

Robert J. Ruben, M.D. 115

Harold F. Schuknecht, M.D. 115

John E. Bordley, M.D. 115

Richard Marcus, M.D. 115

Robin P. Michelson, M.D. 115

LaVonne B. Bergstrom, M.D. (closing) 115

Genetic Sensorineural Deafness in Adults. Michael M. Paparella, M.D., David G. Hanson, M.D., K. N. Rao, M.D., Rolf Ulvestad, M.D. 116

Discussion:

Eugene L. Derlacki, M.D. 129

Jack L. Pulec, M.D. 129

Michael M. Paparella, M.D. (closing) 129

Paget's Disease of the Temporal Bone. George T. Nager, M.D. (Abstract) 130

Operative Treatment of Surgical Lesions with Objective Tinnitus. Paul H. Ward, M.D., Richard Babin, M.D., Thomas C. Calcaterra, M.D., H. R. Konrad, M.D. 132

Eustachian Tube Lymphatics. Jack L. Pulec, M.D., Tomokazu Kamio, M.D., Malcolm D. Graham, M.D. 141

Introduction of the Award of Merit Recipient, Catherine A. Smith, Ph.D. 151

Response of the Award of Merit Recipient 152

Award of Merit Recipients 153

Guests of Honor 154

Business Meeting, April 11, 1975

Election and Presentation of New Members 155

Election of Nominating Committee 156

Business Meeting, April 12, 1975

Approval of Minutes of Meeting, April 21-22, 1975 158

Reports:

Secretary-Treasurer 158

Editor-Librarian 162

Board of Trustees of the Research Fund 163

American National Standards Institute, Inc. 163

American Board of Otolaryngology 164

American College of Surgeons 165

Nominating Committee 165

Business:
Old:
Election of Council 165
Communications 165
New:
Honorary Membership 165
Future Meetings, Time and Place 166
Introduction of President-Elect, Victor Goodhill, M.D. 167
Presentation to President Lester A. Brown, M.D. 167
Response of President-Elect 167

In Memoriam
Barry J. Anson, M.D. (associate) 169
Walter Page Covell, M.D. (associate) 171
Francis L. Weille, M.D. (active) 173
Henry Lane Williams, M.D. (active) 175

Members
Active 176
Senior 179
Emeritus 180
Associate 180
Honorary 180

Index
Authors 182
Subject 183

MEMBERS IN ATTENDANCE AT THE ONE HUNDRED AND EIGHTH ANNUAL MEETING

Row 1: McCabe, Proctor, Snow, Naunton, D. K. Lewis, Kos, Derlacki, M. Lewis.

Row 2: Maddox, Montgomery, W. House, Baron, H. House, Senturia, Bradley, Taylor, Brown, Bordley, Shambaugh, Rosenwasser, Lurie, Lathrop, Goodhill, Michelson, Cole.

Row 3: Hough, Lim, Pulec, Shea, Armstrong, Hilger, Rubin, Basek, Woodman, Ritter, Farrior, McLaurin, Torok, Silcox, McQuiston, Wehrs, Robinson, Goldman, Simmons, Singleton.

Row 4: Sataloff, Daly, Ruben, Buckingham, A. Hilding, Simonton, Wilson, Bailey, Tabb, Ruggles, Sheehy, Anthony, Cody, Withers, Bellucci, Chandler, Moon, C. Smith, DeWeese, Gacek, Compere, Morrow, Barber.

Row 5: Alford, McGovern, Goodman, D. Hilding, Duvall, M. Ronis, Sando, Schuknecht, Dayal, McNally, Boyd, Catlin, Hardy, Druss, Rambo, Nager, Moore, Lawrence, Harrill, Ward, Vernon, Crabtree, Tonndorf, M. Smith.

Row 6: Stroud, Harrison, Glasscock, McAskile, Fitz-Hugh, Davison, Powers, Work, Caparosa, Proud, Schlosser.

OFFICERS

1975

PRESIDENT

LESTER A. BROWN, M.D.
490 Peachtree Street, N.E.
Atlanta, Georgia

VICE-PRESIDENT

VICTOR GOODHILL, M.D.
459 North Roxbury Drive
Beverly Hills, California

SECRETARY-TREASURER

G. DEKLE TAYLOR, M.D.
Marshall Taylor Doctors Building
Jacksonville, Florida

EDITOR-LIBRARIAN

BRIAN F. MCCABE, M.D.
University Hospitals
Iowa City, Iowa

COUNCIL

The above Officers, and
BEN H. SENTURIA, M.D.
WESLEY H. BRADLEY, M.D.
SHIRLEY H. BARON, M.D.
CARY N. MOON, JR., M.D.

AMERICAN OTOLOGICAL SOCIETY, INC.

REGISTRATION

Members and Guests attending the One Hundred and Eighth Annual Meeting of the American Otological Society, Inc., which was held at the Hyatt Regency Atlanta, Atlanta, Georgia, April 11 and 12, 1975.

MEMBERS

Active Members

BOBBY R. ALFORD
WALTER P. ANTHONY
BEVERLY W. ARMSTRONG
HOWARD A. T. BAILEY
HUGH O. BARBER
SHIRLEY H. BARON
MILOS BASEK
RICHARD BELLUCCI
LESLIE BERNSTEIN
JOHN E. BORDLEY
HAROLD M. E. BOYD
WESLEY H. BRADLEY
LESTER BROWN
R. A. BUCKINGHAM
RALPH J. CAPAROSA
FRANCIS I. CATLIN
J. R. CHANDLER
CLAUDE C. CODY
JAMES M. COLE
WESLEY E. COMPERE
JAMES A. CRABTREE
JOHN F. DALY
FRANCIS W. DAVISON
VIJAY S. DAYAL
EUGENE L. DERLACKI
DAVID D. DEWEESE
A. J. DUVALL
J. BROWN FARRIOR
RICHARD R. GACEK
MICHAEL E. GLASSCOCK III
JOSEPH L. GOLDMAN
VICTOR GOODHILL
WILFRED S. GOODMAN
WILLIAM G. HARDY
JAMES A. HARRILL
WILEY H. HARRISON
A. C. HILDING
DAVID A. HILDING
JEROME HILGER
JACK V. HOUGH
WILLIAM F. HOUSE
MICHAEL C. KOS
DONALD K. LEWIS
FRANK D. LATHROP
MILES L. LEWIS
FRED H. LINTHICUM, JR.
WARD B. LITTON
MOSES H. LURIE
H. EDWARD MADDOX
KENNETH McASKILLE
BRIAN F. McCABE
FRANCIS H. McGOVERN
JAMES W. McLAURIN
RALPH J. McQUISTON
RICHARD E. MARCUS
ROBIN MICHELSON
WILLIAM W. MONTGOMERY
CARY N. MOON
JAMES A. MOORE
RUFUS C. MORROW
GEORGE T. NAGER
RALPH F. NAUNTON
MICHAEL M. PAPARELLA
CLAUDE LEE PENNINGTON
W. HUGH POWERS
BRUCE PROCTOR
G. O. PROUD
JACK L. PULEC
TOM RAMBO
FRANK N. RITTER
MENDELL ROBINSON
MAX L. RONIS
HARRY ROSENWASSER
ROBERT J. RUBEN
WALLACE RUBIN
RICHARD L. RUGGLES

Active Members (continued)

J. SATALOFF
WOODROW D. SCHLOSSER
HAROLD F. SCHUKNECHT
GEORGE E. SHAMBAUGH, JR.
JOHN J. SHEA
JAMES L. SHEEHY
LOUIS E. SILCOX
BEN H. SENTURIA
HERBERT SILVERSTEIN
F. BLAIR SIMMONS
KINSEY M. SIMONTON
GEORGE T. SINGLETON
MANSFIELD F. W. SMITH
JAMES B. SNOW
MALCOLM H. STROUD
HAROLD G. TABB
GEORGE DEKLE TAYLOR
JUERGEN TONNDORF
NICHOLAS TOROK
PAUL H. WARD
ROGER E. WEHRS
BEN T. WITHERS
WILLIAM H. WILSON
WALTER P. WORK

Senior Members

JOSEPH G. DRUSS
G. SLAUGHTER FITZ-HUGH
HOWARD P. HOUSE
WM. J. McNALLY
DEGRAAF WOODMAN

Associate Members

MERLE LAWRENCE
DAVID J. LIM
ISAMU SANDO
CATHERINE A. SMITH

Speakers (Guest)

ROGER BOLES
RODNEY PERKINS
MAXWELL ABRAMSON
KEDAR K. ADOUR
LAVONNE B. BERGSTROM

GUESTS

MAXWELL ABRAMSON
KEDAR K. ADOUR
DANIEL P. AKIN
DONALD G. ALBERS
JOANNE M. ALEXY
NANCY R. ALLEN
HOOSHANG ALMASSIAN
CHARLES H. ALPER
SEAN R. ALTHAUS
NAVIN P. AMIN
EDWARD L. APPLEBAUM
GRADY ARNOLD
AZHAR ASLAM
JOSEPH P. ATKINS, JR.
ELHAMY L. ATTIA
DAVID F. AUSTIN
RICHARD W. BABIN
BYRON J. BAILEY
DAVID G. BAILEY
BERNARD M. BARRETT
GERALD N. BART
LAVONNE B. BERGSTROM
ROBERT A. BERTRAND
JOHN BIZAL
DONALD S. BLATNIK
LEONARD C. BLEIDT
BARBARA A. BOHNE
ROGER BOLES
DERALD E. BRACKMANN
EDWARD C. BRANDOW
PATRICK E. BROOKHOUSER
KENNETH H. BROOKLER
JAMES S. BROWN
THOMAS D. BROWN
LYNN McCUISTON BURNETT
SIDNEY N. BUSIS
ANDRES B. BUSTANANTE
ROBERT A. BUTLER
JOHN G. CAMPBELL
EDUARDO M. CANILANG

GUESTS (continued)

WADE R. CARTWRIGHT
NICHOLAS J. CASSIS
ROBERT J. CATER
EDGAR CHIOSSONE
WILLIAM A. COMBS
JAMES P. CONLEY
STANLEY W. COULTHARD
BEN P. COUNCIL
HENDRIK J. DEJAGER
ANTONIO DE LA CRUZ
GEORGE T. DEMOS
CORNELIUS F. DERRICK
LARRY C. DOBBS
ROBERT A. DOBIE
DONALD T. EAGLES
WILLIAM G. EDWARDS
DAVID N. F. FAIRBANKS
JAMES R. FANCHER
JOSEPH C. FARMER
JAY B. FARRIOR
BLAIR FEARON
CHARLES F. FERGUSON
NELSON FERNÁNDEZ-BLASINI
FULTON W. FITE
JAS. T. FLYNN, JR.
PERRY A. FOOTE, JR.
JOSEPH FREEMAN
ERIC W. FRIEDRICH
KISHIN Y. GANDHI
TIERRY F. GARCIA
P. GERLINGS
NATHAN I. GERSHON
IRWIN A. GINSBERG
JOHN H. GLADNEY
ROSALIND S. GORDON
VICTOR GOTAY
HARRIETT M. GOURLEY
THOS. E. GRIFFITH
ROBERT T. GUELCHER
RICHARD W. HANCKEL
DAVID G. HANSON
HERBERT H. HARRIS
GEORGE I. HARRISON
CECIL W. HART
T. WILLIAM HAYES
E. L. HENDERSHOT
RAYMOND L. HILSINGER
RAYMOND L. HILSINGER, JR.
MILTON R. HIMALSTEIN
ELIAS Y. HIZAL
STEPHEN P. HOGG
LAUREN D. HOLINGER
MELTON J. HORWITZ
JOHN S. HUFF
ROGER L. HYBELS
CHARLES E. JORDAN
JOHN K. JONES
S. K. JUHN
EDWARD T. JULER
DONALD B. KAMERER
Y. P. KAPUR
MARC S. KARLAN
WILLIAM H. KAYE
ROBERT J. KEIM
A. P. KELLER, JR.
JAMES H. KELLY
JAY F. KENT
JAMES T. KING
SAM E. KINNEY
ERNEST F. KISH
GEORGE G. KITCHENS
BRUCE H. KLENOFF
DANIEL W. KLETZING
ROBERT I. KOHUT
ARTINE KOKSHANIAN
ROBERT M. KOMORN
RICHARD LAFLEUR
SAM J. LAMONTE
MARY D. LEKAS
JOHN S. LEWIS
WILLIAM J. LEWIS
EMSEBIO G. LIM
WILLIAM J. LOEB
J. ROBERT LOGAN
HOWARD W. LOWERY
LOUIS D. LOWRY
ALASTAIR A. MACGIBBON
JOHN W. MAHAN
LUCIE C. MAJOROS
MARTON MAJOROS
KAZUMI MAKISHIMA
GHULAM H. MALIK
DANIEL M. MARTINEZ
ROBERT H. MATHOG
MALCOLM D. MCAULEY
C. MCGIVE
THOMAS DOUGLAS MCKEE
ROBERT D. MCQUISTON
ROBERT K. MIDDLEKAUFF
DIRAN O. MIKAELIAN
DANIEL R. MILLER
LISA C. MILLER
MAXINE C. MILLER
WILLARD B. MORAN
WILLIAM C. MORGAN
RICARDO MULERO
JAMES P. MURPHY
DUANE W. NAGLE

Guests (continued)

STEVEN E. NATHANSON
PATRICK J. NOONAN
RUSSELL J. ORD
LUP Q. PANG
WILLIAM R. PANJE
JAMES L. PARKIN
SIMON C. PARISIER
ROBERT F. PARK
C. K. PARKER
WILEY A. PARKON
RICHARD C. PARSONS
RODNEY PERKINS
JOHN H. PER-LEE
WALTER A. PETRYSHYN
JOSE T. PICO
RONALD J. PIMPINELLA
IRA A. POLISAR
JACK W. POU
DAVID L. POUSHTER
FREDRIC W. PULLEN
LORING W. PRATT
SHOKRI RADPOUR
FRANK J. RICCIO
HENRY D. ROSIN
ANTONIO RULLAN
RAIF K. SABEH
LESLIE J. SABO
NILS SANDBERG
JUAN J. SANTIAGO
FELICE JOSEPH SANTORE
ANNE Z. SAUNDERS
GORDON F. SCHAYE
GARY C. SCHECHTER
STUART A. SCHERR
GERALD L. SCHMITZ
JOHN K. SCOTT
ABRAHAM SHULMAN
HARVEY H. SIROTA
E. JOHN SMITH
THOMAS TIMOTHY SMITH
JOHN H. SOBEL
NATHANIEL L. SPARROW
JAMES T. SPENCER
JAMES H. SPILLANE
EDWARD J. STARINCHAK
EDWARD W. STEVENSON
H. BENJAMIN STONE
MICHAEL SULMAN
DONALD R. TODD
HARVEY M. TUCKER
JEROME J. VERANTH
ENRIQUE A. VICENS
RICHARD L. VOORHEES
PHILLIP S. WADE
FRANCELLA E. WATKINS
ALFRED D. WEISS
STEPHEN J. WETMORE
JAMES F. WHITE
JAMES W. WHITE
HAROLD WILF
WILLIAM H. WILLIS
PAUL I. WILLS
CHARLES J. WINE
PATRICIA J. WINELAND
CARL W. WULFESTIEG
EIJI YANAGISAWA
PEDRO J. YENDRELL
HARRY ZOLLER

SCIENTIFIC SESSION

FRIDAY, APRIL 11, 1975

The Scientific Program of the One Hundred and Eighth Annual Meeting of the American Otological Society, Inc., convened at 9:04 A.M. in the Phoenix Ballroom of The Hyatt Regency Atlanta, Atlanta, Georgia, Dr. Lester A. Brown, President of the Society, presiding.

REMARKS BY THE PRESIDENT

LESTER A. BROWN, M.D., PRESIDENT

UBI NOS SUMUS?

Ladies and Gentlemen: It is my pleasure to welcome you to the One Hundred and Eighth Annual Meeting of the American Otological Society and to the City of Atlanta. Offhand, it seems strange that in all these years, this is the first time that "the Otological" and the other national otolaryngologic societies which make up the "Spring Logical" meeting have ever met in Atlanta, Georgia, probably because until within the last ten years Atlanta has not had the facilities for meetings of even the small size of our combined groups.

This hotel's construction started about 1966, and the formal opening was in June 1967, amid unfinished floors, walls, and meeting and dining rooms, and the large electricity carrying cables which were lying on top of the basic floors added tedium to an exploration of the strange new hostel with its skylighted lobby and silent outside-inside elevators. In early 1968, soon after the formal opening and about the same time that a local otolaryngologic foundation put on the Atlanta Hyatt's first medical meeting, an invitation was sent to the secretary of the Triological, Victor Alfaro, to consider Atlanta as a place for the spring conclave. After one or more secretaries' meetings, the invitation was accepted for the "next open time" which to the members of the foundation seemed like a distant journey into the future (1975), seven years and two secretaries hence. The invitation's crystal ball even suggested the second week in April, which sounds as if it were cahooting with the weather bureau.

But, the reasons why the national societies have not met here before never bugged me as much as why was Atlanta ever settled at this particular spot, and even more puzzling – from whence came the name "Atlanta."

The answer to why a settlement began at the location of the now "Underground Atlanta" is that a state-owned railroad from Augusta, Georgia to the west came here to make contact with one railroad that was coming from about half-way down what is now the Georgia-Alabama line and another railroad that was already in operation from Cincinnati to Nashville which wanted in on the junction. Basically, it was just that simple in those 1830s, which was only about 35 years before the formation of the American Otological Society.

It does not take too much imagination to understand how it happened that the new location in the pine tree thicket – no, not peach trees – became known as Terminus. Ten years later, more or less, the name was changed to Marthasville in honor of Governor Lumpkin's daughter, which name only lasted about four years, being replaced by the permanent name of "Atlanta," the derivation of which has never been explained – even 140 years later.

And so, I shall conclude these opening remarks in order to conform with the ruling of the Council of the Otological whose instructions about time-saving were written, sent to each essayist and now displayed in slide one. Since you cannot read this, I can tell you from slide two that the instructions are:

BE BRIEF

NO THANKS

NO HISTORY

MEAT

SELECTED SLIDES

I hope that you have enjoyed or will enjoy your visit to this city, that you will come back and maybe you will, since the Academy has been eyeing Atlanta as one of the prospective places for its meetings. Already, on the drawing boards are plans for adequate accommodations within one-half mile of where we are right now. I do not know that the new structure will have hotel accommodations; but even if it does, you could again stay at the Hyatt Regency Atlanta, the Hyatt system's flagship, if you so desired.

And finally, just in case there might be someone who has had a lapse of Latin memory, the subject of these remarks, UBI NOS SUMUS?, means "Where are we?"

Well, we are about five blocks north of where the first two railroads met.

INTRODUCTION OF THE GUEST OF HONOR: JOHN E. BORDLEY, M.D.

LESTER A. BROWN, M.D.

Ladies and gentlemen, as the fifth generation of physicians in his family, our Guest of Honor today was born in Baltimore, went to the Gilman School in Baltimore for his early preparatory work and then to Yale for his college degree.

You know, Yale is a right nice little School. It is about 175 miles south of Harvard!

He received his Doctor of Medicine degree from Johns Hopkins School of Medicine, and completed his residency in otolaryngology at Johns Hopkins Hospital. From 1942 to 1945 he served with the World War II Hopkins Unit in the Southwest Pacific.

Upon returning he practiced otolaryngology in Baltimore until 1952, at which time he accepted the offered professorship in otolaryngology at Johns Hopkins School of Medicine and became the first full-time Andelot Professor in Otolaryngology.

His hobbies are golf and photography, and he says that he so much likes to travel that he includes travel in his hobbies.

He has been visiting professor in many places in the world, some of which are Mexico, Thailand, Taiwan, the Philippines, London and Cairo, to name some places.

I have known Dr. Bordley for many years, but about four years ago, one Sunday morning just before the American Board of Otolaryngology opened its annual meeting, I was in the street arcade of the Palmer House on my way to breakfast when I met John by accident. We walked a short distance north on State Street, then some two blocks west on Madison to Maxime's restaurant. I was amazed at two things; that Dr. Bordley had a sense of humor, and he never forgets anything that he hears or sees.

I can tell you that was one of my most enjoyable breakfasts, listening to Dr. Bordley tell about worldwide travel experiences, not necessarily medical, and eating strawberry pancakes!

It gives me a great deal of pleasure to introduce to you our Guest of Honor for 1975, Dr. John E. Bordley.

REMARKS BY THE GUEST OF HONOR

JOHN E. BORDLEY, M.D.

Thank you, Lester. This is indeed a great honor for me. This Society was the first Society I ever attended as a house officer, actually, in Atlantic City. Unfortunately, I can only say "thank you" to this Society and to our President. I cannot describe how I feel in my heart. It is a mixture of deep appreciation, affection and humility.

I think when one receives an honor like this from one's colleagues, it is just about the nicest kind of honor that you can receive and it is an honor that always lives with you.

As a Guest of Honor, I was told that the Guest of Honor had the privilege to speak on any subject of his choice, or not to speak at all!

The instructions also advised that if the Guest of Honor did choose to speak that he should keep it short.

After much consideration, I have decided to speak a few words on a subject that is of deep concern to me. The subject has to do with the future activities of our Society.

It could be called leadership.

The distinguished tradition of our Society has been to act as the forum before which the scientific research and technical advances in otology are annually presented, debated and tested for excellence.

Through the years its programs have been unmatched. For instance, it has been my privilege to hear the first public presentations of such fascinating subjects as recruitment, basal turn atrophy of the organ of Corti in sensorineural hearing loss, cochlear potentials, fenestra novovalis, glomus jugulare, vestibular nerve section for Ménière's disease, stapes mobilization, stapedectomy and the transtemporal approach for VIII nerve tumors.

These are but a few of the presentations that this Society has staged in the past thirty years.

Through the years, it has steadily grown in stature. Its importance as a national and international force is recognized by all otologists everywhere today. Its leadership role has been taken for granted.

Today, we are facing a need for a new kind of leadership. This leadership should be supplied by our Society.

This country is about to implement a number of laws that originated as a result of research work encouraged by this Society, presented before this Society and performed for the most part by members of this Society.

I am referring to OSHA, the Occupational Safety and Health Act of 1970.

This act is designed to protect this country's working population from hearing damage secondary to environmental noise or toxic agents. OSHA will cost the citizens of this country approximately $13 billion to implement.

It is the largest, most costly and most important plan for hearing conservation in the world's history. Just one item gives some idea of its immensity. It has been calculated that it will require at least ten thousand additional trained audiometrists to implement the program.

At present, this program does not include any medical or otological supervision in its plans. However, there are negotiations underway that in all likelihood will result in making the otologist basically responsible for the supervision of many of its programs that are being organized today throughout industry.

The preservation of hearing of millions of individuals will depend on the excellence of these programs. It is therefore of the greatest importance that the proper procedures and standards be developed and maintained.

Members of this Society have taken part in some of the planning discussions and they should have a great deal to say about such procedures and standards.

Leadership in the critical review of plans and standards and strong support for those otologists devoting their time to the development of the programs is very much needed.

This is not politics, for politics is not the responsibility of our organization, rather it is our responsibility as the most powerful force in the field of hearing today to make sure that no efforts be spared to see that the best standards are adopted and the strongest otological supervision is maintained over such programs and standards.

Times are changing. Needs are changing.

Our country is finally taking advantage of the output of our laboratories and putting it into practice for the benefit of its people.

A new idea has been born. Now it is of great importance that this Society, with all its expertise in hearing, help it to develop into something fine.

Hearing loss one might say has gone national, just as cancer and heart disease have done.

Today, we face a whole new challenge.

Let us marshal those forces that we have created in the Committee on Hearing and Equilibrium of the Academy, the Hearing Committee of the American Council and in this great Society, and assert the otologist's right to take the lead in things otological.

Is this Society prepared to meet this new challenge for leadership? I hope it is.

THE COCHLEAR IMPLANT: CURRENT STATUS

ABSTRACT*

WILLIAM F. HOUSE, M.D.

LOS ANGELES, CALIFORNIA

This is the first report in a series of long-term studies on cochlear implants from the vantage point of various specialists. Fifteen patients have been implanted and specifics of each case are presented in case histories.

The surgical technique is described and the engineering involved in the development of an electronic prosthesis is detailed. Engineering studies indicate that it is probably feasible to dedevelop a multiple electrode system which can supersede the present single wire appliance. Since there has been considerable controversy about the long-term toxic effects of implanted wires, findings are presented which challenge such pessimism. In one instance, studies under electron microscopy indicate that there is no change either in the insulation material or the electrode wire. Further support comes from another study which indicates that over time there is no evidence of electrolysis.

Thirteen patients were given intensive rehabilitation and the results were encouraging because speechreadng improved, a wide variety of environmental sounds were understood, and the quality of life seemed improved. Psychological studies, which primarily are concerned with describing the problems and methods involved in studying patients with implants, nevertheless have accumulated sufficient data to support the previous view that cochlear implants make a significant difference to the recipient's life.

To date, the evidence supports the view that cochlear implants are an important contribution in restoring sound and in improving the quality of life in selected individuals who have sustained a profound hearing loss.

---

* The complete manuscript will be published as a supplement and will accompany a future issue of the *Annals of Otology, Rhinology and Laryngology.*

PRESENT STATUS AND FUTURE DEVELOPMENT OF THE COCHLEAR PROSTHESIS

ROBIN P. MICHELSON, M.D.

MICHAEL M. MERZENICH, PH.D. ROBERT A. SCHINDLER, M.D.

DAVID N. SCHINDLER, M.D.

SAN FRANCISCO, CALIFORNIA

SUMMARY – Presently devised single channel devices generate relatively primitive sensation of hearing. They provide some enhancement of communication skills for the totally deaf. Definite psychological advantages for the totally deaf have been observed. Pitch discrimination is by the mechanism of "periodicity pitch." No "place" pitch encoding is possible. The recognition of complex sounds is not possible. Multiple segments of auditory nerve must be stimulated in a manner which will simulate the complex patterns of neural activity necessary for speech discrimination. Electrodes can be optimized and the pathophysiological consequences of electrical stimulation can be determined in experimental animals. The perceptual consequences of electrical stimulation, however, can best be determined in man himself. How much we will have to rely on known and future methods of aural rehabilitation will depend upon how well perceptual speech patterns can be generated by electrical stimulation of the auditory nerve.

Speech discrimination by ear alone has not been possible with the aid of any cochlear prosthetic device so far devised. The limited sensation of hearing afforded with these devices has, however, been of definite benefit in totally deaf patients. Enhancement of communication skills with lip reading, as well as the awareness of environmental sounds, has resulted. In this manner, the distressing isolation of total deafness has been at least partially overcome.

The synchronous stimulation of a single large segment of auditory nerve, afforded by these single channel devices, produces limited auditory sensation by the mechanism of "periodicity pitch." No "place pitch" encoding is possible with a single channel device. Pitch discrimination is limited to the range of 60-600 Hz although tonal sensation is present when stimulus frequencies are as high as 10 kHz. Thus, it has not been possible to generate neural firing patterns with sufficient information content (and complexity) for the recognition of speech or complex sounds.

The Present Status of Cochlear Prostheses. The question of auditory nerve survival after cochlear implantation has been a major interest to our group. Histopathological studies in animals by Schindler and Merzenich,[1] as well as physiological studies by Merzenich, *et al*, have shown that auditory nerve survives scala tympani implantation almost intact, even though massive hair cell destruction occurs. These studies extend to three and one-half years in animals (Fig. 1). Injury of the basal membrane or fracture of the modiolus produces severe localized degeneration. Implantation of small electrode arrays into the spiral ganglion also results in some localized neural degeneration.[3] Experience with patients correlates well with these observations since no impair-

From the Coleman Memorial Laboratory, Department of Otolaryngology, University of California at San Francisco, San Francisco, California.

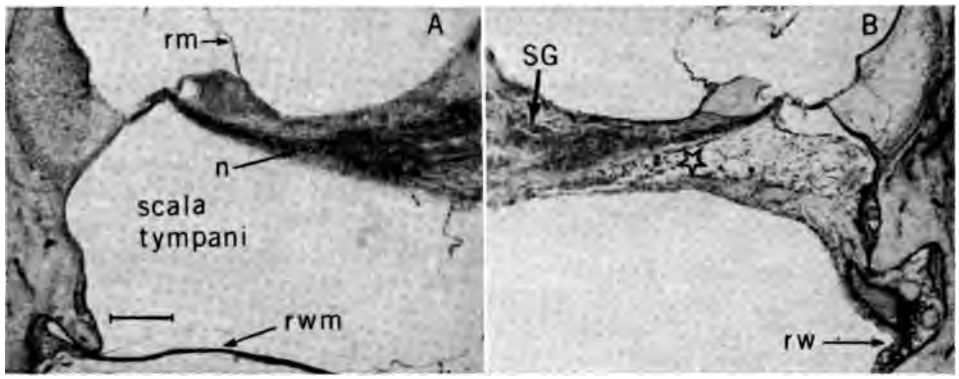

Fig. 1. Midmodiolar section through the basal turn near the round window in a normal cat (A) and an implanted cat (B). rm – Reissner's membrane; n – Radial fibers of the spiral ganglion cells; rwm – Round window membrane; rw – Round window area; SG – Spiral ganglion; star – Connective tissue reaction to the electrode. Note differences in the appearance of the stria vascularis in the normal and implanted cats. The bar at the lower left is 200μ in length.

ment of performance has been noted during a five-year observation period.

Threshold responses of single colliculus units to electrical sine wave stimulation of the auditory nerve in animals correlated well with patient thresholds (Fig. 2).

The sensation of loudness increased in ordered relation to stimulus strength. The upper limit of loudness was taken as a "too loud" response from the patient. No painful or vertiginous sensation ever resulted indicating that the stimulus was limited to the cochlea and was not spreading to the labyrinth or middle ear. The dynamic range of loudness sensation generated by electrical stimulation of the auditory nerve determined in this manner was only 15 dB.

Studies by Merzenich, *et al*[2] have shown phase locked neural responses to electrical sine wave stimulation of the auditory nerve. This "phase locking" breaks up when stimulus frequencies are above 600-700 Hz. This observation correlates well with pitch scaling experiments on implanted patients who show poor pitch discrimination above 700 Hz. Tonal sensation is still present, however, to at least 10 kHz. Paradoxically, these patients are able to detect a tonal quality difference between sine

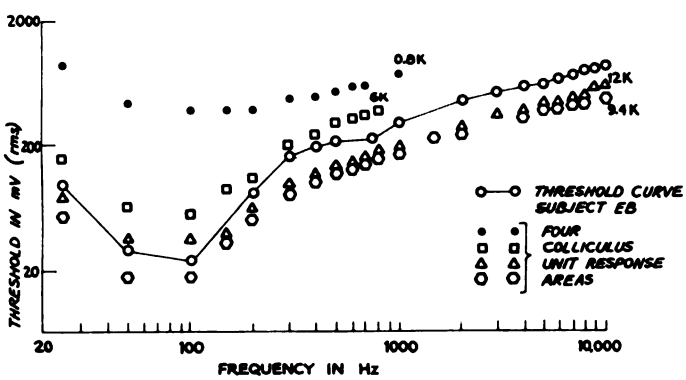

Fig. 2. Threshold responses to electrical stimulation of the acoustic nerve in man (open circles). Response of four colliculus neurons in animals driven by electrical stimulation are also shown.

and square wave electrical stimulation even at high frequencies.

Physiological studies by Merzenich, *et al*[2] also revealed that neural responses to electrical sine wave stimulation occurs over a broad frequency range in contrast to the narrow frequency range to sound stimulation.

Our early prosthetic devices were only capable of synchronously stimulating a broad segment of auditory nerve. The stimulus form was the electrical analog of the acoustic input modified in two ways. First, the frequency response of the system was modified so that patient response thresholds were flat. Second, an automatic gain control was incorporated, which effectively increased patient dynamic range to approximately 50 dB. When these modifications were made, subjects were able to distinguish voices, which had a more "natural" quality. In fact, they were often able to distinguish one voice from another. Unaided speech discrimination, however, was not possible.

A radio frequency carrier was first used to transmit information and power across the intact skin to the internal device. Electromagnetic interference with this system did not present a problem. Failure of some of the internal electronic components, however, was a problem. The broad frequency response range (100 Hz-20 kHz) was a distinct advantage. Later simple electromagnetic coupling proved to be the most reliable, although frequency response was limited to 300 Hz-4 kHz.

Patient acceptance of these devices, in our small series, has been surprisingly good in spite of the mechanical failures necessitating replacement of the implant.

Future Devices and Research Objectives. It is now apparent that if recognizable speech patterns are to be generated with electrical stimulation of the acoustic nerve, multichannel differential stimulation almost certainly will be required. Thus, a means of "place" as well as "periodicity" encoding must be provided. Work in our laboratory, principally by Merzenich, *et al*[4], has shown that it is feasible to electrically excite small segments of auditory nerve through the scala tympani. Attenuation between electrically excited segments of basal membrane is approximately 25 dB per octave, presumptive evidence that good isolation can be obtained between channels in a multichannel scala tympani electrode array (Fig. 3). These observations were made with an electrode of .003 inch in diameter. It is conceivable that even better isolation

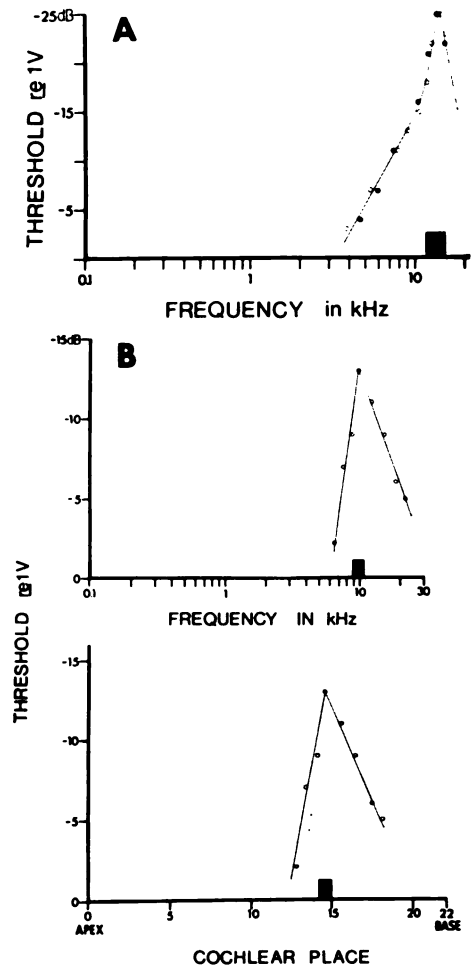

Fig. 3. Colliculus neuron response curves to electrical stimulation of a single segment of basal membrane (electrode contact diameter .003 inch).

can be obtained with different electrode configurations.

Using bipolar electrodes preliminary observations indicate that performance is degraded if the distance between bipolar elements is less than 200 μ. Exact contact with basal membrane is also critical. Placement against bony modiolus is ineffective. With properly placed electrodes, performance improves with time up to about six weeks, as evidenced by a decrease in threshold stimulus. Histologic studies indicate that the formation of connective tissues around the implant isolates electrode contacts from the surrounding conductive cochlear fluids.

The total number of channels (electrodes) that are feasible will probably be determined by the size of the electrical field that is needed to produce the desired graded neural response in any given segment of basal membrane.

The length of basal membrane that needs to be differentially electrically excited, theoretically, for speech discrimination is 20 mm at the basal end of approximately one and one-quarter turns of the basal coil.

Our group has developed an eight channel array with the mechanical characteristics which allow the device to be inserted safely through the round window for a distance of 23 mm in the human scala tympani. In addition, new molding techniques have provided a more accurate fit to the contours of the scala tympani.

The University of California group at San Francisco have cooperated with the Stanford team led by Simmons.[5] Simmons reports, "The Stanford group (White, Glattke, Simmons) is developing a four-channel stimulating system for placement directly in the auditory nerve. This system will eventually be tried in a small group of human volunteers but only after extensive testing in animals. There are many unique features of this system which are not now available elsewhere, and the most important of these is that the implanted electronics include a computer switch register that is externally programmable by digital instructions to each electrode separately. This will allow considerable flexibility in the translation of sounds into electrical impulses. If the four-channel system proves successful, it will be an easy matter to add additional electrode channels in multiples of four."

"We estimate that we are perhaps 6 to 18 months away from a clinical trial. The implantable electronics have been developed and are now undergoing final preproduction trouble shooting. There is, however, no way to speed up the animal test stage, principally because testing for insulation failures is an important and frustrating bottleneck." Evaluation of both methods will be a joint effort of both groups in the near future.

Future research objectives will include a determination of the safe limits of electrical stimulation of the auditory nerve over a suitable time course, as well as any external environmental hazards to which the implanted patient might be vulnerable.

Past experience has shown that the stabilized implanted electrode is the most reliable part of the cochlear implant system. The implanted electronics appear to be the most failure prone. The NIH workshop on Cochlear Implants held in San Francisco on October 23-24, 1974, concluded that a reliable implanted connector would be desirable. This would allow the replacement of the electronics module with a greatly simplified surgical procedure.

The last but not the least important objective is to determine the most effective mode of stimulation. More exact information on the tissue electrode interface, as well as more exact details of nerve excitation under these conditions, are needed. Three broad methods of encoding information for meaningful excitation of the auditory nerve array within the cochlea seem to warrant investigation.

1. Vocoder Processing: A series of single formant frequencies are extracted

from the incoming speech signal and delivered as a stimulus to the appropriate "frequency place" on the basal membrane.

2. Programmed pulsatile stimulation: Pulses of various repetition rates and amplitude would be delivered to the appropriate "frequency place." Vocoder format could be used on speech filtered into appropriate bands and encoded into pulses.

3. Multiple filters: Speech signals would be divided into predetermined frequency bands and delivered as an analog signal to the corresponding "frequency place."

As indicated above, a versatile programmable pulse-generating device is nearing completion at Stanford. It will deliver symmetrical-graded electrical charges to the auditory nerve via the Simmons modiolar electrode or the scala tympani electrode.

Our group has under design consideration of an implantable device consisting of eight active filters. The frequency elements of the auditory input signal would be delivered as analog stimuli to appropriate locations on the basal membrane.

These devices all have inherent limitations in terms of flexibility. It would be highly desirable to control all variables from outside the subject. With this idea in mind, preliminary engineering studies indicate that a device might be constructed within the required size constraints that would have the following characteristics: 1) independent control of each channel, 2) sufficient channel band-width to allow the delivery of a wide variety of stimulus wave forms including specified pulses, and 3) backward telemetry would be provided to allow monitoring of the actual stimulus and electrode performance *in situ*.

With such a device the perceptual consequences of the various stimulus parameters could be compared in a single individual.

Request for reprints should be sent to Robin P. Michelson, M.D., Coleman Memorial Laboratory, HSE-863, University of California at San Francisco, San Francisco, Calif. 94143.

REFERENCES

1. Schindler R, Merzenich M: Chronic intracochlear electrode implantation: Cochlear pathology and acoustic nerve survival. Ann Otol Rhinol Laryngol 83:202-215, 1974

2. Merzenich M, Michelson RP, Schindler RA, *et al*: Neural encoding of sound sensation evoked by electrical stimulation of the auditory nerve. Ann Otol Rhinol Laryngol 82:486-503, 1973

3. Simmons FB: Cochlear implants. Arch Otolaryngol 89:61-69, 1969

4. Merzenich M, Schindler DN, White MW: Feasibility of multichannel scala tympani stimulation (Symposium on cochlear implants). Laryngoscope 84:1887-1893, 1974

5. Simmons FB: Personal communication

COCHLEAR POTENTIALS AND OXYGEN ASSOCIATED WITH HYPOXIA

MERLE LAWRENCE, PH.D.

ALFRED L. NUTTALL, PH.D. PAUL A. BURGIO, A.B.

ANN ARBOR, MICHIGAN

SUMMARY – In the guinea pig, during general hypoxia produced by shutoff of respiratory air, oxygen-sensitive microelectrodes detect a decrease in oxygen concentration in the fluids of the tunnel of Corti before detecting a decrease in scala media oxygen concentration. The present experiments were designed to measure the cochlear microphonic (CM) potential generated by the organ of Corti when vibrated by a microprobe on the basilar membrane along with the oxygen decline in both tunnel and scala media to see upon which source of oxygen CM is dependent. Because oxygen concentration in both areas can decrease considerably before CM is affected, the recovery following a brief period of hypoxia is a more accurate measure. Because CM starts a recovery before scala media oxygen, the positive endolymphatic potential (EP) was also measured to determine its role in the generation of CM. Our interpretation of the course of events is that CM is partially dependent upon oxygen supplied to the extracellular spaces of the organ of Corti by the spiral vessels and upon EP that, itself, is dependent upon several factors. The data indicate that EP plays a more complex role than that of providing a current flow for modulation by a resistance varying with vibration.

As techniques for the study of the capillaries of the inner ear improve it becomes more apparent that inner ear disorders and the accompanying sensorineural hearing loss are brought about by vascular pathology and changes in the microhomeostatic conditions.[1,2] Capillary involvement has been clearly demonstrated in man and animals, and the observed changes have been found to be associated with aging, toxins, and noise.

The histopathological changes observed in the capillaries have been reported as swollen endothelial cells which occlude blood flow and degenerated capillaries forming intravascular strands and avascular channels.[3] Such pathology would indicate that a deficit in inner ear function results either from the direct effect of local anoxia or from ionic or metabolic imbalance resulting from secondary changes in secretory tissues.

Many experiments have been carried out, starting in 1941,[4] demonstrating the effects of general hypoxia upon the cochlear potentials which have come to be recognized as accurate measures of inner ear function providing these potentials are interpreted correctly.

Békésy[5] showed that the cochlear microphonic (CM) and the DC resting potential of the perilymph (recorded behind the round window), while quite resistant to low-oxygen content of respiratory air, do decrease with anoxia. Later,[6] in an attempt to determine the source of CM and the magnitude of the positive resting potential of the endolymph (EP), he recorded almost par-

---

From the Kresge Hearing Research Institute, University of Michigan Medical School, Ann Arbor, Michigan.

This research was supported by funds from the John A. Hartford Foundation and PHS grants NS-05785 and NS-11731.

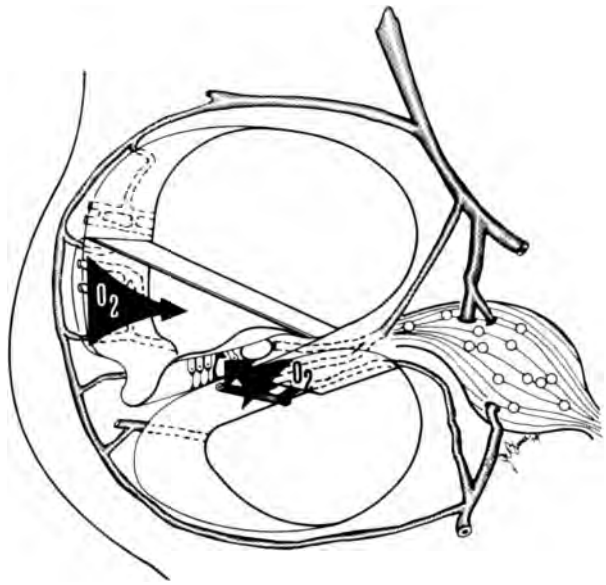

Fig. 1. Sources of oxygen for the organ of Corti with the spiral vessels the most likely.[10] Experiments reported here were designed to determine relationship between CM and O_2 in these fluid spaces.

allel decline in these potentials with anoxia.

There are many other experiments showing the effects of anoxia on cochlear potentials that cannot be reviewed here, but there are a few pertinent to the present study.

Misrahy, *et al*[7] were the first to measure oxygen within the endolymph and to determine the amount of change with anoxia. They concluded that the organ of Corti receives its oxygen from the stria vascularis. In 1961 Rice and Shinabarger[8] sought to correlate the drop in EP and CM with each other and with anoxia. They found the correlation so poor that no direct relation between CM and EP was indicated.

Similarly, other studies have determined the relation between general hypoxia and the decline of the cochlear potentials, but in order to understand the effects of the observed histopathological changes upon the organ of Corti function, it becomes important to know which of the various capillary areas is responsible for the observed decline in electrical potential.

Histopathological changes have been observed in the spiral capillaries and in the capillaries of the stria vascularis, and the evidence indicates that these two areas serve different functions.[9] During general hypoxia the oxygen tension in the tunnel fluid supplied by the spiral vessels falls before the oxygen tension in the scala media endolymph.[10]

Our specific question in the design of the present experiments was whether, with hypoxia, CM generated by the organ of Corti responds to changes in the rapidly changing tunnel oxygen or to the more delayed change in endolymph oxygen. The two sources of oxygen are illustrated in Figure 1 which shows a relatively longer path for diffusion from the stria vascularis to the hair cells than from the spiral vessels to the hair cells.

As can be seen from the results the answer is complex, but the determinations do give a better understanding of inner ear function.

METHODS AND MATERIALS

In order to measure electrical events within the confines of the scala media, especially

those affected by the microcirculation, it is essential that the capillaries remain uninjured. To accomplish this we made use of direct microscopic visualization making possible the insertion of an electrode into the tunnel without injury to the spiral capillaries and the insertion of other electrodes into the scala media through the avascular *pars pectinata* of the basilar membrane.

The surgical approach and method of observing the organ of Corti for electrode placement have been described in previous publications.[10-12] Because AC, DC, and oxygen current were to be measured, both platinum and glass-micropipette electrodes were used.

The method of recording oxygen current in both the scala media and tunnel of Corti were the same as described previously except that in certain experiments we recorded both oxygen current and CM through the same platinum electrode. In general this can be accomplished by recording oxygen current with a DC current meter (since oxygen concentration and its changes are essentially DC events and the meter circuit filters out the higher frequencies). An AC amplifier for the CM potentials was connected in parallel to the current meter.

More specifically, a glass-insulated, etched-platinum-iridium microelectrode* with less than 5 μm exposed above a less than 1 μm tip served as an oxygen-reduction cathode while the reduction current was measured by an oxygen-current meter.** This device is basically a very sensitive DC current meter ($< 10^{-10}$ AMPS) and also supplies -0.6 volt bias required for the oxygen cathode. CM potentials picked up by the platinum microelectrode were recorded across a voltage-divider network formed by the resistance of the electrode ($\sim$ 10 megohm) and a 5 megohm series resistor. A preamplifier*** was used to separate and amplify the CM.

The positive endolymphatic potential (EP) and also CM were recorded by a glass-micropipette electrode with a tip diameter of 1 μm. These potentials were amplified by an electrometer amplifier,**** the output of which was divided; one branch going to a wave analyzer that does not respond to the DC, and the other branch going directly to the chart recorder.

The chart recorder recorded four events: CM, EP, oxygen current (O_2), and an electrocardiogram (EKG) from electrodes on the chest wall of the animal. This latter was recorded so that any effect on the cardiovascular activity of the animal resulting from the surgical manipulation, anesthesia, or the hypoxia could be monitored.

A microvibrator provided a stimulus either directly to the basilar membrane, or to the head of the stapes. This vibrator consisted of a glass rod with a tip diameter of about 100 μm attached to a precision-tooled steel rod, in ball bearing ways, glued to a rubber diaphragm driven through an air-filled tube by an electromagnetic driver mounted outside the electrically-shielded soundproofed room. For these experiments it seemed to make no difference in the results where the vibrator was placed, so no distinction between placement has been made.

The guinea pigs used were products of our own colony, weighed between 350 and 400 gm, and were anesthetized with diallylbarbituric acid and urethane. Through a tracheostomy, mechanical respiration was provided with rate and air volume adjusted to maintain the animal in good physiological condition. During an experiment which lasted three to four hours, the animals were kept warm by a heating pad.

The respirator used compressed air, and to produce the hypoxia the source was turned off and the tube at the trachea clamped. This procedure is designated as "air off" in the illustrations. The tube to the trachea was unclamped and the air turned on to reestablish the normal condition indicated as "air on."

During the course of these experiments, 224 separate runs with various electrode placement in 39 guinea pigs were made.

RESULTS

The Recorded Data. During an experiment, the data were recorded on the moving chart of a graphic recorder. For tabulation and statistical treatment the instant of decline or increase of each potential following "air off" or "air on" was taken directly from the chart. For visual display of the results and to facilitate the comparison of the exact moment of decline and recovery, the responses were plotted as departures from 100% which represents the prehypoxic stabilized output from each electrode. In each of three series of experiments a separate combination of electrodes was used so that different sets of measures could be compared.

Series 1: In this series two platinum microelectrodes were used, one through the zona arcuata, with the tip in the tunnel of Corti, and another passing

---

* No. 30-10-3, Frederick Haer & Co., Ann Arbor, Mich.
** Model 1200, Transidyne General Corp., Ann Arbor, Mich.
*** Model P16, Grass Instrument Co., Quincy, Mass.
**** Model A-35, Medistor Div., Simlog Instruments, Overlake Park, Redmon, Washington.

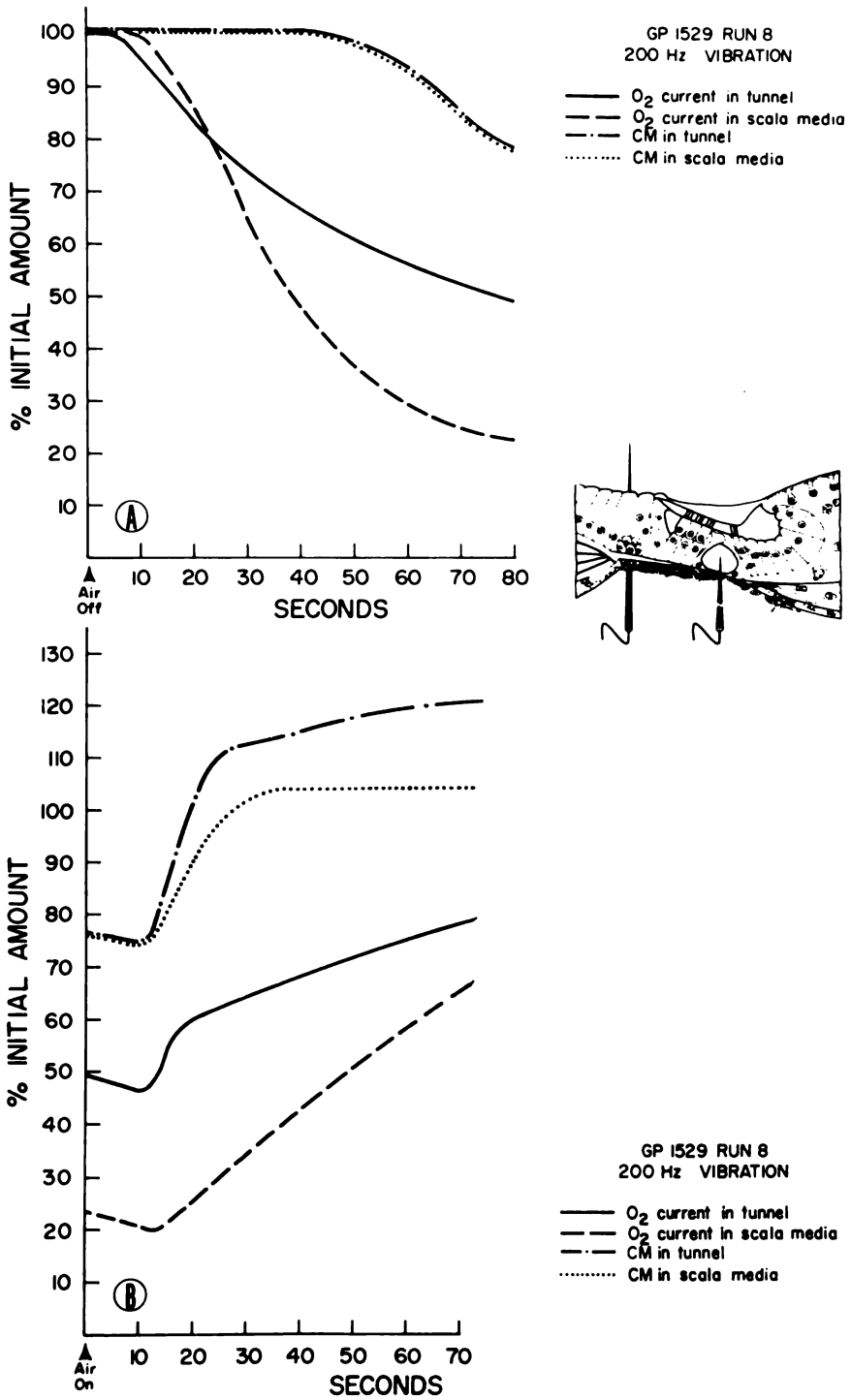

Fig. 2. Decline (A) and recovery (B) of indicated measures determined by platinum electrodes in tunnel of Corti and in endolymph of scala media.

through the zona pectinata and Claudius cells, with the tip in the scala media next to the stria vascularis. From each electrode, changes in oxygen tension and changes in CM to 200 Hz vibrations were recorded simultaneously during induced hypoxia.

Figure 2A portrays graphically the typical decline in responses following "air off." The vibrator amplitude was adjusted to give a CM level between 10 and 30 μV. Differences between initial magnitudes of response from the electrodes, placed in the different areas, were removed by means of the scaling done for graphical presentation. Initial CM magnitudes are not important for the measurement of the delays. This is also true for the oxygen-current data. For reasons stated in our earlier publication,[10] and because each of the two electrodes has a different sensitivity, the data presented are not absolute oxygen-tension measurements.

The important measure is the moment of beginning decline in each of the tracings after respiratory air to the animal is shut off. The amount of decline is immaterial except that an effort was made to return air to the animal before any general changes in the cardiovascular condition, as reflected in the EKG of the animal, were produced.

In this typical run, following shut off of respiratory air, the first recording to decline is that measuring the oxygen content of the tunnel fluid followed by that of the oxygen content of the endolymph. Several seconds later CM starts to decline simultaneously in both recording sites. It would appear that CM generation is maintained for several seconds, in this case about 37 seconds, after the oxygen in the fluid compartments starts to decrease. There apparently is an overabundance of oxygen under normal conditions which must be depleted before CM is affected. Once this storehouse disappears, the relative times of beginning recovery follow a different sequence.

Figure 2B portrays, in a typical animal, the recordings of oxygen current and CM recovery in the two fluid compartments following return of respiratory air. It appears that all recordings start recovery at the same time, but close measurement shows this is not the case. As reported earlier,[10] oxygen concentration in the tunnel fluid begins recovery first. Here we see that this is followed by CM in both the tunnel and scala media. The last measure to start a recovery is that of oxygen concentration in the scala media.

Our interest is in the relationship among the exact points of beginning decline and beginning recovery. In order to present a more exact determination of these responses in the many animals used, the times were recorded and submitted to statistical analysis. The cumulative results are presented in later tables.

Series 2: Because CM starts a simultaneous decline in the two fluid compartments sometime after the oxygen begins to decline, the question was asked whether or not some other factor might not be involved in the maintenance of CM. A prominent theory[18] of the generation of CM is that it is a modulation of the current flow resulting from the presence of the positive EP and negative intracellular potential of the hair cells. If such a condition is operating, one would expect CM and EP to decline and recover together.

In this second series of experiments, in addition to the records of oxygen changes in the tunnel fluid, CM and EP were recorded simultaneously in the endolymph of the scala media by a nonpolarizable glass micropipette electrode.

Figure 3A shows the recordings in a typical animal of these potentials following the shut off of respiratory air. Again the first to decline is the tunnel oxygen. For some reason there was a slight rise in the tunnel oxygen, but the early decline is obvious. The second response to decline is EP and finally, shortly thereafter, the scala media CM starts to decline.

After the respiratory air is turned on,

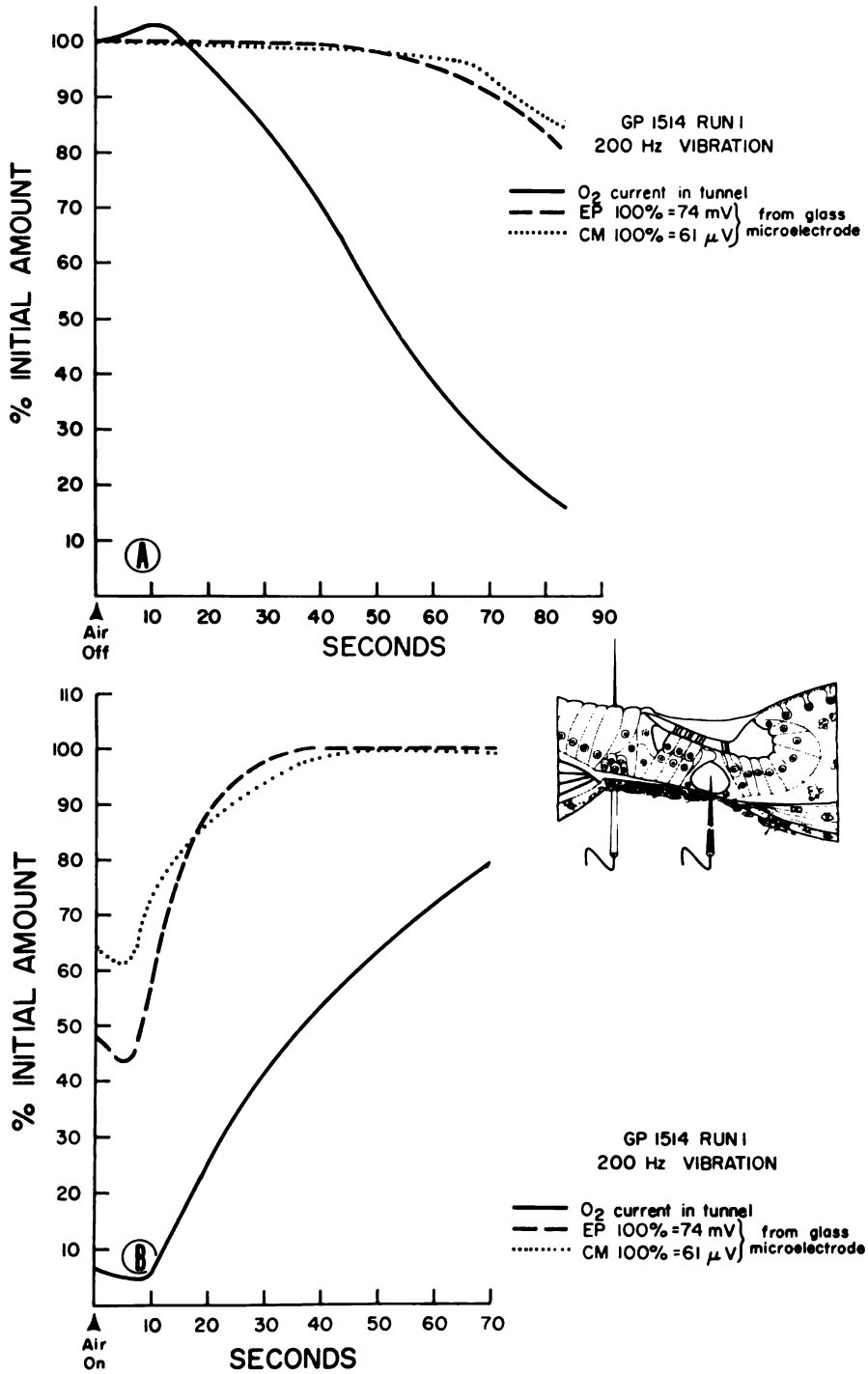

Fig. 3. Decline (A) and recovery (B) of indicated measures determined by a platinum electrode in the tunnel of Corti and a glass micropipette electrode in the endolymph of the scala media.

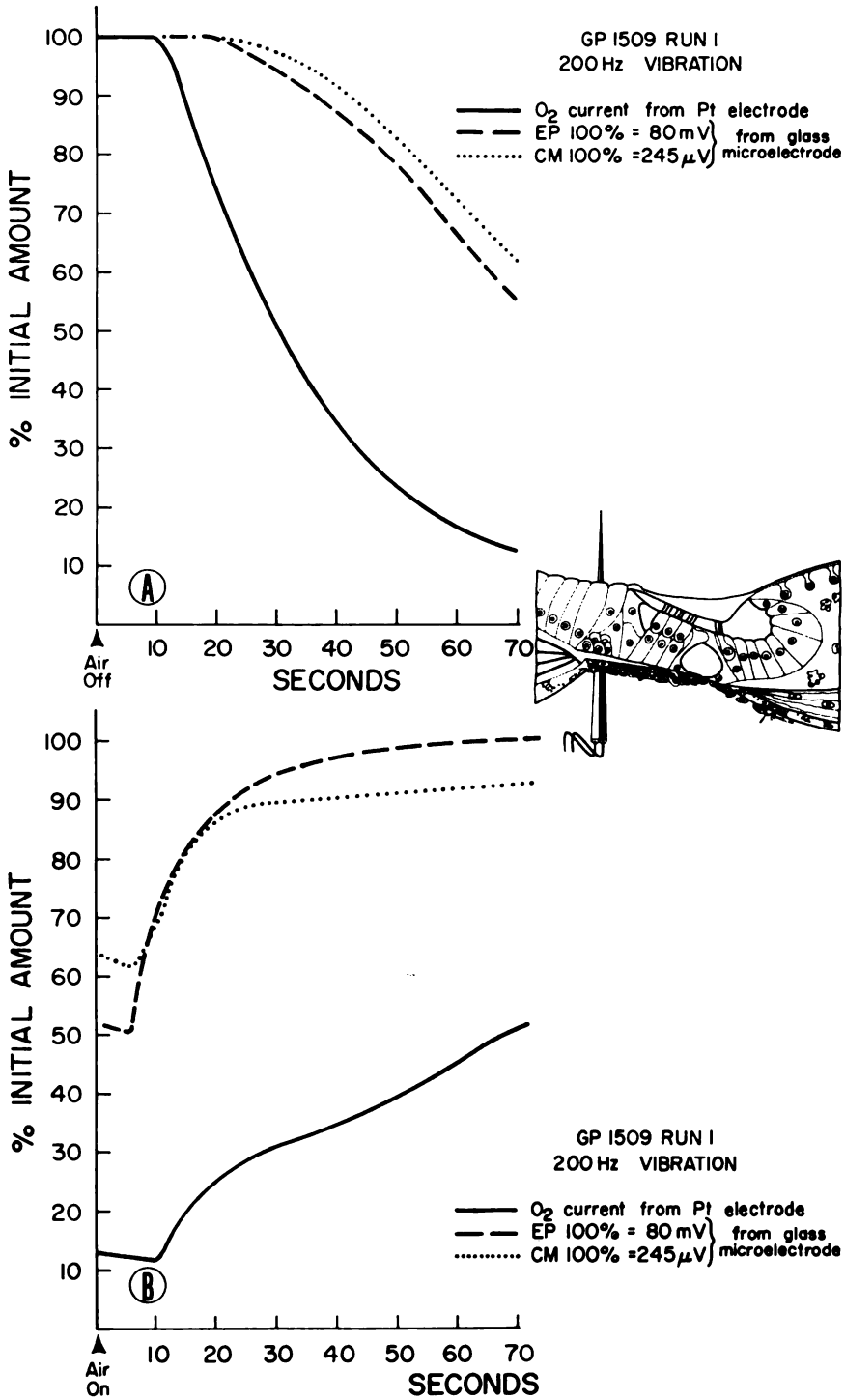

Fig. 4. Decline (A) and recovery (B) of indicated measures determined by a platinum and glass micropipette combined into a double electrode placed in the endolymph of the scala media.

TABLE I

DELAY TIMES FOR RESPIRATORY AIR TURNED OFF OR ON TO DECLINE OR INCREASE IN FLUID OXYGEN. SIMULTANEOUS RECORDINGS

	(a) Air off to O_2 Decline		(b) Air on to O_2 Increase	
	Tunnel	*Scala Media*	*Tunnel*	*Scala Media*
N	52	52	11*	11*
μ	12.1 Sec	14.4 Sec	8.1 Sec	9.9 Sec
σ	3.6 Sec	4.8 Sec	1.4 Sec	1.9 Sec
	P<.0005		P<.0005	

* Data from animals with minimal heart-rate change.

all potentials appear to recover at the same instant as shown in Figure 3B. In this particular animal the return of tunnel oxygen was slightly delayed, but as is shown in the later tables, the differences in these recovery measures are not significant. The data from each of the similar runs in all experimental animals are also summarized in the tables.

Series 3: To complete the measurements so as to have similar ones from each fluid compartment, a dual electrode, consisting of a nonpolarizable glass micropipette electrode and a platinum electrode fitted together under a microscope and glued so that the tips were no more than a few microns apart, was inserted into the scala media endolymph.

Figure 4A shows the recordings from a typical animal of the decline of oxygen concentration, EP, and CM from a dual scala media electrode. The first to decline is the oxygen, followed some seconds later by EP and CM. After the respiratory air is turned on (Fig. 4B), EP and CM start to return within a very few seconds followed shortly by the endolymph oxygen. Under these recording conditions the difference between the CM - EP start of recovery and the oxygen concentration start of recovery is quite significant as will be clarified in the tables to follow.

Analysis of Data. Although each animal gave distinct results, consistency was difficult to determine from the graphs, so in order to determine the sequence of events, similar measures for all animals were grouped and analyzed statistically.

This analysis is presented in the following tables, each of which, it will be noted, has a different sample size. The reason for this is that for any statistical comparison only data from paired electrodes in the same animal were considered.

Also it will be noted that the sample sizes for the "on delay" are small. This is because, during the period of hypoxia, the hearts of some animals showed marked changes in beat rate and strength of contraction, delaying recovery of responses until the recorded EKG returned more or less to normal. Therefore, for the analysis, only data from those animals with minimal EKG changes were used.

The total sample size for any data comparison was, of course, much larger, and similar statistical treatment of these figures did not alter the qualitative results as presented in the tables. The reason the smaller sample size has been used is that the data reflect better controlled experimental conditions.

Our earlier publication[10] on the availability of oxygen in the tunnel fluid, as compared with that in the endolymph during hypoxia was, in most instances, made with each electrode placement in a different animal. In the present experiments, the electrodes were paired in each animal as shown in the inset picture of Figure 2. The data in Table I

TABLE II

DELAY TIMES FOR RESPIRATORY AIR TURNED OFF TO DECLINE IN FLUID OXYGEN, COCHLEAR MICROPHONIC (CM) AND ENDOLYMPHATIC POTENTIAL (EP). SIMULTANEOUS RECORDINGS FOR EACH GROUP

	(a)		(b)		(c)		(d)	
	O_2 (Tunnel)	CM	O_2 (Tunnel)	EP	O_2 (SM)	CM	O_2 (SM)	EP
N	62	62	31	31	79	79	45	45
μ (Sec)	11.7	37.9	10.9	29	16.6	38.5	14.0	31.4
σ (Sec)	4.0	16.4	3.7	12.9	8.5	19.1	4.1	19.9
	P<.001		P<.001		P<.001		P<.001	
	r=.31		r=.23		r=.30		r=.26	

SM - scala media

display the delay times, in seconds, for (a) respiratory air turned off to first noticeable oxygen-current decrease and (b) respiratory air turned on to oxygen-current increase. All measurements were paired from two simultaneously-placed oxygen sensitive microelectrodes. "P" is the probability that the mean delay in the tunnel (μ_1) and the mean delay in the scala media (μ_2) are the same, tested against the alternative that $\mu_2 > \mu_1$ (one-tailed Student's t test).

As can be seen in the table, these results are highly significant and confirm the observation in our earlier report[10] that tunnel oxygen starts to decrease before that of the scala media oxygen.

Our first question, as described in the introduction, was whether the decline in CM resulting from the onset of hypoxia correlated with the oxygen decline in the tunnel or with the oxygen decline in the scala media. By combining data from paired recordings as shown in Figures 2-4, delay times for simultaneous recordings could be made.

Table II shows the delay times, in seconds, from shut off of respiratory air to first noticeable decline in oxygen tension in tunnel fluid or scala media endolymph, EP and CM. For comparison of the differences between sample means, the data are grouped. (a) Delays, air off to decrease in tunnel-fluid oxygen tension and air off to decline in CM. (b) Delays, air off to decrease in tunnel-fluid oxygen and air off to decrease in EP. (c) Delays, air off to decrease in scala media oxygen and air off to decrease in CM. (d) Delays, air off to decrease in scala media oxygen and air off to decrease in EP. "P" in this table is the probability that the paired mean delays are the same tested against the alternative that they are not the same (two-tailed Student's t test).

It makes no difference whether the recording is made in the tunnel or in the scala media, the decline in CM shows the same delay after the respiratory air is turned off, and this beginning decline in CM is much later than the beginning decline of oxygen in either tunnel or scala media. Consequently, these data do not tell us which source of oxygen CM is dependent upon.

The table shows that EP starts a decline later than does scala media oxygen, but still ten or more seconds before CM. All the differences between means in this table again are highly significant.

The data for each comparison were also tested for correlation (r = Pearson product-moment correlation coefficient). That is, the measures were tested to see if, in a single pair of measures, early decline in one was followed by an early decline in the other. As can be seen, the means, although their differences would occur by chance

TABLE III

DELAY TIMES FOR RESPIRATORY AIR TURNED ON TO INCREASE IN FLUID OXYGEN, COCHLEAR MICROPHONIC (CM) AND ENDOLYMPHATIC POTENTIAL (EP)

	(a)		(b)		(c)		(d)	
	O_2 (Tunnel)	CM	O_2 (Tunnel)	EP	O_2 (SM)	CM	O_2 (SM)	EP
N*	19	19	13	13	12	12	7	7
μ (Sec)	8.4	9.2	8.2	8.1	10.2	8.5	10.3	8.6
σ (Sec)	1.5	2.0	1.5	1.5	1.8	2.7	1.0	1.5
	$P<.1$		$P>.1$		$P<.02$		$P<.01$	
	$r=.48$		$r=-.05$		$r=.64$		$r=.67$	

SM - scala media
* Data from animals with minimal heart-rate change

less than once in a thousand, are not very highly correlated, indicating that the two paired-measures are not very dependent on each other.

Because both EP and CM start a decline sometime after oxygen tension in either tunnel or scala media, it would seem that, under normal conditions, there is a storehouse of oxygen which has to be depleted before the discernible changes in the electrical measures are observed. Following the exhaustion of this storehouse, the delay in the return of the various measures after the respiratory air is turned on may be the more realistic determinant of the sequence of events.

Table III shows the delay times in seconds from return of respiratory air to beginning oxygen-tension increase in tunnel fluid or scala media endolymph, and beginning return of EP and CM. All measurements are paired and, again, the data are grouped for comparison of sample means. (a) Delays, air on to increase in tunnel-fluid oxygen tension and air on to beginning recovery in CM. (b) Delays, air on to increase in tunnel-fluid oxygen tension and air on to beginning recovery of EP. (c) Delays, air on to increase in scala media oxygen tension and air on to beginning increase in CM. (d) Delays, air on to increase in scala media oxygen tension and air on to beginning increase in EP. "P" is as defined in Table II.

The first response to start a recovery is the tunnel-fluid oxygen followed immediately, or at the same time by EP and CM. The last measure to begin a recovery is the scala media endolymph oxygen. However, the most significant differences are those between CM and endolymph oxygen, and between EP and endolymph oxygen. There seems to be no relationship at all between tunnel-fluid oxygen and EP. It is interesting to note, however, that the small significance between delays in beginning recovery of tunnel-fluid oxygen and CM would indicate that they start returning at the same time, and this return between the paired measures is somewhat correlated. That is, when tunnel-fluid oxygen shows a relatively early recovery, so does CM. On the other hand, there is no correlation whatsoever between tunnel-fluid oxygen and EP, and their similarity of recovery times are not related to each other ($r = -.05$).

The curious revelation is that scala media oxygen returns last, significantly after both CM and EP. The differences are also fairly well correlated, that is, if CM or EP take a relatively longer time to begin recovery, so does scala media oxygen.

An essential question remains concerning the direct relationship between the beginning decline or recovery of CM and EP when simultaneous data

TABLE IV

DELAY TIMES FOR RESPIRATORY AIR TURNED OFF (a) OR ON (b) TO CHANGE IN ENDOLYMPHATIC POTENTIAL (EP) AND COCHLEAR MICROPHONIC (CM)

	(a)		(b)	
	EP	*CM*	*EP*	*CM*
N	44	44	14*	14*
M (Sec)	28.9	33.4	7.9	8.3
σ (Sec)	19.2	22.5	1.3	1.4
	P<.001		P<.1	
	r=.94		r=.85	

* Data from animals with minimal heart-rate change.

are recorded from a single nonpolarizable glass micropipette electrode as shown in Figure 4.

Table IV shows the delay times, in seconds, for (a) respiratory air turned off to beginning decline in EP and CM and (b) respiratory air turned on to beginning return of EP and CM. The sample number for return of respiratory air data is small because all animals that showed changes in the recorded EKG resulting from the hypoxia were eliminated. "P" is the same as described for Table II.

The data of Table IV, with air turned off, clearly show that EP declines significantly ahead of CM and that these declines are highly correlated.

On the return of respiratory air, both EP and CM start recovery at about the same time. Again, EP starts a bit sooner, but the return difference is not as significant as the beginning decline measure. However, the beginning recovery measures are again highly correlated; EP and CM, for any simultaneous recording, return together.

The data from the above tables are summarized in Figure 5. The beginning declines in the various measures are clearly separated following shut off of respiratory air and all the differences are statistically significant. Oxygen in the tunnel starts first, followed by the oxygen in the scala media endolymph. Considerably later, as though an excess of oxygen were being used up, EP starts to decline followed later by CM.

Recovery shows a different picture. Essentially tunnel-fluid oxygen, EP, and CM all start recovery together. The last measure in these experiments to show evidence of return is the oxygen in scala media endolymph.

DISCUSSION

Our experiment was designed to find out if CM decreased with the early decrease in tunnel oxygen or later with scala media oxygen. The results show that CM starts a decline much later than beginning decline of oxygen in either fluid compartment, and actually does not start decreasing until after EP has started to decrease.

There apparently is a storehouse of oxygen in excess of that required to support the generation and maintenance of EP and CM. Since CM is the last to start a decline, one cannot determine to

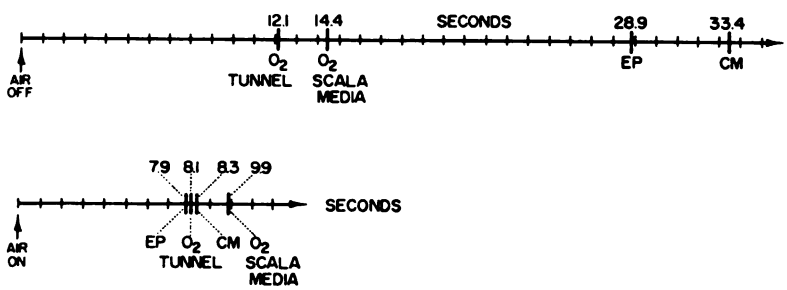

Fig. 5. The time lapse for beginning decline in the indicated measures following shut off of respiratory air and for beginning recovery of the same measures following return of respiratory air.

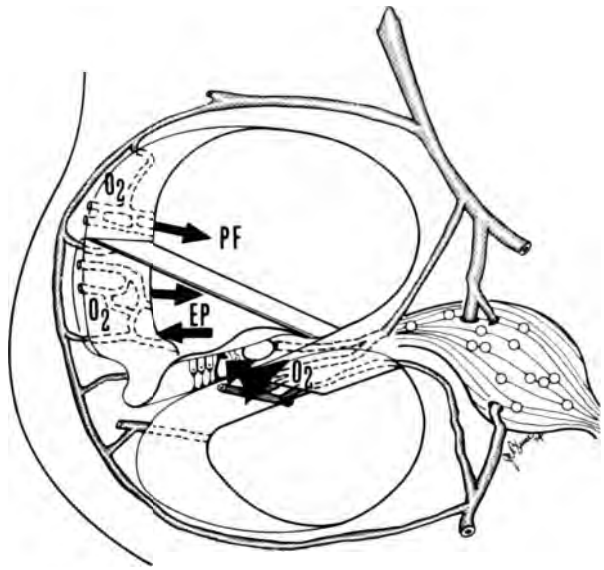

Fig. 6. Oxygen sources and function as indicated by the experiments reported here. The suprastrial capillaries provide oxygen and plasma filtrate (PF) as constituents of perilymph. The positive endolymphatic potential (EP) is brought about by ion transport from perilymph across Reissner's membrane and by special features of the stria vascularis that require oxygen for this function. The generation of CM depends upon tunnel oxygen and EP polarization, but the relationship is not exact.

which source of oxygen CM is more responsive, nor does this measure reveal how CM is related to EP. EP and CM could be responding differently to different sources of oxygen, but the correlation figures shown in Table IV indicate a clear relationship between EP and CM.

The high correlation coefficient indicates that the relationship can be represented by a straight line, *i.e.*, large delays in EP correspond to large delays in CM, and also that the experimental variation among animals is greater than the variability within an animal.

Obviously, there is a definite relationship between EP and CM, but the theory suggesting that CM is produced by a variable resistance directly modulating a current flow produced by the relatively high positive voltage of EP is difficult to reconcile since EP and CM do not change together. Such a theory would require a nonlinear element to account for the stability of CM until EP falls to a certain level.

Unexpectedly, the responses during recovery from hypoxia show a different sequence of events. Tunnel-fluid oxygen, EP and CM return together, whereas an electrode in the scala media detects a recovery in EP before there is a change in scala media oxygen. The biophysical mechanism for the generation of EP is obscure, and this difference in beginning recovery times reflects its complexity. Apparently there are other factors contributing to the generation of EP, and one of these factors, more than likely, involves the diffusion of ions from the perilymph across Reissner's membrane.

The suprastrial capillary[14] network lies in the region of spiral ligament just "above" Reissner's membrane. These capillaries are close to the surface and are arranged in a way to allow the formation of a plasma filtrate. These capillaries also would be subject to hypoxia, but oxygen tension in perilymph was not measured in these experiments.

Our interpretation of the course of events is presented in Figure 6. CM is

at least partially dependent upon two factors: oxygen supplied to the extracellular spaces of the organ of Corti by the spiral vessels, and EP that itself is dependent upon several factors. Those factors determining EP include the diffusion of ions across Reissner's membrane, the availability of which is controlled by the suprastrial capillaries, and the buildup of the appropriate ion concentrations within the endolymph controlled by the special properties of the stria vascularis which requires oxygen for this function. The oxygen released by the capillaries of the stria vascularis is utilized by the stria vascularis itself[15,16] and is not released for the supply of the organ of Corti.

In the experiments reported here EP, as measured by a microelectrode in the endolymph, is a measure independent of the oxygen content of the endolymph. The oxygen that is measured within the endolymph is that which diffuses from the stria vascularis or through Reissner's membrane from the suprastrial capillaries.

EP itself is directly related to the generation of CM as is also the extracellular-space oxygen of the organ of Corti. However, it appears from the data reported here that the role of EP is more complex than that of providing a current flow for modulation by a variable resistance. The effect of a high-positive polarization without current flow enhancing the transduction process at the extremely low energy levels of threshold hearing is more likely the essential reason for its existence.

In answer to the question posed in the introduction, both capillary areas, the spiral capillaries and those of the stria vascularis are important to the adequate function of the organ of Corti: the spiral capillaries directly and the strial capillaries indirectly. Apparently, the suprastrial capillaries also play an important role.

Request for reprints should be sent to Merle Lawrence, Ph.D., The Kresge Hearing Research Institute, University of Michigan Medical School, Ann Arbor, Michigan.

REFERENCES

1. Hawkins JE Jr: Comparative otopathology: aging, noise and ototoxic drugs. Adv Otorhinolaryngol 20:125-141, 1973

2. Johnsson LG: Vascular pathology in the human inner ear. Adv Otorhinolaryngol 20: 197-220, 1973

3. Johnsson LG, Hawkins JE: Strial atrophy in clinical and experimental deafness. Laryngoscope 82:1105-1125, 1972

4. Wever EG, Bray CW, Lawrence M: The nature of cochlear activity after death. Ann Otol Rhinol Laryngol 50:317-329, 1941

5. Békésy GV: D-C potentials and energy balance of the cochlear partition. J Acoust Soc Am 23:576-582, 1951

6. Békésy GV: Gross localization of the place of origin of the cochlear microphonic. J Acoust Soc Am 24:399-409, 1952

7. Misrahy GA, Hildreth KM, Shinabarger EW, *et al*: Endolymphatic oxygen tension in the cochlea of the guinea pig. J Acoust Soc Am 30:247-250, 1958

8. Rice EA, Shinabarger EW: Studies on the endolymphatic DC potential of the guinea pig's cochlea. J Acoust Soc Am 33:922-925, 1961

9. Lawrence M: Inner ear physiology, in Paparella MM, Shumrich DA (eds): *Otolaryngology*. Philadelphia, W.B. Saunders, vol 1

10. Lawrence M, Nuttall AL: Oxygen availability in tunnel of corti measured by microelectrodes. J Acoust Soc Am 52:566-573, 1972

11. Lawrence M, Nuttall AL, Clapper MP: Electrical potentials and fluid boundaries within the organ of Corti. J Acoust Soc Am 55: 122-138, 1974

12. Lawrence M: Direct visualization of living organ of corti and studies of its extracellular fluids. Laryngoscope 84:1767-1776, 1974

13. Davis H: Biophysics and physiology of the inner ear. Physiol Rev 37:1-49, 1957

14. Hawkins JE Jr, Johnsson LG, Preston RE: Cochlear microvasculature in normal and damaged ears. Laryngoscope 82:1091-1104, 1972

15. Thalmann I, Matschinsky FM, Thalmann R: Quantitative study of selected enzymes involved in energy metabolism of the cochlear duct. Ann Otol Rhinol Laryngol 79:12-29, 1970

16. Chou JTY, Rodgers K: Respiration of tissues lining the mammalian membranous labyrinth. J Laryngol Otol 76:341-351, 1962

CONSERVATIVE MANAGEMENT OF MÉNIÈRE'S DISEASE: FURSTENBERG REGIMEN REVISITED

ROGER BOLES, M.D.
SAN FRANCISCO, CALIFORNIA

DALE H. RICE, M.D. ROGER HYBELS, M. D.
WALTER P. WORK, M. D.
ANN ARBOR, MICHIGAN

SUMMARY — This study reviews twenty years' experience at the University of Michigan with 500 consecutive patients suffering from symptoms of Ménière's disease. An especially strong tradition of medical therapy for Ménière's disease has prevailed at the University of Michigan because of the influence of Albert C. Furstenberg, who developed and promoted the Furstenberg regimen of a low-sodium diet and diuretics. It has been our distinct clinical impression over the years that the Furstenberg regimen has been quite satisfactory in relieving the most disturbing symptoms of Ménière's disease in the vast majority of cases and often in patients who have failed other treatment programs. This study quantifies, as much as possible, our extensive experience with this disease and confirms for us the efficacy of this treatment. Relatively few operative procedures have had to be performed for conservative treatment failures in our hands. The success of this conservative management program has been largely dependent upon the strict adherence by the patient to a professionally prescribed, low-sodium diet. Occasional patients with chronic symptoms which are refractory to medical management continue to be a problem, particularly since it is in this group of patients that bilateral involvement tends to ultimately occur.

Ever since 1861, when Prosper Ménière described the clinical picture of vertigo, hearing loss, and tinnitus as a manifestation of an inner ear disorder, his name has been associated with this specific and distressing combination of symptoms.[1] Ménière, in his treatise, was hopeful that in future years microscopic examination of temporal bones afflicted with these symptoms would ultimately reveal the exact etiology of this disorder and end the "blind empiricism" with which it had been treated so unsuccessfully. In the 114 years since Ménière's original essay, we have essentially failed to meet his charge to find a specific etiology and a rational and scientific treatment for his syndrome, despite extensive attempts by many clinicians and scientists. One such study was carried out at the University of Michigan by Furstenberg, *et al* in the 1930's and was presented before the American Otological Society in Atlantic City in 1934.[2] This study was, in great measure, an expansion of similar work done previously by Dederding which related variations in the body, dietary fluids, and electrolytes to remissions and exacerbations of the symptoms of Ménière's syndrome.[3] From their studies, Furstenberg and his group concluded that the tissues involved in Ménière's disease either have an increased avidity for sodium ions or an unusual sensitivity to them. From this conclusion they tried, with rather clear and dramatic success, a treatment program designed to reduce body sodium by restricting it in the diet and by enhancing its elimination through the kidney with the use of the diuretic, ammonium chloride. This initial success in 14 patients was confirmed by subsequent trials with this treatment program in 150 patients as reported in 1941.[4] This treatment program of a low-sodium diet and diuretic gained widespread recognition and approval from

From the Department of Otorhinolaryngology, University of Michigan, Ann Arbor, Michigan.

practitioners both inside and outside of the specialty of otolaryngology, and generally became known as the Furstenberg regimen[5,6] (Fig. 1, Table I).

Fig. 1. Albert C. Furstenberg, M.D.; Dean, School of Medicine (1935-1960); Chairman, Department of Otolaryngology (1932-1957); University of Michigan.

Whereas the surgical treatment for Ménière's disease had been partial section of the VIII nerve, after the initiation of the sodium-elimination program, only six of the 150 patients reported by Furstenberg, *et al* in 1941[4] had had to have this surgical procedure because of their failure to respond satisfactorily to medical treatment.

Because of these initial and continued apparent successes, many patients with Ménière's disease and other forms of dizziness have been attracted to the University of Michigan over the ensuing years. Seldom has there been any expression of doubt as to the efficacy of the Furstenberg regimen at this institution, presumably because of considerable patient and physician satisfaction with it. The recent, great attentions given to other methods of treatment, both surgical and medical, and particularly the advocacy of operative procedures of considerable magnitude,

TABLE I

FURSTENBERG REGIMEN

1. 800-1,000 mg sodium diet
2. Avoidance of preparations high in sodium, *e.g.* sodium bicarbonate, sodium salicylates, etc.
3. Diuretic

suggested that others were not experiencing the same satisfaction that we were with the sodium-restriction program or that perhaps we were not realistically appraising our own results with it. It was largely with this motivation that we reviewed our experience at the University of Michigan with over 500 consecutive cases of Ménière's disease during the past twenty years.

In order to be included in this study, all patients had to have the classic triad of symptoms and additionally had to have audiometric evidence of sensorineural hearing loss. During the span of time of this study, a number of helpful new audiometric tests were developed and employed as they became available. The same was true for vestibular testing. Whenever there was a serious question as to the accuracy of the diagnosis, the patients were referred to specialists in neurology and internal medicine for their evaluations and opinions.

Once the diagnosis of Ménière's disease was established, our basic treatment program was to start the patient on a low-salt diet and a diuretic. The majority of patients had mild and easily controlled symptoms and required only one or two visits to our clinic before we were willing to return them to their family physicians for long-term maintenance care. This paper will deal with the 125 patients who were followed for longer periods of time, usually because of the severity of their disease.

Of this group of 125 longer-term patients, 71 were males and 54 were females. Their ages ranged from 10 to 73 years with the average age being 45.5 years at the time of their first visit (Table II).

The patients in this study group were divided into three classes according to

TABLE II

AGE OF ONSET OF MÉNIÈRE'S DISEASE

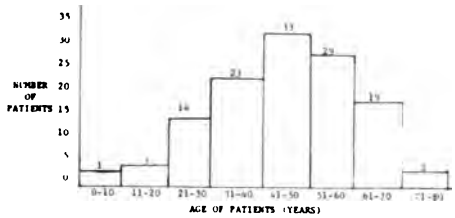

the severity of their disease. If the patient had one or more incapacitating spells a month with nausea or vomiting, he was classified as severe. If a patient had such severe episodes only once or twice every three months, he was classified as moderate. Symptoms less severe than these were considered mild. By these criteria, 103 patients were classified as severe, 18 as moderate, and three as mild. Two could not be accurately classified. Twenty-four patients had bilateral disease.

Almost all patients were treated initially with a low-salt diet which was worked out on an individual basis for each patient by a qualified dietician. These low-salt diets generally allowed the patients 800-1,000 mg Na/day. An occasional patient with mild or moderate symptoms was placed on a no-added-salt diet, which meant adding no salt to one's food either in the cooking process or at the table. In addition, each patient received a diuretic and a variety of other medications. Early in this experience, ammonium chloride was the diuretic used in doses suggested by Furstenberg, specifically 9 g/day. As the thiazides became available, they were used with greater frequency and essentially replaced ammonium chloride. Flushing doses of nicotinic acid were given to many patients. Numerous other preparations were used sporadically, including meclizine hydrochloride, diazepam, and chlorpromazine. The mainstay of treatment, however, was the low-salt diet and the diuretic. If the symptoms continued despite the diet prescribed, the sodium content was reduced further, occasionally to a minimum of 500 mg/day. As symptoms

TABLE III

RESPONSE TO MEDICAL THERAPY IN MÉNIÈRE'S DISEASE

Severity of Disease	*Quality of Response* Excellent	Good	Fair	Poor	*Totals*
Severe	63	26	3	11	103
Moderate	8	9	0	1	18
Mild	3	0	0	0	3

seemed to improve and disappear for two or three months, the treatment program was gradually tapered and titrated against any recurrence of symptoms. This usually consisted of first reducing and finally eliminating the diuretic, followed gradually by a liberalization of the low-salt diet.

The response of the patient to treatment was determined by the degree of relief from vertiginous episodes. If, after the initiation of treatment, the patient had no further spells, the response was considered excellent. If the attacks decreased in severity and occurred no more frequently than one in three months, the response was considered good. If the spells were decreased in severity and occurred no oftener than one per month, the response was considered fair. If more than one attack occurred per month, the response was considered poor. By these criteria, 63 of the 103 patients regarded as severe had excellent responses. Twenty-six of the 103 had good responses. Three had fair responses and eleven had poor responses. Of the 18 patients with moderate symptoms, eight had excellent responses, nine had good responses, and one had a poor response. The three patients followed in the mild group all had excellent responses. (Table III).

Furstenberg, *et al* had noted in their early work with the low-salt diet program that not only were patients promptly relieved by this treatment, but also that the return of symptoms was often immediately precipitated by the use of salt.[2] In our current review, 17 of the 125 patients volunteered this same information; namely, improvement of symptoms when avoiding salt and exacerbation upon resumption of

TABLE IV
CHANGE IN HEARING OVER TIME IN MÉNIÈRE'S DISEASE

Duration of Disease		*Audiogram Results*	
Yrs.	*Air Conduction (Av. at ½, 1 & 2 kHz)*	*Air Conduction (4 kHz)*	*Discrimination %*
5-10	60dB	67dB	55%
11-15	50dB	60dB	55%
16-20	55dB	65dB	54%
>20	50dB	60dB	35%

salt. All of the patients with good or excellent responses were relatively faithful to their diet.

All but one of the 12 patients who had poor responses to this medical therapy had symptoms classed as severe. Ten of these patients had unilateral disease. All but one patient ultimately had a destructive labyrinthectomy with complete relief of further vertigo. The single surgical patient with bilateral disease had one ear which was much more severely affected than the other and had a destructive labyrinthectomy on the more severely affected ear with good relief from further dizzy spells. Nine of the 11 operative procedures were done via both mastoid and middle ear approaches with opening of each semicircular canal as well as the oval window. Two were performed through the ear canal alone with communication of round and oval windows only. The labyrinthectomy was performed only when the patients' symptoms were uncontrolled by the most intensive medical therapy and only when the involved ear had no further useful hearing. Seven of these 11 patients had poor responses to medical management from the outset and had a destructive labyrinthectomy relatively early in the course of their disease. Four of the 11 surgical patients had a long history of disease which had responded well initially to medical management but which ultimately became reactivated with persistence and worsening of symptoms despite conservative treatment.

The relationship of hearing in the affected ear to the duration of the disease is shown in Table IV. It appears that the hearing loss in the affected ear usually stabilizes within five years of the onset of the disease but that the discrimination score may deteriorate even after many years. Nine patients in this group of 125 had a history of the disease for longer than 20 years. Six of these nine patients eventually developed bilateral disease.

DISCUSSION

Since the etiology and pathophysiology of Ménière's disease remain obscure, treatment of all varieties must still. therefore, be considered empirical. We have generally operated under the principle that under such uncertain circumstances, the most conservative treatment program which will give acceptable relief from symptoms is probably best justified in most instances.

As was stated early by Furstenberg, the success of medical therapy for Ménière's disease will be greatly dependent upon the strictness with which it is prescribed by the physician and dietician and also with which it is followed by the patient himself. We believe much of our continued success with this program is premised on our careful adherence to these principles of close therapeutic control.

Although we have tried a number of auxiliary medications to supplement our basic treatment program through the years, we must emphasize that we have depended most heavily upon dietary sodium restriction as the primary treatment, with the use of diuretics in the more troublesome cases. Patients who will need an operative procedure usually have a poor response to medical management from the outset. The distressing feature of eventual bilateral involvement, in many patients who have long-standing symptoms and

who respond poorly to medical management, begs for a better solution to these particular patients' problem than a destructive operation.

CONCLUSIONS

The vast majority of patients with Ménière's disease can be managed adequately with a strict low-salt diet supplemented when necessary with the use of diuretics.

Destructive labyrinthectomy should seldom be necessary but continues to be a satisfactory solution to the problem of unilateral Ménière's disease which is refractory to medical management.

Bilateral Ménière's disease is uncommon, and when it does occur, it is usually in patients with long-standing symptoms which have generally responded poorly to medical treatment.

The pathological processes of Ménière's disease require greater clarification in order to develop more truly rational treatment programs.

Request for reprints should be sent to Roger Boles, M.D., School of Medicine, Department of Otolaryngology, Room 495 U, University of California, San Francisco, California 94143.

REFERENCES

1. Ménière P: Memoire sur de lesions de l'oreille interne donant lieu a des symptoms de congestion cerebrale. Gazette Medicale de Paris 16:597, 1861

2. Furstenberg AC, Lashmet FH, Lathrop F: Ménière's symptom complex: medical treatment. Ann Otol Rhinol Laryngol 43:1035-1046, 1934

3. Dederding D: Our Ménière treatment (principles and results). Acta Otolaryngol (Stockh) 16:404-415, 1931

4. Furstenberg AC, Richardson G, Lathrop F: Ménière's disease; addenda to medical therapy. Arch Otolaryngol 34:1083-1092, 1941

5. Brown MR: Medical treatment (Furstenberg method) of Ménière's syndrome. JAMA 108:1158-1160, 1937

6. Bartels EC: Diagnosis and treatment of Ménière's disease. Med Clin North Am 22: 695-700, 1938

DISCUSSION

LESTER A. BROWN, M.D.: Do you have it in your paper what your diuretic of preference was and what the doses were?

ROGER BOLES, M.D.: Yes.

LESTER A. BROWN, M.D.: Would you give us those?

ROGER BOLES, M.D. (closing): The medications that were used, in general, have changed a great deal over the twenty years, as have the diuretics.

Dr. Furstenberg used ammonium chloride and any of you who have ever used that know what great difficulty the patients had in swallowing 9 g of ammonium chloride a day. They are huge pills and often caused gastric upset.

About ten years ago, we began to phase over to the thiazides and currently are using most commonly the hydrodiuril preparation, 50 to 100 mg a day, depending on the severity.

I must say, however, that the essence of the treatment, as we have experienced it, is the low sodium diet; and simply bringing that sodium down just as strictly as one can to the levels used in the people with advanced cardiac disease, is the heart of the program.

JUERGEN TONNDORF, M.D. (New York, New York): My remarks will be directed toward the papers by Drs. House and Michelson, and they will be limited to the problem of signal processing.

The application of electrical wave forms these gentlemen are using today, is, in my opinion, not the right way to go about this problem.

I have a few slides here which most of you have seen in a presentation at the 1972 meeting of this society by Drs. Kiang and Moxon (Trans Am Otol Soc 60, 72-89, 1972). The first slide (K. & M., Fig. 3) shows the result of applying an electrical wave form. The input-output curve is extremely steep, while an acoustic stimulus produces the usual gradual one – that is one source of trouble.

The next slide (K. & M., Fig. 4) shows the PST histogram of a single nerve fiber in response to the acoustic wave-form of a click, and you see the typical two or three time type of "ringing."

With an electrical wave-form you get what is known in the trade as an "on" response and nothing else.

And, the third problem is in the next slide (K. & M., Fig. 1). On top are tuning curves in response to acoustic inputs. Note their sharp tuning to given frequency ranges. In the lower graph are tuning curves in response to electrical inputs. They are not sharply tuned, they are practically flat.

Now, the explanation for these findings. The last slide is from my earlier cochlear model studies (J Acoust Soc Am 32, 1344-1355, 1960, Fig. 2). This is a time/distance/amplitude plot in response to a click, *i.e.*, the wave forms at ten different points, and one recognizes the traveling wave going along the cochlea. You

see that with distance the intervals between wave crests are increasing. The response at a given point is a "ringing" with time, and acoustically-evoked tuning curves or PST histograms replicate this exactly – Dr. Kiang has very good neural data which replicate exactly this time/distance plot.

Now, what do we learn from this?

In the case of an electrical input, it is the absence of the mechanical preprocessing of the traveling wave which sends the wrong signal into the cochlear nerve.

I like to use an analogy here to make my point clear. In the early days of wireless telegraphy, where channels were so bad that their band widths were about 10-20 Hz wide, the only type of signal you could use was Morse code, and with that you got your message over.

If somebody had tried to talk into such a channel you would have been able to hear that somebody was speaking at the other end, but you could not have made out anything because he had not used the proper code. One had to translate one's spoken message first into the proper code, Morse code, and then you were in.

Let me make one last remark. Please do not misunderstand me – we, as scientists, are not against attempts to make a cochlear prothesis; we are being misread very often in this respect. We are all for it, but we feel you ain't doing it right!

We believe we know what type of signal code is required to stimulate the VIII nerve, and that is definitely not the acoustic waveform or the electrical equivalent of it.

We know what such a code should be, and the only thing which has to be worked out is the "how," and that can be worked out. You need a computer, and once the computer task is understood, you can miniaturize the instrument and carry it around.

We are only suggesting that this would be a more promising approach, and I hope that my remarks will be taken as a constructive criticism, which is the way they have been meant.

William F. House, M.D. (closing): I think what Juergen has to say has a lot of merit. I think you have to realize though that we are dealing here with very, very sick inner ears and whether or not these ears are going to function as a normal ear, especially a normal ear with hair cells. It is obvious when you knock the hair cells out as Dr. Kiang did and got those flat curves, you are dealing with an entirely different system in terms of stimulation.

So, my feeling is very strong that we are probably going to gain a certain amount from all of these animal experiments but ultimately there will have to be a good deal of empiric type of stimulation of these inner ears in order to find out what we can do with them.

I would like to emphasize one point and that is, it seems to be the feeling that all we are going to have to do is to develop the perfect system, stick it in this patient's ear and say, "Go forth and hear!"

It is not going to be that simple. Probably the greatest physician of all time was able to tell his patient to "Pick up thy bed and walk!" and the patient did it.

But the rest of us have to get our patients on crutches, canes and so on and a few months later, they are walking and that is the exact same situation with these sick inner ears.

You are never going to put something in and have the patient just suddenly go away hearing.

For example, those of you who have operated on totally dead ears on patients who have severe otosclerosis, not totally dead, but at least they have no audiometric responses, find those ears will come up in some cases to 70 dB. The patient now has a flat 70 dB response after his stapedectomy and you will notice that the patient at first has zero discrimination. Three months later the patient will have 10 or 15%.

Six months later he will have maybe 40 or 50% and now the patient is willing to accept a hearing aid, thus bringing his level up to maybe 40 dB, with a 40 or 60% discrimination.

What I am saying is after an ear is really damaged by any disease, then it takes a long time for that ear to recover.

So one of our complicated problems is going to be, no matter what we develop in the way of a stimulating current, we are going to have to be able to put the patient through a period of rehabilitation. No matter what theories are behind what we are doing, there is going to be this very complicating factor of how well the inner ear will recover, how many fibers are going to be left that can be stimulated, and so on.

So it is not really a simple problem in terms of just figuring out nerve responses in animals, I think there has got to be a lot of empiricism and we are just going to have to work at it over a long period of time.

Robin P. Michelson, M.D. (closing): I appreciate very much Dr. Tonndorf's remarks.

However, I think that I would like to point out that what the patient hears or what the percepts of these various stimuli are is the important thing.

For instance, our patients very clearly describe a perceptual difference between a sign wave, an electrical sign wave stimulus, a square wave – I am sure Dr. Tonndorf will appreciate the significance of this – the sign wave is a prime mathematical function. It consists only of the fundamental.

A square wave on the other hand is a complex wave form represented by the fundamental in every third upper harmonic.

Now, somehow or other these patients are able to distinguish those two wave forms even at high frequencies. They are also quite clearly able to recognize electrical white noise or narrow-band white noise centered around the higher frequencies and distinguish this from the other two types of stimuli.

Paradoxically, however, pitch scaling in the high frequency range is very, very poor and we think this is the reason that speech discrimination is impossible at this point.

GRAFTING MATERIALS AND METHODS IN RECONSTRUCTIVE EAR SURGERY

RODNEY PERKINS, M.D.
PALO ALTO, CALIFORNIA

SUMMARY – The evolution of tympanic membrane grafting over the past 20 years has been based on biologic tissues of mesodermal origin which contain a collagen matrix. The dominant theme of this evolution has been the modification of these collagen membranes by physical and chemical agents to achieve a more ideal graft. The graft material and the operation should be suited to specific problems. Current operative techniques and graft materials are discussed. It is believed that there will be continued modification and manipulation of collagen in the future to achieve a more ideal graft for tympanic membrane restoration.

Over the past 25 years there has been a progressive improvement in the ability to surgically close perforations of the tympanic membrane. Various materials have been used in combination with a wide variety of surgical procedures in an effort to arrive at a restoration of both structure and function of this unusual and important membrane.

The earlier pioneers employed skin grafts in attempts to restore the integrity of the membrane. Although these epidermal grafts were successful in many cases, they have largely been abandoned and replaced by mesodermal grafts of diverse origins. Today, we see many types of materials of mesodermal origin employed in reconstruction of the tympanic membrane. They are placed in different positions using a plethora of techniques but have generally been accepted by almost all otologists as the material of choice.

It has been found useful in discussing this subject and in organizing my thoughts to think of these mesodermal tissues as material, rather than this tissue or that tissue, treated in this manner or that manner. These are, in fact, all biomaterials. For example, a piece of dried, dehydrated autogenous temporalis fascia is widely used in otologic surgery. This is said to be a "tissue graft." Yes, it is from a tissue source, but it is no longer living tissue. The original nature of the tissue has been dramatically changed by the drying process. It has been devitalized, dehydrated, and slightly denatured by the drying process. It is more appropriate to think of this fascia now as a piece of nonviable biomaterial of autogenous mesodermal origin. By doing so we can better understand the function it serves and develop a basis for understanding the nature of some of the homograft materials now being employed and provide a framework from which we can develop more ideal materials in the future.

THE BASIS OF TYMPANIC MEMBRANE GRAFTING

In some of the earlier literature on tympanic membrane grafts one sees expressed the terms "high metabolic rate" graft and "low metabolic rate" graft. The former is usually applied to autogenous skin grafts and the latter to materials of mesodermal origin. The higher perforation rate of the autogenous skin grafts is said to be due to its "higher metabolic rate," whereas the mesodermal grafts were thought to perforate less due to a "lower metabolic rate." Presumably this meant that the mesodermal grafts required less vascular and nutritive support and therefore in a compromised situation, had a

higher chance of survival. This line of reasoning does not explain the higher survival of the mesodermal grafts. While it is true that the viable autogenous ectodermal grafts need neovascularization to survive, it is not true for the mesodermal material. The difference in success lies in the fact that these are two different methods of membrane restoration rather than factors related to the "metabolic rate" of the tissues employed. The autogenous skin graft becomes the graft membrane *per se* if successfully neovascularized before skin death. The mesodermal material only serves as a superstructure or scaffolding for growth of epithelium from the adjacent ear canal wall and therefore is only part of the new membrane. Its function is that of superstructure or guide plane for the new epithelium. This superstructure may remain briefly and be replaced by host fibrocytic infiltration and new collagen deposition as with autogenous fascia or may be turned over more slowly, as is thought to occur in aldehyde crosslinked homograft tympanic membranes.

One of the important facts which emerge from this understanding is: superstructure graft materials need not be viable to perform their function in tympanic membrane closure. This should be quite obvious when one considers dried autogenous fascia grafts. These grafts have been dehydrated and frequently heated at supraphysiologic temperatures and still perform quite well as a graft superstructure material.

The Common Denominator. All the superstructure grafts that I have heard about are of mesodermal origin. Autogenous fascia, autogenous perichondrium, autogenous vein, homograft tympanic membrane, homograft dura, homograft fascia, homograft pericardium, homograft omentum, heterograft serosa, heterograft tympanic membrane, and probably others have been used in tympanic membrane restoration. All of these are used in a nonviable state. Why is it that all of these are of mesodermal origin? Why is it that all of these work a certain percentage of the time? What do these tissues have as a common denominator that makes them useful as a superstructure graft? All of these tissues contain a collagen matrix that is the structural layer necessary to perform a graft superstructure function, *i.e.*, support migration of host epithelium.

Modified Collagen Membranes: The Evolutionary Theme. Collagen matrix grafts were introduced to tympanic membrane surgery in the 1950's in the form of autogenous vein and fascia. These were employed essentially as viable and unmodified. Initially, they were employed as a medial surface graft and later were used as a lateral surface graft. However, in both grafting positions the function remains that of a superstructure for epithelial migration.

During the late 1950's and early 1960's we see the beginning of what I believe to be the dominant theme of tympanic membrane grafting evolution: the progressive modification of collagen matrices to achieve a more ideal graft material. These modifications become more apparent with a review of the past 20 years.

Shortly after the introduction of autogenous vein and autogenous temporalis fascia, surgeons began drying or dehydrating the fascia prior to use. I suspect that this was an accident in the beginning as are many things in scientific evolution. One can easily imagine the fascia, drying out on the back table while the operation progressed. However, such a graft was placed, and it worked. Most of us now routinely dry the fascia either by air drying at room temperature or accelerate the process by placing a lighted bulb near the fascia. We do this to facilitate fashioning it to size and to simplify our ability to manipulate it into the desired position before rehydration occurs and the tissue becomes less manageable. However, from an evolutionary point of view, the air drying introduced a modification into the tissue: it devitalized it and dehydrated it. When the lighted bulb adds heat to the tissue, it further alters it by slightly denaturing the protein. What we are in effect doing in



Fig. 1. Chart illustrates progressive modification of grafting materials.

this sequence is trading the viability of the material for the technical advantages that the dehydration affords. We are employing two modifying agents, evaporation and heat, to give us this new nonviable denatured collagen matrix.

We can follow this evolution in more detail by examining further developments in tympanic membrane grafting materials (Fig. 1). During the 1950's, the tissues employed were native and viable. As we have discussed above, the dehydrated fascia (F_D) signalled a change.

In the early 1960's, the report of Chalat on his attempt to use fresh homograft tympanic membrane as a graft material was another significant departure (Fig. 1, [H_c]).[1] The variation here is not so much the modification of a collagen matrix but a change in the source material of this matrix. He did not introduce chemicals into his homograft holding solution, but the collagen matrix did have a different architectural structure than fascia or vein. In that sense, the collagen matrix was modified, but this was accomplished by source selection rather than by chemical or physical modifiers.

Jean Marquet introduced an additional factor by using a chemical agent, Cialit,®* as a sterilizing agent in the solution for storage of homograft tympanic membrane.[2] The Cialit® prevents bacterial growth and, thus, counters the potential effect that proteolytic enzymes from such growth might have on the protein structure of the collagen and its interstitial substance.

In 1968, Glasscock and House reported using two other agents, freezing in combination with isopropyl alcohol (Fig. 1, [H_{GH}]).[3] In this instance, both a physical modification (freezing) and a chemical one, *i.e.*, dehydration by the alcohol, have been employed.

In 1969, our initial experience with homograft tympanic membrane modified with formaldehyde was reported (Fig. 1, [H_P]).[4] The formaldehyde not only serves as an excellent sterilizing agent for both bacteria and for many viruses, but also effects a more specific change in the collagen matrix. The aldehyde interacts chemically with the collagen molecule to give three advantageous modifying effects. It increases tensile strength, and evidence indicates that it reduces the antigenicity.[5,6] In addition, the crosslinking creates a memory in the matrix for its configura-

* Asid Institut, BMBH, Munchen, Lohhof, Germany.

tion at the time of crosslinking. Here, then, from our evolutionary view, we have added a specific chemical alteration of the collagen molecules and created a membrane which retains the desired shape.

In 1973, another departure was introduced by Claus Jansen (Fig. 1, [H_J]).[7] It is a source modification similar to that of Chalat. Jansen used heterograft tympanic membrane of bovine origin in successful closure of perforations. This further supports the migratory plane theory and again emphasizes that the membrane need not be viable, need not be autogenous, nor even homologous. However, it still is a collagen matrix.

The last item in the evolutionary table is the formaldehyde formed autogenous fascia graft (Fig. 1, [FFF]).[8] This modified membrane evolved from seeing the advantages that the conical shape of formaldehyde crosslinked homografts afforded in hearing improvement and reduced blunting and lateral displacement. The graft material and surgical method are described in more detail later in this paper. The graft represents a biomaterial of autogenous fascia modified by dehydration, heat, and chemicals (aldehyde crosslinking) which retains the conical shape of the tympanic membrane during implantation.

Through these years, most of these changes have been made empirically by surgeons in an attempt to improve their results. Each small variation is not noticed as clearly as we can note it with retrospective vision. However, the trend is clear, logical, and will continue to unfold more dramatically in the next few years.

SURGICAL METHODS FOR USE WITH COLLAGEN MEMBRANE GRAFTS

The collagen membrane material is only one facet of the successful restoration of tympanic membrane function. Without a well-designed operative procedure and technique by the surgeon, the type graft employed is a moot point.

Collagen membranes are usually used with techniques that either place the membrane medial to the remnant tympanic membrane or lateral to the deepithelized remnant. Problems are associated with both of these techniques when used in total tympanic membrane perforations.

Medial surface collagen membrane grafts have been used longer than lateral surface grafts. They are the method of choice in perforations that are clearly posterior to the malleus. Autogenous fascia placed on the medial surface of a posterior perforation has almost assured perforation closure with little chance of complication. However, in total tympanic membrane perforations or in perforations in which there is a substantial portion of the perforation anterior to the malleus, this grafting technique runs into problems and has a higher perforation rate than is acceptable in cases where ossicular anatomy and function are normal. At least a 5% perforation rate is likely.[9]

In these cases, the failures are usually anterior-inferior. This is due to the poor apposition of the graft to the medial surface of the inferior annular rim or to incomplete removal of the epithelium that has migrated over the edge onto the medial surface. This same incomplete removal can also result in residual epithelium in the middle ear.

Lateral surface grafts in similar large or substantially anterior perforations have an exceptionally high rate of closure which in good hands is virtually 100% However, this benefit is too frequently dulled by significant blunting and lateral displacement in the healed membrane and its consequences to hearing improvement. Another less frequent complication of lateral surface autogenous fascia grafts is the late appearance of an expanding epithelial cyst hidden in the blunted anterior sulcus.

Total and Anterior Perforations with Intact Malleus

In an effort to combat the complications of both medial surface and lateral surface grafts and to find a grafting method that could be used with any collagen membrane graft, the following

technique has evolved. It can be used in all total tympanic membrane perforations and works well with non-processed autogenous fascia, formaldehyde formed autogenous fascia, homograft tympanic membrane with ossicles en bloc or any other collagen membrane graft materials. It will be described here utilizing a formaldehyde formed autogenous temporalis fascia graft in a total tympanic membrane perforation with no ossicular disease. In my opinion, this biomaterial is the one of choice in this clinical condition.

Preparation of the Formaldehyde-Formed Autogenous Temporalis Fascia. The procedure is done under local anesthesia, if no cholesteatoma is present, in adults. The fascia is obtained from the lateral surface of the temporalis muscle through a separate incision. A separate incision is suggested because the fascia found at the upper extent of a post-auricular incision or an extended post-auricular incision is frequently thicker and more irregular due to its attachment to the skull at the temporal line.

A piece of fascia about 2 cm in diameter is removed and spread on a cutting block. Any attached muscular tissue is removed. The fascia is placed between the layers of a cotton gauze sponge and squeezed between the fingers. This removes any attached blood clot or serum on the graft surface.

At this point a metal male mold,* shaped like the medial external auditory canal and tympanic membrane, is employed (Fig. 2A). The fascia is pulled onto the mold in such a manner that about 3-4 mm of fascia is present on the anterior canal wall portion of the mold. The tympanic membrane portion is completely covered and 5-10 mm of fascia extend onto the posterior superior canal wall portion of the mold (Fig. 2B). Care is taken to eliminate any excess tissue in the anterior sulcus area of the mold. Any bunching or folding of the tissue in that area is worked away toward the posterior superior canal wall area. Redundant tissue is more tolerable in this latter area, whereas it might tend to cause blunting if present in excess in the anterior sulcus zone.

Fig. 2. A) The metal male mold shaped like the medial external auditory canal and tympanic membrane. B) The patient's fascia is draped on the mold, air dried, and fixed with buffered formaldehyde.

The metal mold and fascia are then air dried using a small electric dryer. The dryer is placed about eight to ten inches from the mold. Adequate drying has occurred when the tissue is tested with a blunt probe and all softness is gone, generally taking about five to ten minutes.

The dried fascia and mold are then placed in a solution bath of buffered formaldehyde, 4% pH 5.6, for about six minutes. If a little more stiffness is desired, this can be effected by increasing the time in this solution.

The fascia and mold are then placed in two successive rinsing baths of physiologic irrigating solution for five minutes each. The now formed fascia is then removed from the mold and placed in a third rinsing bath for five minutes. Any rough edges are trimmed at this time and the shaped graft is ready for implantation.

Surgical Implantation Technique. Through the transmeatal approach, an extended posterior vascular strip flap is created (Fig. 3). This flap is retrograde elevated several millimeters using a back-angled elevator.**

A postauricular incision is made and dissection is carried anterio-medially to the posterior lateral bony rim of the external canal. The previously delineated

* Hear America Corporation, Sunnyvale, California
** Storz Instrument Co., St. Louis, Mo.

Fig. 3. Canal incisions are made to create a posterior skin flap. The connecting incision (dotted line) is made as near to the posterior rim of the perforation as possible.

Fig. 4. A small amount of bone removal at the posterior superior rim of the bony external canal facilitates the view of the anterior sulcus.

posterior vascular strip is elevated and retained under the protective blade of a special tympanoplasty retractor.*

In order to clearly view the anterior canal sulcus, it may be necessary to remove a small amount of the rim of the posterior superior bony canal near the spine of Henle (Fig. 4).

Fig. 5. A) A double-edged sickle knife is used to make an incision in the anterior rim of the perforation and an incision along the posterior periostium of the malleus. B) Using an angled canal elevator the outer squamous epithelium is separated from the middle fibrous layer of the tympanic membrane.

The anterior edge of the tympanic membrane perforation is incised and an incision is made in the posterior periosteum of the malleus (Fig. 5A). The epithelium on the malleus is carefully dissected off in continuity with elevation of the epithelium of the pars flaccida area. The outer squamous epithelium is separated from the middle fibrous layer of the tympanic membrane (Fig. 5B). This dissection is carried forth until the entire remnant tympanic membrane is elevated to the canal wall.

The anterior-superior flap, thus created, is retrograde elevated about 5 mm with the back-angled elevator (Fig. 6). *The remnant tympanic membrane and annulus are then removed.* The formed fascia is then introduced into the canal and placed into anatomical position. Care is taken to be sure the graft is on the bone of the anterior sulcus and on the manubrium of the malleus.

Using a sharpened wood applicator saturated with methylene blue dye, the midpoint of the malleus is marked on

---

* Storz Instrument Co., St. Louis, Mo.

Fig. 6. Using a back-angled canal elevator, the anterior superior skin flap is retrograde elevated.

the lateral surface of the fascia graft. The formed fascia is withdrawn and placed on the cutting block. Using a number 11 scalpel blade, a small incision is made at the dye mark.

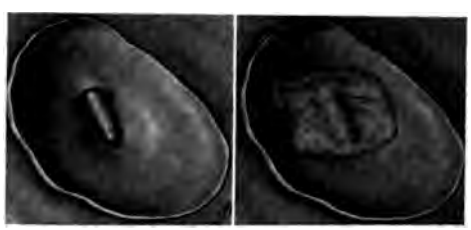

Fig. 7. A) The inferior one-half of the malleus manubrium projects through the slit and lies to the fascia graft. B) A small piece of nonprocessed fascia is placed over the exposed manubrium.

The graft is reintroduced into the canal. The slit is maneuvered over the malleus tip and the graft placed back in its previous position (Fig. 7A). A small piece of dehydrated, but nonformaldehyde treated fascia is then placed over the exposed manubrium (Fig. 7B). The malleolar slit arrangement helps to prevent lateral displacement, both in the early postoperative period due to middle ear bleeding, and in the later period when displacement of the malleus might occur due to graft tightening.

The previously elevated anterior superior canal skin is rolled back over the sulcus flange of the formed fascia. A small slit is made in the canal skin flap to prevent a webbing effect (Fig. 8). The anterior sulcus area is then packed with chloramphenicol soaked gelatin (Gelfoam®)* pledgets. The postauricular wound is closed with interrupted 3-0 subcuticular Dexon suture.

Through the transmeatal view the posterior vascular strip canal skin flap is replaced in its normal position such that it overlies the posterior canal portion of formed fascia graft (Fig. 8). The remainder of the canal is packed with chloramphenicol soaked gelatin (Gelfoam®) pledgets. An expanding plastic

Fig. 8. The anterior and posterior canal skin flaps are placed over the flange of the homograft. A small slit is made in the anterior flap to prevent a webbing effect.

* The Upjohn Co., Kalamazoo, Mich.

Fig. 9. The medial canal is packed with antibiotic soaked Gelfoam® pledgets and plastic sponge packing is placed in the lateral canal.

sponge pack is introduced into the lateral external meatus with a special applicator (Fig. 9). The plastic packing is removed in the office one week later using the stereo operating microscope. Antibiotic ear drops are used two weeks after the operation to remove the more medially placed gelatin sponge packing.

Results with this chemically modified collagen have been excellent. The perforation rate has been 1% in over 60 cases. It has been particularly effective in reducing blunting and lateral displacement. In the first 41 cases with normal ossicular chains, 71% had closure of the air-bone gap to 1-15 dB.[8]

Large Membrane Perforations with Malleus-Incus Disease

In cases which have pars tensa perforation and significant malleus disease, currently a similar operative technique is used to that just described with the formaldehyde formed fascia. However, in these cases, a formaldehyde crosslinked tympanic membrane with malleus-incus en bloc is employed. The formaldehyde processing is particularly important in en bloc homografts since the incudomalleolar joint is unstable unless strengthened by crosslinking with aldehydes. The homograft incus is placed on the stapes if possible and sometimes connected to the stapes with

CLINICAL CONDITION	OPERATIVE TECHNIQUE	GRAFT MATERIAL: SOURCE	GRAFT MATERIAL: MODIFICATION
• POSTERIOR PERFORATION	• PERFORATION EDGE REMOVAL • TYMPANOMEATAL FLAP • MEDIAL SURFACE GRAFT	AUTOGENOUS TEMPORALIS FASCIA	• NON VIABLE • DEHYDRATED
• TOTAL OR ANTERIOR PERFORATION • OSSICLES INTACT	• ANTERIOR CANAL FLAP • REMNANT ANNULUS REMOVAL • SLIT IN GRAFT FOR MANUBRIUM	AUTOGENOUS TEMPORALIS FASCIA	• DEHYDRATED • MOLDED TO ANATOMICAL SHAPE • FORMALDEHYDE CROSSLINKED
• PARS TENSA PERFORATION • MALLEUS-INCUS DISEASE • WITH OR WITHOUT CHOLESTEATOMA	• ANTERIOR CANAL FLAP • REMNANT ANNULUS REMOVAL • INTACT CANAL WALL TECHNIQUE IF CHOLESTEATOMA	HOMOGRAFT TYMPANIC MEMBRANE WITH MALLEUS-INCUS EN BLOC	• FORMALDEHYDE CROSSLINKED

Fig. 10. Current techniques and biomaterials of choice in tympanic membrane reconstruction.

a wire prosthesis. Continuity with the stapes may be effected with a homograft incus prosthesis (HIP) at a second stage.[10]

The perforation rate in these formaldehyde-processed homografts has been 11%. These are employed in cases that are difficult ossicular reconstructive problems. The 11% perforation risk is worth the marked advantage of having the attached malleus-incus to work with in these difficult ossicular chain problems. Should a perforation occur, they are usually not large and can be repaired at a second stage.

At the present time, the homograft tympanic membrane with ossicles en bloc is the method of choice in such conditions.[10] They have also been used in tympanomastoid reconstructions of ears that have had previous radical surgery. A graphic summary of the indications, technique, and graft material that I currently employ is seen in Figure 10.

CONCLUSIONS

The evolution of tympanic membrane grafting has been the province of the last 20 to 30 years and has followed a rather empirical course. Although numerous graft materials are used, they all have as a common denominator the collagen matrix which forms a superstructure for migration of host epithelium.

During this period, modification of the collagen membrane grafts has evolved. This modification now runs the spectrum from simply drying and devitalizing autogenous fascia to aldehyde crosslinking homologous collagen in tympanic membranes. As in other types of evolution the reason is to gain advantage; in this case: advantage technically, advantage in reducing complications, and, therefore, advantage in restoration of function.

The concept of modification of collagen membranes is not currently embraced by all otologists and valid differences of opinion exist.

The various collagen membrane grafts employed today have different characteristics and each has advantages when they are employed in specific situations. A philosophy that dogmatically employs a singular surgical technique and a singular collagenous material to all cases seems to ignore this evolution and the present state of the art.

Over the next few years, we shall see more sophisticated modifications and manipulations of collagen that will continue the trend toward the utlimate evaluation of a biosynthetic tympanic membrane prosthesis.

Request for reprints should be sent to Rodney Perkins, M.D., 1801 Page Mill Road, Palo Alto, California 94304.

REFERENCES

1. Chalat NI: Tympanic membrane transplant. Harper Hosp Bull 22:27-34, 1964

2. Marquet J: Reconstructive micro-surgery of the eardrum by means of a tympanic membrane homograft. Acta Otolaryngol (Stockh) 62:459-464, 1966

3. Glasscock ME III, House WF: Homograft reconstruction of the middle ear: A preliminary report. Laryngoscope 78:1219-1225, 1968

4. Perkins R: Human homograft otologic tissue transplantation: buffered formaldehyde preparation. Trans Am Acad Ophthalmol Otolaryngol 74:278-282, 1970

5. Furthmayr H, Timpl R: Structural requirements of antigenic determinants in the aminoterminal region of the rat collagen oc 2 chain. Biochem Biophys Res Commun 47: 944-950, 1972

6. Brunner H, Dichtl M, Steffen C: Immunogenitat und Spezifitat von chromstabilisiertem Kalbskollagen. Z Immunitaetsforsch 142:460-470, 1971

7. Jansen C: Heterologous tympanoplasty. Trans Am Acad Ophthalmol Otolaryngol 77: 111-116, 1973

8. Perkins R: Formaldehyde formed autogenous fascia graft tympanoplasty. Presented at the Academy of Ophthalmology and Otolaryngology, Dallas, Texas, Oct. 9, 1974. To be published.

9. Hough JV: Tympanoplasty. Trans Am Acad Ophthalmol Otolaryngol. CETV-OTO, OTO-3, Vol. 1

10. Perkins R: Otologic homograft indications, techniques, and anatomic and functional results. Trans Am Acad Ophthalmol and Otolaryngol 80: 41-46, 1975

OTOLOGY AND INDUSTRIAL HEARING CONSERVATION

JOSEPH SATALOFF, M.D.

PHILADELPHIA, PENNSYLVANIA

SUMMARY – The Occupational Safety and Health Act is establishing limits for industrial noise exposure The Act may also require physicians to evaluate audiograms and examine almost two million employees annually. Otolaryngologists must take special training and become certified to provide American industry with expertise in industrial hearing conservation.

The Federal Government showed its serious concern for hearing loss by including noise exposure regulations in the Occupational Safety and Health Act (OSHA) of 1971. This law specified 90 dBA as the maximum noise level to which any employee should be exposed for eight hours daily over a period of years. The Department of Labor held inspections to insure industry's compliance with these regulations, but the regulations were too vague. In 1973 the Secretary of Labor instituted a new and appealing approach to writing standards by appointing a fifteen-man committee representing labor, management, government, and science to develop a noise proposal within nine months. The author was a scientific representative on this committee and believes it functioned extraordinarily well and produced an excellent and practical noise standard.

Certain features contained in the proposed noise standard are notable: 1) Certification of occupational hearing conservationists was recognized and defined; 2) No worker should be exposed to noise in excess of the limits shown in Table I; 3) Noise exposures exceeding 90 dBA as specified in Table I should be controlled by feasible engineering methods or administrative controls. If these controls were not immediately feasible, personal hearing protection equipment should be used; 4) All plants should have noise measurements at least annually; 5) Hearing conservation programs should be under the surveillance of a licensed physician; 6) Employees who either use ear protectors or are time exposed to over 85 dBA, Table 1,

TABLE I

SOUND LEVEL/DURATION LIMITS TO WHICH INDUSTRIAL WORKERS MAY BE EXPOSED*

Sound Level (dBA)	*Time Permitted (hrs.-mins.)*	*Sound Level (dBA)*	*Time Permitted (hrs.-mins.)*
85	16- 0	101	1-44
86	13-56	102	1-31
87	12- 8	103	1-19
88	10-34	104	1- 9
89	9-11	105	1- 0
90	8- 0	106	0-52
91	6-58	107	0-46
92	6- 4	108	0-40
93	5-17	109	0-34
94	4-36	110	0-30
95	4- 0	111	0-26
96	3.29	112	0-23
97	3. 2	113	0-20
98	2-50	114	0-17
99	2-15	115	0-15
100	2- 0		

* As suggested in the proposed noise standard by the Department of Labor's Committee to propose a noise standard for the Occupational Safety and Health Act.

should be part of a hearing conservation program that includes annual audiograms. Rules for calibrating all equipment and record keeping were included, and the technique for audiometry was detailed; 7) If the hearing thresholds for any employee showed a change averaging over 10 dB at 2, 3, and 4 kHz in either ear, the employee should be tested within a prescribed period and if the hearing change persisted, the employee should be referred for medical evaluation; and 8) Employees should be notified of their noise exposure and audiometric levels.

Even though all federal standards are based chiefly on the best available scientific information, other influential factors come into play, such as economics, practicability, and even vested interests. It is only natural, therefore, that the proposed noise standard was not accepted unanimously, and certain aspects of the proposal are being challenged. Most notable is that the 90 dBA level should be lowered to 85 dBA or even lower and that the requirement for medical surveillance and referral for medical evaluation should be deleted. The latter issue is of special interest to otologists since the challenge is based on the premise that too few otolaryngologists and other physicians are available with training and experience in industrial hearing conservation and occupational deafness to supply American industry with needed services. It has been estimated that about two million employees might require hearing evaluations annually on the basis of the OSHA medical surveillance requirement, proposed by a representative of Labor and passed unanimously by the Committee. The Committee felt that hearing loss was a medical responsibility and that a trained physician should have the chief responsibility for interpreting audiograms, making a diagnosis, and recommending treatment for patients with hearing problems.

Whether or not OSHA includes medical surveillance in its forthcoming noise regulation, it is essential that otolaryngologists acquire training and expertise to serve industry meaningfully and to help millions of employees with hearing difficulty. More and more, otologists are assuming essential roles in the development of effective hearing conservation programs and are called on to advise management and government in the many important aspects of such programs. The highly specialized problems attending occupational hearing loss and hearing conservation have focused attention upon the need for otologists to acquire training and experience in this field. First, we must become certified hearing conservationists and teachers by taking at least the 20-hour course required by the Council for Accreditation in Hearing Conservation. More desirable, however, is to acquire practical experience by taking more extensive training courses such as the one-week course provided each August for the past 22 years at Colby College in Waterville, Maine. Other courses are available and recommended, but their success depends on the industrial experience of their faculties. The best training courses include lectures on noise measurement, instrument calibration, industrial hearing testing, record keeping, ear protection, motivational programs, noise control, differential diagnosis of hearing loss, workmen's compensation for hearing loss, legislation, and labor relations and management problems.

American otology must also institute training programs in hearing conservation for all our residents, and competence in this field should be required by the American Board of Otolaryngology. We must also make certification courses readily available to practitioners throughout the country.

Otologists have special and unique responsibilities to industrial hearing conservation programs. The otologist must sometimes even coordinate the program and provide a broad understanding that transcends hearing testing or noise measurement.

A proper hearing conservation program requires team work of safety engineers, hygienists, audiologists, hearing

conservation technicians, industrial physicians, nurses, and a trained otologist. Among the otologist's singular functions are to interpret hearing tests, to diagnose, and to determine treatment and dispensation. He must also provide medicolegal advice and testify in compensation and legislative proceedings.

Above all, our responsibility is to prevent deafness in all employees and to detect, diagnose, and recommend treatment for all causes of hearing loss. Only with such a broad concept can the objective of our Congress be achieved: to maintain the health of industrial employees.

I am convinced that American otology will meet this challenge so that we may supply the needs of our country and pass on to our successors a specialty broad in horizon, imaginative, and of greater service to our people.

Request for reprints should be sent to Joseph Sataloff, M.D., 1721 Pine Street, Philadelphia, Pa. 19103.

COMPLICATIONS IN ACOUSTIC NEUROMA SURGERY

MICHAEL E. GLASSCOCK III, M.D.

JAMES W. HAYS, M.D. JAMES P. MURPHY, M.D.

NASHVILLE, TENNESSEE

SUMMARY – The findings in a series of 80 cerebellopontine angle tumors are presented. Complications and results are covered in detail. A new method of controlling postoperative cerebrospinal fluid (CSF) leak is presented. Care of the eye in postoperative facial paralysis is emphasized, and a new type of moisture chamber is introduced.

Acoustic tumors remain a challenge to the otologist both in diagnosis and surgical removal. While the overall morbidity and mortality have been lowered, these tumors are still difficult and dangerous to remove. The complications that occur can be debilitating and, in some instances, fatal. It is important to recognize the more common ones, to know why they occur, and how to prevent them. The purpose of this paper is to review findings in a series of 80 cases and to discuss in detail the results in relation to complications.

DIAGNOSIS AND SURGICAL REMOVAL OF ACOUSTIC TUMORS

When this type of surgery was first attempted, the operative death rate was approximately 80 to 90%.[1] Cushing[2] was able to lower this rate to about 20% by advocating subtotal removals. There were several reasons for this high mortality rate, such as poor operating room conditions, poor general anesthesia, and lack of blood replacement. The chief cause of difficulty, however, was the large size of the tumor at the time of surgery. Most patients were not suspected of having a tumor until they were moribund. This can be attributed only to lack of diagnostic ability. One of Cushing's greatest contributions was his recognition of the natural history of these tumors.[2] He was the first to realize that tinnitus and hearing loss were among the first symptoms of a patient with an acoustic neuroma.

Dandy[3] was able to obtain total removals with an acceptable mortality rate because of better diagnostic tools and improved operating room conditions. The tumors that Dandy removed were, by and large, smaller and detected earlier than those with which Cushing had been left to deal.

Years later, House[4] was able to lower the morbidity and mortality dramatically because of earlier detection. He was able to take advantage of a wide variety of new and sophisticated audiometric and radiological advancements. Dealing largely with much smaller tumors and improved surgical techniques (translabyrinthine and microsurgical), he was able to lower the overall mortality rate to 10%.

While it would be ideal to find these tumors when they are limited to the internal auditory canal (IAC), this is not always possible. Many times the tumors simply do not produce enough symptoms to alert even the most suspicious physician. Until some type of screening test is developed, it would appear that we must continue to deal with medium and large tumors for some years to come.

The key to early detection is a physician with a high index of suspicion who is willing to perform a thorough neurotologic evaluation on all patients with unilateral tinnitus, unilateral sensorineural hearing loss, or any form of spatial disorientation. This evaluation should include: a head and neck examination; screening neurological, audiometric, and vestibular studies; and x-rays of the temporal bone. Should the results of these tests be suspicious, then a posterior fossa contrast study should

be performed. The Pantopaque®* examination is highly accurate and will usually indicate the size of the tumor.

There are several operative procedures that are employed at the present time. A certain amount of controversy still remains concerning the best method for the surgical removal of these tumors. At the present time they are being removed through the classical suboccipital route with and without microsurgical technique. House[4] and his disciples[5] continue to advocate the middle fossa approach for small tumors (limited to the IAC), the translabyrinthine for medium, and the transsigmoid or combined procedure for large tumors.

The final test for any procedure or surgeon is the overall morbidity, mortality, and recurrence rate over a period of years. It is only with this experience that the best methods of diagnosis and management can be determined. Certainly, at this point in time, the results of House stand as a yardstick by which others may judge their progress.

To continue our advancement in this type of surgery, it is important for all surgeons to periodically review their cases and make formal reports as to their results and complications. This must be done in a standardized method for the information to be meaningful.

CASE SUMMARIES

In this review of a series of 80 cerebellopontine angle tumors,** there are 79 patients represented. One individual had bilateral acoustic neuromas. Two other patients had neurofibromatosis, but only one tumor has been removed at this time. There were 30 males and 49 females. with 15 large, 62 medium, and 3 small tumors. Seventy-four were acoustic neuromas, four were meningiomas, one was an hemangioma. and one was a ganglioneurolipoma. There were three combined translabyrinthine-suboccipital, one transsigmoid, and three middle fossa procedures performed. The remaining 73 tumors were removed through the translabyrinthine approach.

A tumor confined to the IAC (usually 0.5 to 0.7 cm) is considered small, while one extending out into the cerebellopontine angle is thought of as medium or large. For classification purposes, a tumor is considered large if there are V nerve findings or evidence of increased intracranial pressure. Tumor size in centimeters has been recorded, based on preoperative Pantopaque® studies and observation at the time of removal. Several tumors of 3 to 4 cm have been listed as medium in size because there were no V nerve findings or evidence of increased intracranial pressure. Conversely, some 2.5 cm tumors are listed as large because they did produce V nerve symptoms.

Facial nerve function has been recorded as percentage of loss. Those patients having completely normal function are reported as 0% loss, and those with no function as 100% loss. Any sign of synkinesis is represented as a 10% loss. A 25 to 50% loss signifies some facial weakness although the patient may be able to close the eye, and the face looks normal at rest.

RESULTS

As this paper is concerned primarily with complications of acoustic neuroma surgery, the results of this series will be reviewed in detail. The aim of this study is to better understand how to prevent complications and how to manage them when they do arise. Experience with these 80 cases has led the authors to change certain aspects of their surgical technique. In addition, it has become necessary to develop new methods of dealing with the sequelae of some of these complications.

FATALITIES

Operative deaths will occur in cases of all tumor sizes from time to time. The surgeon's duty is to obtain a total removal with as little damage to the brain stem and its blood supply as possible. While fatalities are usually associated with injury to the anterior

* C. G. Armour Medical Corp., Baltimore, Md.

** Detailed tabulation of all 80 cases prepared according to guidelines established by W. F. House, M.D.[4] are available on request to senior author.

cerebellar artery, they can also occur from cerebral edema, meningitis, or a host of other causes in the immediate postoperative period. In this particular series, there have been no fatalities.

The posterior fossa is a treacherous area of the intracranial cavity for tumor removal. The main reason for this is that the brain stem represents the most primitive portion of the brain and is concerned with the most vital functions of respiration and heart rate. Medium and large tumors usually contact the stem and must be carefully dissected away from it during the removal. At this point in the procedure, the respiratory rate may drop. Even in smaller tumors, the anterior-inferior cerebellar artery may be adherent to the tumor, making its removal extremely difficult. Atkinson has shown that most operative fatalities are associated with injury to this artery.[6] Even if this vessel is not severed in tumor removal, it can still go into spasm and occlude. It is extremely important to avoid contact with this vessel if at all possible. One of the great advantages of the translabyrinthine approach is that the tumor capsule is between the surgeon and this artery throughout the greater part of the procedure. This is in direct contrast to the situation one encounters in the suboccipital approach, where one often finds himself operating past the anterior-inferior cerebellar artery in order to remove tumor.

In order to prevent operative fatalities, microsurgical technique is imperative. Careful dissection of the tumor capsule and bipolar cauterization of all the small blood vessels entering the tumor prevent operative and postoperative hemorrhage.

Bleeding must be kept under control at all times, and there should be no indiscriminate manipulation of the capsule. It must be remembered that these are brain tumors and that the tumor frequently has its blood supply in common with the brain stem. While most fatalities are associated with large tumors, it is certainly possible to injure the anterior-inferior cerebellar artery in removing a medium-sized tumor. In fact, if one were removing a small tumor through the middle fossa, it would still be possible to injure the artery as it frequently loops into the internal auditory canal.

TOTAL VERSUS SUBTOTAL REMOVAL

All tumor removals in this series have been total. We would not hesitate, however, to leave a small piece of capsule attached to the brain stem in order to get the patient off the operating table alive.

Should the tumor recur, House[4] has shown that secondary removal through the translabyrinthine route is less hazardous than through the suboccipital. There is some question as to whether small pieces of capsule survive and cause tumor regrowth.

For standardization when reporting results, it would seem best to simply refer to the removal as being either total or subtotal. The tumor is either totally removed or it is not, and stating whether there was a radical subtotal or partial subtotal is merely confusing and serves no real purpose. In discussing results, a subtotal removal should be considered a complication.

CEREBROSPINAL FLUID LEAK

Cerebrospinal fluid (CSF) leak has been the most frustrating and consistent complication in this series of patients (11%). In the first few cases, temporalis muscle was used in the middle ear and mastoid cavity to prevent a leak. The muscle was sutured into position by using 3-0 silk in the dura. In many women the muscle was very small, and it was difficult to obtain enough bulk to seal the dural defect. Many individuals developed seromas at the donor site due to weeping of the muscle where bleeders had been cauterized, which led the authors to the use of adipose tissue obtained from the abdominal wall. This latter procedure seemed to work well in that the temporalis muscle was left in place and could be used to obtain a water-tight closure of the subcutaneous tissue and did away with the seromas and fluid accumulations under the postauricular skin. Occasionally a

patient would develop a postoperative leak, and it would be traced to the middle ear. The adipose tissue did not lend itself to packing in the middle ear. At this point, sternocleidomastoid muscle was obtained for the middle ear, and adipose tissue was used in the mastoid cavity. Leaks still persisted from time to time, leading to the present method of management.

Routine Surgical Technique. Temporalis fascia is taken and put aside to be used later in the closure. After the simple mastoidectomy has been performed, the facial recess is opened, and the incudostapedial joint is separated. The incus is removed and placed in the homograft bank. The head of the malleus is amputated and placed deep into the Eustachian tube. Muscle is cut into small pledgets and inserted into the Eustachian tube behind the head of the malleus. The entire middle ear is then filled with muscle. Special care is taken not to dislodge the stapes from the oval window as this has been a common site for CSF leakage into the middle ear.

Since this method of packing the middle ear and mastoid has been employed, there has been only one leak down the Eustachian tube. There have been nine such CSF leaks requiring a formal closure. This accounts for an overall incidence of 11% for the entire series. Five patients have developed postauricular leaks through the wound that healed spontaneously.

There have been three patients in this series who have had persistent CSF leaks that simply could not be controlled with the usual methods. All had at least one attempt at closure of the leak using all of the methods just described. Finally, in desperation, a totally different approach was conceived to solve the problem.

CASE REPORT

A 42-year-old male underwent the removal of a 4 cm acoustic neuroma in July 1973. The tumor was totally removed and the facial nerve was preserved. He had an uneventful postoperative recovery and was discharged from the hospital one week after surgery. He continued to do well for approximately three weeks. While bending over one day, he noticed a clear drainage from the left nostril. He was readmitted to the hospital, and the wound was explored. The stapes was found to be subluxated, and CSF was flowing freely from the oval window. After the ossicle was removed, the vestibule and Eustachian tube were packed with muscle. Again he had an uneventful postoperative period and did well. Three weeks later he developed another leak. This time it was decided to let the leak remain for awhile to see if it would close on its own. After one month the wound was again examined. CSF was again flowing freely from the oval window. More muscle was placed into the vestibule area, middle ear, and mastoid cavity. The postauricular skin did not look good after so much surgery. Nylon sutures were used to close the wound. The patient did well and went back to work. Almost three weeks later, he started spiking a temperature elevation of 39.4C and he was disoriented. A spinal tap confirmed the diagnosis of bacterial meningitis. With the proper antiobiotic coverage his infection came under control, and his ear was again explored. The leak was still coming through the oval window. Again the ear was filled with muscle. He had an uneventful recovery and went back to work. There was no obvious CSF leak, but he did complain of a salty taste. About two months after the episode of meningitis, he suddenly developed ataxia and could not sit or stand in an upright position. An x-ray skull series revealed air in the ventricles and there was evidence of hydrocephalus. There was definitely a leak, and he was producing excessive amounts of CSF. A ventricular-peritoneal shunt was performed and the hydrocephalus came under control. The CSF leak continued. It was obvious that something drastic needed to be done to control his fistula. A middle fossa Eustachian tube closure was performed, and finally we were able to stop the leak. Once it was controlled, he did well. The last surgery was over a year ago. He has had no

Fig. 1. A routine middle fossa exposure of the temporal bone is accomplished using a House-Urban middle fossa retractor. The surgeon is seated at the head of the table with the patient lying supine with his head turned to one side.

further signs of a fistula, and he is back to his regular activities.

MIDDLE FOSSA EUSTACHIAN TUBE CLOSURE

A routine middle fossa exposure (Fig. 1) of the Eustachian tube is accomplished. Once the geniculate ganglion is identified, the bone lying lateral to the ganglion (tegmen tympani) is removed, exposing the middle ear from above. The tensor tympani muscle is followed to the Eustachian tube, and the superior aspect of the osseous tube is removed down to the isthmus (Fig. 2). Next the tensor tympani muscle is stripped from the semicanal, and a small wedge of cortical bone is fashioned so that it fits snugly into the isthmus of the tube. All of the mucosa from the medial wall of the middle ear has usually been removed at the first surgery. Should there be any remaining, it is removed at this time. The scrub nurse now mixes a portion of orthopedic bone glue* and places it in a disposable syringe with a 15 gauge blunt needle. The glue is placed into the Eustachian tube and anterior portion of the middle ear (Fig. 3). Care must be taken to keep the operating field dry so that the glue will become adherent. The chemical reaction that

Fig. 2. The tensor tympani muscle is followed to the Eustachian tube, and the superior aspect of the osseous tube is removed down to the isthmus.

Fig. 3. The orthopedic glue is placed into the Eustachian tube and anterior portion of the middle ear.

occurs while the glue is solidifying creates an excessive amount of heat. It is important to keep the glue away from the facial nerve during the period of hardening. The carotid artery is in almost direct contact with the glue, but the rapid flow of a large amount of blood quickly dissipates the heat.

The field is kept dry until the glue has solidified and attached itself to the bone of the middle ear and Eustachian tube. The middle fossa retractor is removed, and the temporal lobe is allowed to expand. The wound is closed in layers, and a bulky dressing is applied. The patient is observed in the recovery room overnight where routine craniotomy checks are performed.

PRESERVATION OF THE FACIAL NERVE

We have been able to preserve the facial nerve anatomically in 68 of the 80 cases in this series, representing a success rate of 85%. Two of these nerves, however, failed to regain any function at one year after surgery dropping the percentage to 82.5% for preservation with function. Fifty-one tumors were removed with no loss of function.

For years the sacrifice of the facial nerve was routine in the removal of these tumors. The lesion was lethal, and without microsurgical techniques there was little chance of saving the nerve. House[4] and his development of the translabyrinthine route to the cerebellopontine angle made preservation of the VII nerve a very real and practical goal. While advocates of the microsurgical suboccipital approach are able to preserve the facial nerve, there is no constant bony landmark for its identification, and no one has reported as high an incidence of preservation as has House.[4]

While it is usually easier to preserve the nerve in patients with smaller tumors, size alone is not the most important factor. Often the nerve will dissect from a large tumor quite easily while it is sometimes very adherent to a medium-sized one. In removing the tumor, it is important to take the tumor away from the nerve and not to push or pull too vigorously on the nerve itself. In dealing with the larger tumors, it is important to reduce the size of the tumor until it is about 1 cm in diameter. It is important to have it free of all attachments and completely mobile before the facial nerve is identified at the lateral extent of the IAC at Bill's bar. In this manner, as the tumor is being dissected free from the nerve, it is possible to rotate the tumor and deflect it inferiorly, usually allowing the surgeon to trace the nerve along the side of the tumor, making the line of cleavage much easier to determine.

Occasionally the VII nerve is simply too adherent to the capsule to obtain a separation of the tumor from the nerve. In such a case, regardless of the size of the tumor, the nerve must be sacrificed in order to obtain a total removal. When this occurs, the surgeon must make the decision to attempt a graft of the facial nerve or to perform some type of anastomosis. Of the 12 nerves that were lost at surgery, seven have been repaired by means of a facial hypoglossal anastomosis. These individuals are considered to have 50% function of their faces.

Nerve Grafts. We have not been able to graft any of the patients in whom the nerve has been severed. Dott[7] reports grafting from the brain stem, but we have seldom been able to find a proximal stump. In attempting a graft, one is committing the patient to a one-year wait to see if there is to be a take. Under most circumstances we have favored a facial hypoglossal anastomosis.

---

* Simplex®, Howmedica Inc., Rutherford, N.J.

Fig. 4. Note that this patient, who had her facial hypoglossal anastomosis approximately five months before this picture was made, has good tone to her face at rest.

Fig. 5. Voluntary control of the face is relatively good with minimal facial movement. The patient has extremely good control of her eye.

Facial-Hypoglossal Anastomosis. While the facial nerve can be anastomosed with the phrenic or spinal accessory nerves, we have preferred the hypoglossal due to its close proximity to the nucleus of the VII nerve in the brain stem. The loss of function of the involved side of the tongue causes the individuals virtually no difficulty with eating or speech. We feel that it is important to perform this anastomosis early while the facial muscles still have good tone. In the seven cases that have undergone anastomosis, the results have been very gratifying. Figure 4 shows an anastomosis approximately five months postsurgery. At rest, her face appears perfectly normal. When she smiles (Fig. 5), there obviously is a weakness in her face, but this will improve with time. It is important to obtain a good microscopic anastomosis of the two nerves. We use at least four and preferably six to eight sutures in the sheath to obtain good union (Fig. 6).

Care of the Eye. Care of the eye following injury to the facial nerve is extremely important. One of the most valuable methods was suggested to us by a patient. This individual was having difficulty with his eye at night. He obtained some clear plastic food wrap and cut a small square to fit over the eye. He taped this into place with a commercial hair set tape (Fig. 7). This created a moisture chamber for the eye and also kept foreign objects, such as the bed sheets out of the eye. The hair

Fig. 6. Microscopic anastomosis should be carried out with four to six well-placed sutures in the sheath of each nerve.

set tape is nonirritating to the skin and peels off easily without pain. We have used this method in a wide variety of cases of facial paralysis now with great success. Patients prefer this method to direct closure of the eye with cellophane or adhesive tape.

When there has been permanent injury to the facial nerve and the recovery period may be several months, a tarsorrhaphy is considered. Whether or not one is done depends upon the difficulty the patient experiences with his eye. We have found with the plastic moisture chamber at night and artificial tears during the day, tarsorrhaphies are not needed as often as they were.

MENINGITIS

The most serious complication in this series of patients has been bacterial meningitis (ten cases). This represents an overall incidence of 12.5%. Interestingly, the severe cases have all occurred several weeks after surgery and have been directly related to a postoperative CSF leak. There has been only one immediate onset, and it was associated with a postauricular leak that

Fig. 7. This square of plastic, when placed over the eye and held in place with the hair set tape, forms a moisture chamber that affords excellent protection. It has the advantage of allowing the patient to keep his eye open and see through the covering.

occurred about three days after surgery. There has been no common organism and none that was resistant to antibiotics.

There have been three individuals who developed a low grade chemical meningitis as a reaction to blood in the spinal fluid representing an incidence of 3.5%. These patients experienced some temperature elevation in the range of 37.8-38.3C, headache, and a stiff neck. Spinal fluid taps performed on these individuals revealed a normal sugar level and a cell count of 100 or less. They grew no organisms on culture, and all recovered without antibiotic coverage within three to ten days.

It has been our policy not to use prophylactic antibiotic coverage during the postoperative period. A true bacterial meningitis requires large amounts of potent antibiotics to bring the infection under control. The only way to predict the correct antibiotic is with culture and sensitivity studies. Should the patient be on too small a dosage of a marginally effective prophylactic drug, it will be impossible in many instances to grow a positive culture, making it extremely difficult to treat the infection successfully.

The patient with a bacterial meningitis is easily recognized. His temperature will frequently spike to 38.9-39.4C. He will be confused and disoriented and will very frequently complain of a stiff neck and severe headache. A lumbar spinal puncture must be performed immediately. If the cell count is elevated and the sugar level is low, a true bacterial meningitis should be suspected. It is a good idea to obtain a gram stain as a stat procedure as well. Broad spectrum antibiotics in high doses and in combination should be instituted intravenously until the culture and sensitivity studies are available. Our drugs of choice are penicillin, chloramphenicol, and methicillin. Should the patient be allergic to penicillin, cephalexin monohydrate is substituted. Once the organism is isolated and the sensitivity known, the patient is left on the specific antibiotic, and the others are discontinued.

It has been our feeling that if the postoperative leaks could be kept to a minimum, the number of bacterial meningitis cases could be lowered as well. The length of the operative procedure, when prolonged, is probably another factor in this problem. When a wound is open for several hours, the possibility of contamination is greater.

POSTOPERATIVE INTRACRANIAL HEMORRHAGE

There were no postoperative hemorrhages occurring in this series. The first 24 hours after surgery are the most critical ones in regard to immediate postoperative hemorrhage. The recovery room in our hospital is adjacent to the operating suite. A set of instruments is kept sterile and ready to use at a moment's notice, and a tracheotomy tray is available at all times. A mechanical respirator is kept in reserve in the recovery room.

Routine craniotomy checks are performed every five minutes until the patient is stable and then every 30 minutes for the first 12 hours. Should evidence of increased intracranial pressure occur, the surgeons are notified immediately, and the patient is returned to

surgery on an emergency basis to remove a clot from the cerebellopontine angle.

Careful attention to technique and to control of bleeding during surgery will eliminate the problem of postoperative hemorrhage in most cases. The bipolar cautery has been of tremendous value in controlling hemorrhage at the time of surgery. Extreme care must be taken with each blood vessel that enters the tumor capsule. There will be postoperative bleeds, however, regardless of how dry the field is at the end of the procedure. The important fact that must be kept in mind is that the surgeon must be prepared to act decisively and quickly to remove the clot and stop the bleeding. One of the great advantages of the translabyrinthine approach is that this can be done with dispatch in the recovery room if necessary.

POSTOPERATIVE EDEMA

We have had to take only one patient out of 80 back to surgery in the immediate postoperative period. This patient did not respond the morning after surgery. Upon reexposing the operative site, the cerebellum was obviously infarcted and very edematous. His had been a large acoustic tumor, and a self-retaining retractor had been placed on the cerebellum for several hours. The infarcted tissue was removed. The patient recovered and has done well with the exception of some mild ataxia.

Retraction of the cerebellum is the most common cause of postoperative edema. If it is necessary to retract the cerebellum exclusively for exposure, it is better to remove the lateral third of the hemisphere. Another of the advantages of the translabyrinthine approach is that in most cases no retraction of the cerebellum is required for an adequate view of the cerebellopontine angle. It is not necessary to remove the lateral third to gain access with this approach.

One patient had edema of the temporal lobe due to retraction during a prolonged middle fossa procedure. Part of the temporal lobe was removed at the initial surgery, and she did have a postoperative edema. She was placed on dexamethasone MSD for this and made an uneventful recovery.

We have tended to use urea, mannitol, and dexamethasone MSD sparingly due to the rebound phenomenon and bleeding that can sometimes occur with these agents.

MEDICAL PROBLEMS

One patient developed severe pneumonia postoperatively due to a contaminated endotracheal tube. Two other patients had pneumonia, but the cause was not determined. One older patient developed a pleural effusion due to congestive heart failure and melena due to a stress ulcer. Another patient became confused and lethargic about six days after surgery and was found to be suffering from hyponatremia. She responded immediately to intravenous 3% normal saline. Two patients have required tracheotomies because they developed aspiration difficulties due to loss of the X nerve at surgery.

There have been two frank wound infections (2.5% incidence), and these cleared with antibiotic coverage.

We have developed a therapeutic team as well as a diagnostic one for dealing with these patients. An internist sees all of these individuals and follows them with us carefully after surgery.

CONCLUSIONS

These cerebellopontine tumors are treacherous to remove, and operative deaths are going to occur from time to time. While aggressive in tumor removal, we are nonetheless very meticulous and careful in surgical technique. Every attempt is made to control bleeding as the dissection is carried out and the brain stem is handled with great care. The patient is allowed to breathe on his own while the capsule is being removed from the stem. Should the respirations cease, the dissection is stopped until spontaneous respirations occur. This is very tedious and may require several hours of determined effort. Large blood vessels that do not enter the capsule are gently packed away

from the tumor with cottonoids, thereby lessening the chance of inadvertent injury.

We have been very fortunate in having superb anesthesia for our patients. Almost without exception, all of them have been responsive and awake at the end of the procedure. The fact that we have only had to take one patient back to surgery in the immediate postoperative period speaks well for anesthesia and the control of hemorrhage and cerebral edema at the time of surgery.

The aggressiveness with which total removals have been sought may account for our lack of facial nerve preservation. While the facial nerve was anatomically preserved in 85% of the cases, it remained functional only 82.5% of the time, a 10% drop since our last report[5] and of great concern to us. We would like to have a better record with facial nerve preservation. While the nerve was simply impossible to save in most cases, there were a few in which it was lost due to technical error. This type of loss can be corrected, and, hopefully, as the series grows, we will be able to improve this aspect.

Eleven (13.7%) of our patients have had serviceable preoperative hearing in the involved ear. Hearing in the opposite ear in all of these individuals (except the bilateral cases) has been good, and we have attempted to save the hearing in the involved ear only three times. All of these were done as middle fossa procedures, and only once were we able to save the hearing. In one case the tumor was too large, and in the other it was adherent to the cochlear nerve.

While interested in preservation of hearing, we are more concerned with total removals, preservation of the facial nerve, and a low mortality rate. At the present time, we feel these goals can best be accomplished through the translabyrinthine approach. We will continue to attempt to preserve the hearing when the tumor is confined to the IAC. In bilateral tumors when there is some hearing present, an attempt will be made to save the labyrinth by means of a combined middle fossa-transsigmoid procedure. We do not feel the suboccipital approach, *per se*, affords good landmarks for the preservation of the facial nerve or furnishes a good route to the cerebellopontine angle and brain stem.

The most bothersome and dangerous complication in this series has been CSF leak with subsequent bacterial meningitis. With improvement in the initial closure, this seems to be coming under control and if it can be kept to a minimum, we feel that the problem of meningitis will also subside.

The best method of lowering morbidity and mortality is to detect these tumors early in their development. Fewer complications occur, and the best results are obtained with small and medium-sized tumors.

Request for reprints should be sent to Michael E. Glasscock, III, M.D., 300 25th Avenue, North, Nashville, Tennessee 37203.

REFERENCES

1. Krause F: Zur Freilegung der hinteren Felsenbeinflache und des Kleinhirns. Beitr Klin Chir 37:728-764, 1903

2. Cushing H: *Tumors of the Nervus Acusticus and the Syndrome of the Cerebellopontine Angle*, ed 2. New York, Hafner Publishing Co, 1963

3. Dandy WE: Operation for total removal of cerebellopontine (acoustic) tumors. Surg Gynecol Obstet 41:129-148, 1925

4. House WF, ed: Monograph II: acoustic neuroma, Arch Otolaryngol 88:575-715, 1968

5. Glasscock ME, Hays JW: The translabyrinthine removal of acoustic and other cerebellopontine angle tumors. Ann Otol Rhinol Laryngol 82:415-427, 1973

6. Atkinson WJ: The anterior inferior cerebellar artery. J Neurol Neurosurg Psychiatry 12:137-151, 1949

7. Dott NM: Facial nerve reconstruction by graft by-passing the petrous bone. Arch Otolaryngol 78:426-428, 1963

ELECTRONYSTAGMOGRAPHY: A REVIEW OF 17 YEARS EXPERIENCE

WALLACE RUBIN, M.D.

METAIRIE, LOUISIANA

SUMMARY – The clinical concepts of electronystagmography (ENG) and vestibular testing are simple. They are not mysterious, complicated, nor time consuming. Every patient afflicted with dizziness deserves such a recording as part of the vestibular workup. No one would consider the evaluation of a patient with a hearing loss complete without an audiogram, and in 1975 no patient with a complaint of dysequilibrium has been properly or sufficiently evaluated without an ENG recording of balance function.

The physician must be the captain of the vestibular diagnostic team based on his interest, knowledge, and capability. It is not the electronystagmograph (ENG) instrument used nor the routine battery of vestibular tests with numerical evaluations that provide diagnostic answers. It is the intelligent application and use of the indicated vestibular tests that are practically correlated and clinically evaluated that will give the knowledgeable physician significant information. This can best be accomplished when ENG testing is done in physical proximity to the responsible physician and when the tests used are intelligently ordered and evaluated. Under such circumstances ENG is always helpful and timesaving because the recordings can then assist in answering these clinical questions: 1) Is the vestibular mechanism normal or abnormal? 2) Is the vestibular pathology peripheral or central? and 3) Is the peripheral disease right or left sided?

The data on the recording additionally may be helpful in providing central nervous system (CNS) localizing information based on the ocular tracking tests.

All balance function tests performed (whether with or without electronystagmography) must fall within one of four categories. They must be tests either for: 1) spontaneous nystagmus, 2) positional or positioning nystagmus, 3) induced nystagmus, or 4) nystagmus as a result of tracking moving visual targets.

Spontaneous nystagmus tests are those performed prior to exposing the patient to any stimuli. In these tests the patient may either be seated, lie on an examining table, or stand. Positional or positioning tests are those where the patient has only his head or his head and body moved into certain positions. Tests for induced nystagmus are performed by either rotating the patient as in any of the many rotational tests, irrigating the ear canals with water above and/or below body temperature, or tests wherein a galvanic stimulus is used to induce the nystagmus.

The spontaneous, positional, and induced tests are all related specifically to vestibular function. Any ocular tracking tests such as the gaze test, the optokinetic tests, the pendulum or sawtooth tracking test, or any other ocular tracking tests are tests of ocular function and the results may or may not relate to vestibular abnormalities.

Nystagmus always accompanies ver-

tigo. It is the one consistent useful objective sign we have available to confirm vestibular abnormalities. Nystagmus which occurs in vestibular disease is best elicited and sometimes only visible when ocular fixation is suppressed or abolished. The only method that allows the physician always to detect the presence of nystagmus is observation of the patient when the patient's eyes are open in a darkened room or when the eyes are closed in a lighted room. There is no better way to accomplish this visualization than with an ENG recorder. Any other method of nystagmus detection (i.e., naked eye or Frenzel's lenses) will miss the majority of nystagmus and will, in addition, not permit accurate evaluation of its characteristics.

ENG rapidly supplies useful differential clinical information when the technique is intelligently combined with a bithermal caloric test and when these responses are interpreted and correlated with the total diagnostic workup. This premise is based on the fact that nystagmus is an algebraically summative phenomenon. When spontaneous nystagmus is present, the ability of an induced thermic nystagmus to inhibit or suppress it and then turn it in the proper physiologic direction is always a better measure of vestibular integrity than the thermic stimulus which would facilitate the spontaneous nystagmus in the same direction. It is this principle that allows for eyeball interpretation of ENG caloric responses and makes it possible to shorten the testing procedure.

Interpreting the caloric responses on an ENG when there is a spontaneous nystagmus present requires primarily a comparison of only two responses. The fundamental question is whether the response to the two stimulations which beat opposite to the spontaneous nystagmus are symmetrical. When the peripheral labyrinth functions in a normal fashion, the spontaneous nystagmus must be slowed, stopped, reversed, and then sustained in the opposite direction. If, for example, there is a right beating spontaneous nystagmus, the two stimulations which should beat left must be compared (R30° and L44°). If there is a left beating spontaneous nystagmus, we must compare L30° and R44°. The results possible with caloric stimulation in the presence of a spontaneous nystagmus are: 1) There will be no change at all of the spontaneous nystagmus with either opposing stimulation; 2) There will be a similar, equal, or symmetrical change with both stimulations; 3) Only one stimulus will slow, stop, or reverse the spontaneous nystagmus or sustain the nystagmus in the opposite direction; and 4) One stimulus will more effectively slow, stop, or reverse the spontaneous nystagmus or will sustain the nystagmus in the opposite direction.

Items 1) and 2) above can occur only with intact peripheral function, while items 3) and 4) indicate pathology of the peripheral labyrinth. The labyrinth least capable of slowing, stopping, or reversing the spontaneous nystagmus or sustaining the induced nystagmus in the opposite direction must be the diseased labyrinth.

When such a testing routine is used and when these concepts are applied, no numbers or formulas are necessary to interpret the ENG. It is also unnecessary to get involved in the problem of adding and/or subtracting the spontaneous nystagmus or to get involved in the directional preponderance controversy. The vestibular end organ algebraically summates the already present and stimulated nystagmic activity and makes these problems moot.

If the caloric responses are recorded from the time of instillation of the irrigating tip and the response is recorded till its completion, then an eyeball comparison of the responses can be made easily and accurately. The correlation of these responses with the spontaneous and positional nystagmus, gaze, and optokinetic (OPK) tests makes it possible to decide normal or abnormal, peripheral or central, right or left peripheral, and possibly to determine CNS localization. This decision can be done easily, quickly, without numbers, without formulas, with less errors, and

without the likelihood of overreading an ENG.

Some persons maintain that the "old" method of calorization with ice water and naked eye evaluations of the induced nystagmus is just as accurate as evaluation with ENG. The fallacies of this kind of thinking are: 1) Spontaneous and/or positional nystagmus would have been missed the majority of the time (more than 95%) with naked eye observations. (This is due to ocular fixation suppression of nystagmus); 2) Nystagmus beats to the diseased ear about 35% of the time; therefore, 65% of the time a warm stimulus would give better information than a cool stimulus; 3) With either cold or warm stimulations and depending on the direction of the missed spontaneous nystagmus, the induced nystagmus would have been in a direction that might make the two stimulations look equal if two cool or two warm stimulations are used, and the naked eye is used for evaluation of nystagmus; and 4) In a small but significant number of cases, the observer would report a perverted nystagmus on thermic stimulation because the spontaneous nystagmus was never seen in the first place and the stimulation provoked or facilitated only the spontaneous nystagmus.

Even though ENG is an indispensible part of the vestibular testing procedure, the machine itself does not and cannot make a diagnosis. However, anyone can quickly learn to accurately read a recording. All ENG apparatuses have the same three basic components: 1) electrode pickup, 2) amplification capability, and 3) readout capability. A single channel unit is all that is necessary for the physician's office. Multichannel sophisticated instruments and equipment are useful in research situations but tend to add technical problems and might clutter the clinician's mind with clinically useless data.

There are persons who criticize ENG because they say that there is no standardization and that spurious spikes and pen movements interfere with readings. The fundamentals of recordings and procedure have been agreed upon and documented by the ENG Study Club as long ago as 1968. The differences of opinion regarding technique are nuances of difference that in no way can or should cloud the issue. Experienced neurotologists have no difficulty reading each other's ENG's. Problems arise only in the hands of those persons who are inexperienced and who overread recordings. These reading difficulties do not occur because of extraneous voltages which occur because of large muscle movements such as blinks, swallows, coughing, or body movements. They occur because of lack of understanding by technically untrained individuals. The interpretation of an ENG cannot be the function of the technician. Vestibular tests recorded by ENG must be supervised by a knowledgeable physician who will make the clinical interpretations and decisions.

CONCLUSIONS

The presence of spontaneous and/or positional nystagmus confirms abnormalities of the vestibular mechanism. The responses to the bithermal stimulation separate the peripheral from the central abnormalities and determine sidedness in peripheral problems. The ocular fixation and tracking tests may help in localizing the central abnormalities. Other special tests (not vestibular nor ENG) tell us about etiologic mechanisms.

The clinical concepts of ENG and vestibular testing are simple. They are not mysterious, complicated, nor time consuming. Every patient afflicted with dizziness deserves such a recording as part of the vestibular workup. No one would consider the evaluation of a patient with a hearing loss complete without an audiogram, and in 1975 no patient with a complaint of dysequilibrium has been properly or sufficiently evaluated without an ENG recording of balance function.

Request for reprints should be sent to Wallace Rubin, M.D., 3333 Kingman St., Metairie, Louisiana 70002.

SENSORINEURAL HEARING LOSS DUE TO COCHLEAR OTOSPONGIOSIS: THEORETICAL CONSIDERATIONS OF ETIOLOGY

FRED H. LINTHICUM, JR., M.D.
LOS ANGELES, CALIFORNIA

ROBERTO FILIPO, M.D.
ROME, ITALY

SIDNEY BRODY, P.E.
LOS ANGELES, CALIFORNIA

SUMMARY – Several theories have been advanced to explain the sensorineural hearing loss that occurs in patients with otospongiosis: toxic substances produced by the otospongiotic focus; vascular shunts between the inner ear vessels and the otospongiotic focus; and atrophy of the organ of Corti and stria vascularis due to unknown causes. Presented here is yet another theory: impingement upon the cochlear walls by the otospongiotic focus, causing a narrowing of the lumen of the cochlea and distortion of the basilar membrane.

There seems to be little question that cochlear otospongiosis can cause sensorineural hearing impairment. But what is the mechanism?

In this paper we will review the various theories and present the results of a study of 100 pairs of temporal bones from the Ear Research Institute collection. Narrowing of the lumen of the cochlea and distortion of the basilar membrane by the otospongiotic focus is another possible cause of sensorineural hearing impairment.

The patients were divided into three groups based upon their ages at the time of the first audiogram: 20 to 29, 30 to 39, 40 to 49. To prevent contamination of our results due to the loss from presbycusis, this loss as determined by Glorig and Davis[1] was substracted from the total sensorineural hearing loss of the patients.

Figure 1 is a chart showing the degree of sensorineural loss after 25 years of repeated examinations and shows a breakdown of the various age groups. It will be noted that in the younger age groups the sensorineural loss is almost twice that one would expect from presbycusis. In the older groups, the loss associated with otospongiosis is equal to that expected in presbycusis for the high frequencies but much greater for the low frequencies. It will be further noted that the low frequencies as well as the high are affected by otospongiosis in distinction to the usually isolated high frequency loss due to presbycusis.

The mechanism by which the otospongiosis produces sensorineural hearing loss, however, is as still uncertain. Probably there is more than one etiology in many cases.

Siebenmann suggested there might be toxic substances, liberated by the otospongiotic focus into the inner ear fluids, that impaired the function of the cochlea.[2] More recently, using electron microscopy, Bretlau, *et al*[3] and Chev-

From the Otologic Medical Group, Inc. and the Ear Research Institute, Los Angeles, California.



Fig. 1 The graph illustrates the progressive sensorineural hearing loss in 220 patients examined repeatedly over a 25-year period. The total length of each bar indicates the sensorineural hearing loss in the various age groups. The light portion of each bar indicates the expected loss from presbycusis as determined by Glorig and Davis.[1] The patients were divided into age groups to indicate when they had their first audiogram. It will be noted that in the younger age groups the sensorineural loss is almost twice that one would expect from presbycusis. In the older age groups, the loss associated with otospongiosis is equal to that expected in presbycusis for high frequencies but much greater for the low frequencies. It is also obvious that the low frequencies, as well as the high frequencies, are affected by otospongiosis in distinction to the usually isolated high frequency loss seen in cases of presbycusis.

ance, *et al*[4] have demonstrated lysosomes at the margins of the advancing otospongiotic focus. They suspected that these lysosomes might produce a toxic substance that caused absorption of the normal bone and, if liberated into the inner ear fluids, could produce a sensorineural loss. Recently they have demonstrated an increase in enzymes in the perilymph in patients with far-advanced otospongiosis who underwent stapes surgery.

Ruedi described venous shunts between the otospongiotic focus and vessels of the cochlea.[5] He suspects that these might produce venous congestion, interfering with the normal metabolism of the cochlea, thus producing a hearing loss.

Atrophy and hyalinization of the spiral ligament have been found to be associated with the sensorineural hearing loss that occurs in patients with otospongiosis. The mechanism that produces the atrophy and hyalinization is as yet not established.[6]

It is possible that the encroachment of the otospongiotic focus on the cochlear capsule can distort it and the basilar membrane, inhibiting the traveling wave throughout the rest of the cochlea.

METHODS AND MATERIALS

One hundred pairs of temporal bones of patients, with clinical antemortem evidence of otospongiosis, were evaluated. There were complete records on all of these patients which included physical examination and audiometric data including air, bone, and speech. In many patients there were other hearing tests performed, such as Békésy, tone decay, and SISI. Many of these patients had had vestibular tests and X-ray evaluation, either by routine x-ray techniques or polytomography.

The temporal bones were decalcified, embedded in celloidin, and sectioned in 20-micron thicknesses. Every tenth section was mounted and stained with H and E. Occasionally, additional sections were prepared and stained with Gomeri, Mallorv, and Bodian stains. We looked for the following: 1) absence (partial or complete) of hair cells, neurons, and ganglion cells; 2) atrophy and hyalinization of the spiral ligament; 3) evidence of vascular shunts between the cochlea and otospongiotic focus; and 4) width of the basilar membrane adjacent to the otospongiotic focus.

RESULTS

Organ of Corti. In some patients numerous hair cells were found to be

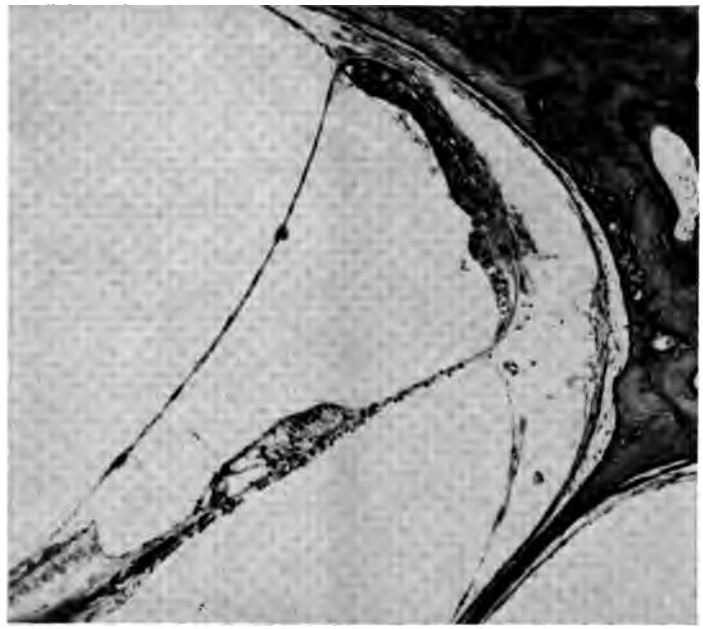

Fig. 2. Otospongiosis involving the endosteum adjacent to the spiral ligament in a patient with an average 50 dB loss in the speech frequencies by bone conduction tests. There is no evidence of an abnormality of the organ of Corti, stria, or spiral ligament with light microscopy. (H. and E., X100)

lacking, particularly the outer cells. This deficiency was most often associated with hyalinization of the spiral ligament. However, there were some patients with clinical evidence of sensorineural hearing loss who demonstrated, by light microscopy, a normally appearing organ of Corti (Fig. 2).

A correlation of the degree of abnormality of the organ of Corti and the sensorineural hearing level could not be made as the sole explanation of the hearing loss.

Spiral Ligament. We have demonstrated a relationship of otospongiosis involving the endosteum adjacent to the spiral ligament.[7] About half of the patients in the Institute collection showing an antemortem bone conduction threshold of 50 dB or more also exhibited hyalinization of varying amounts. This hyalinization always appeared in the peripheral portion of the spiral ligament adjacent to the otospongiotic focus involving the endosteum (Fig. 3). In the turns of the cochlea without otospongiosis, there was no hyalinization (Fig. 4). The cause of this degenerative change in the spiral ligament remains obscure, but it may well be due to the toxic influences of the enzymes secreted by the lysosomes as suggested by Bretlau, *et al* and Chevance, *et al*[3,4] or some abnormal metabolism in the ligament, possibly from hypoxia due to the vascular shunts described by Ruedi.[5]

Vascular Shunts. Ruedi[5] described venous shunts between the venules of the inner ear and the otospongiotic focus adjacent to it (Fig. 5). He postulated that these shunts could produce venous congestion and hence influence the metabolism of the cochlea. This could result in hypoxia and degenerative changes in the spiral ligament such as the hyalinization described in the preceding paragraphs.

Hypoxia due to shunting of blood may also produce new bone formation in the cochlea (Fig. 6) which could also act as an aneurysm, shunting blood

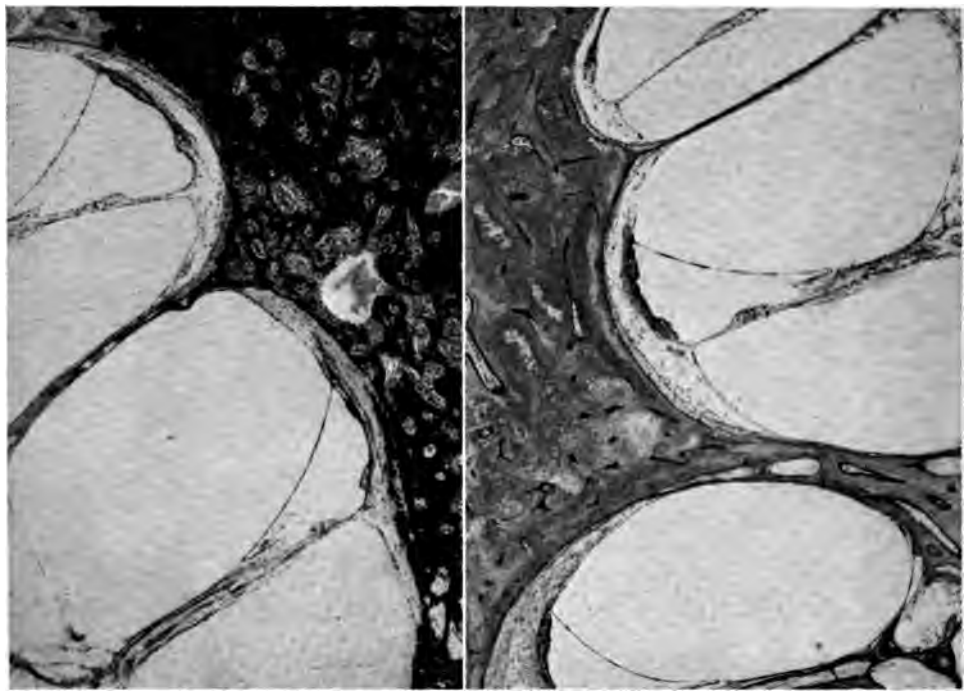

Fig. 3. Active otosclerotic focus adjacent to spiral ligament. Evident is hyalinization and calcification of the spiral ligament, distortion of the cochlear wall, and atrophy of the stria vascularis. (X50)

Fig. 4. Anterior portion of the cochlea of the same patient shown in Figure 3. The stria and spiral ligament appear normal. There is no distortion of the cochlear wall. (X50)

away from the spiral ligament and into the expanding growing otospongiotic lesion. The resulting hypoxia may interfere with the nutrition of the cochlea, much as a hemangioma or aneurysm will impair the growth of a limb or other structure. This might also result in a buildup of metabolites in the cochlear fluids.

Perhaps the stria vascularis, an integral part of the spiral ligament, has a selective absorptive function, rather than secretory and absorptive as some have suggested. Should this be the case, interference of the circulation could result in a buildup of metabolites in the inner ear fluids. Possibly the stria acts like a kidney tubule in being able to selectively absorb certain ions and molecules while rejecting others as the tubule does. This might indicate that the arteries beneath the organ of Corti are analogous to the glomerulus in the kidney and the stria to the kidney tubule. If this were the case, an interference of the circulation to the stria due to vascular shunts could decrease its efficiency. This interference would result in a buildup of carbon dioxide and other products of metabolism and interfere with the normal function of the hair cells in those cases in which there was found, by light microscopy, to be no abnormality.

Toxic Influences. Bretlau, *et al*[3] and Chevance, *et al*[4] have demonstrated lysosomes at the advancing edge of the otospongiotic focus. This explains why bone seems to be absorbed and replaced by the otospongiotic lesion without the evidence of osteoclasts at the advancing edge of the lesion. (Therefore, the multinucleated "osteoclasts" are possibly merely foreign body giant cells absorbing debris rather than cells capable of actually destroying bone.) They

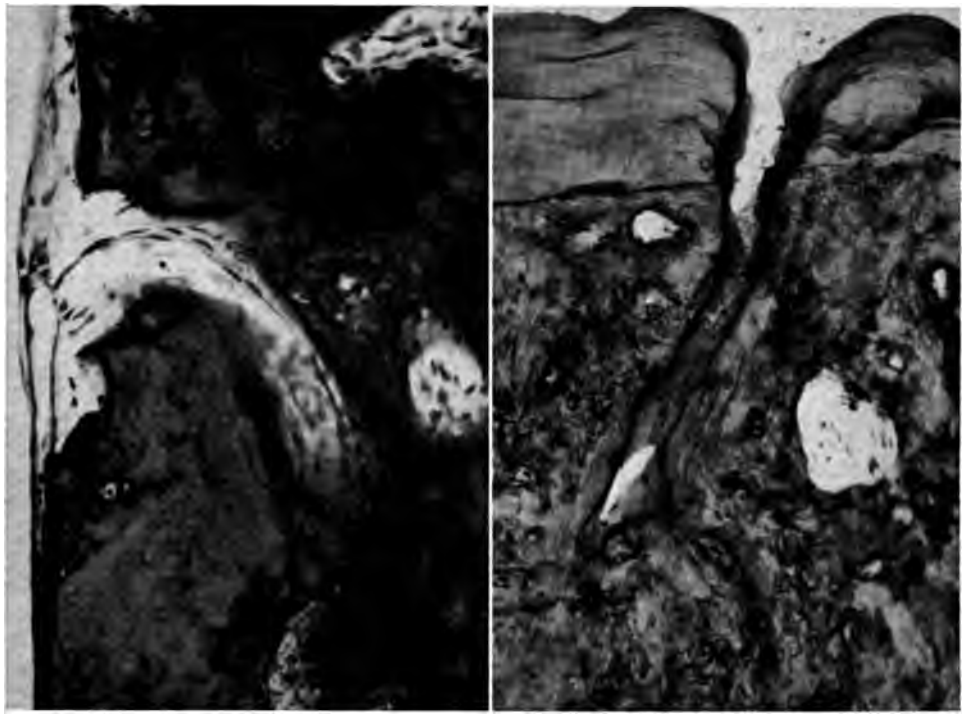

Fig. 5. Vascular shunt between the scala tympani and active otospongiotic focus, similar to those described by Ruedi.[5] Such shunts could alter the metabolism of the inner ear fluids and hence the organ of Corti. (X430)

Fig. 6. Another vascular shunt between the scala tympani and otospongiotic focus. There is lamellar bone present within the scala tympani. Such new bone formation is usually due to hypoxia of an organ. (X430)

postulated that the enzymes secreted by the lysosomes, when liberated into the inner ear fluids, could produce a toxic effect upon the metabolism of the hair cells. In analyzing the perilymph in patients undergoing stapedectomy with mixed hearing losses, they found increased amounts of these enzymes present. This could explain the poor sensorineural function in patients whose temporal bones showed no evidence of damage to the hair cells.

Cochlear Distortion. The propagation of the traveling wave along the basilar membrane was analyzed by Békésy.[8] Later, Tonndorf[9] demonstrated that increased tension on the basilar membrane, as occurs with endolymphatic hydrops, could account for the phenomenon of diplacusis in patients with this condition. However, neither individual, to our knowledge, analyzed what might happen should the basilar membrane insertions be relaxed.

Analysis of the width of the basilar membrane in the posterior basal turn of twelve cochleas with otospongiosis involving the endosteum indicated a median width of .78 mm. The median width of the basilar membrane in sixteen cochleas without otospongiosis was .85 mm, a statistically significant difference.*

This difference suggested the possibility of the cochlear focus encroaching upon the spiral ligament and narrowing the width of the basilar membrane and

---

* The difference of .07 mm between the two groups yielded a value of 3.80, which is significant beyond the .01 level, 2.77 required with 27 degrees of freedom.[10]



Fig 7. Cochlear model so constructed that the simulated basilar membrane is relaxable throughout the length of the model. It was found that relaxation of the membrane at the basal turn affected the amplitude of the traveling wave. The model is scale 1 cm to 1 mm.

the diameter of the cochlea. This distortion could possibly alter the amplitude of the traveling wave.

A model of the cochlea was constructed in such a manner that the basilar membrane could be narrowed in the simulated basal turn of the cochlea (Fig. 7). It was found that the amplitude of the traveling wave was decreased with the exception of the area where the membrane had been narrowed (Fig. 8). In this area the amplitude increased. This increase was felt to allow energy to be transmitted directly from the scala vestibuli to the scala tympani via the cochlear duct and basilar membrane, thus decreasing the amplitude of the traveling wave along the remainder of the basilar membrane.

These findings suggest that part of the sensorineural hearing loss in patients with cochlear otospongiosis could be due to basilar membrane distortion. Alteration of the diameter of the various turns of the cochlea may also be a factor.

DISCUSSION

Analysis of 36 pairs of temporal bones with otospongiosis involving the endosteum of the cochlea and an antemortem sensorineural hearing loss fails to reveal any single abnormality of the organ of Corti, spiral ligament, configuration of

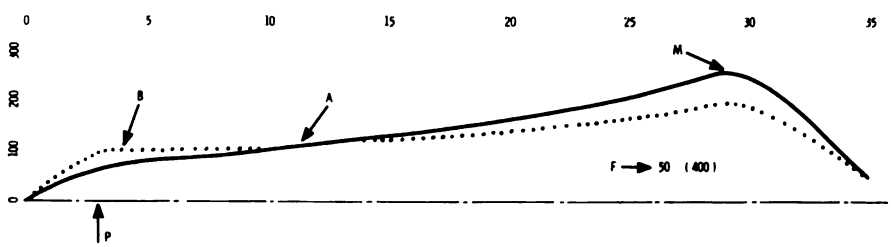

Fig. 8. Traveling waveform in the cochlea model before (solid line) and after (dotted line) relaxation of the basilar membrane in the simulated basal turn. The frequency for this wave pattern was 50 Hz. Note an increase in the amplitude of the wave in the relaxed area "B", indicating an escape of energy from the scala vestibuli to the scala tympani. The amplitude of the rest of the traveling wave is decreased. The numbers on the ordinate represent the distance in centimeters from the round window. The numbers on the abscissa represent the excursion of the basilar membrane in microns. "M" is maximum excursion of wave corresponding at scale to 400 Hz. "A" indicates little difference at high frequencies.

the cochlea, or vascular supply to account for the sensorineural hearing loss present in all cases. Comparison of the hearing level of these patients with nonotospongiosis patients indicates that the sensorineural hearing loss was far greater than one would anticipate in the general population of the same age group. Patients were excluded who had other known causes of hearing loss such as ototoxic drugs, acoustic trauma, and viral infections. It was found that in all but three cases the ear with the greater involvement of the endosteum by the otospongiotic lesion had the greatest sensorineural hearing loss. There is no question in my mind that otospongiosis produces a sensorineural hearing loss. The mechanism by which this occurs is probably multiple: 1) derangement of the vascular supply to the spiral ligament and hence the stria vascularis due to shunting of the blood into the otospongiotic focus; 2) toxic influences due to enzymes secreted by lysosomes at the advancing edge of the otosclerotic focus; and 3) distortion of the cochlear capsule and relaxation of the basilar membrane.

The importance of the roles of these various abnormalities in the production of the sensorineural hearing loss has yet to be determined. The work by Shambaugh[11] indicating that sodium fluoride will change the actively metabolic otospongiotic lesion into the inactive otosclerotic focus and hence prevent the progression of the sensorineural hearing loss is of utmost importance, even though we are as yet not certain of the role played by these various abnormalities in the cochlea as concerns the sensorineural hearing loss.

Valvassori[12] has demonstrated by polytomography that the sodium fluoride treatment does alter the type of otospongiotic focus. More recently we demonstrated the same, using strontium-85 and analyzing the radioactivity in the foot-plates of patients with mixed hearing losses.[13]

Microscopic examination of these foot-plates revealed that half underwent a change from an otospongiotic lesion to an otosclerotic lesion. The other half exhibited an otosclerotic lesion prior to and after administration of sodium fluoride. In spite of the apparent similarity of the type of lesion, the radioactivity was decreased as measured by strontium-85 in all but one patient.

There are, in the temporal bone collection of the Institute, three pairs of temporal bones with cochlear otospongiosis in both ears but stapedial fixation in only one. All three have an equal sensorineural hearing loss in both ears. We believe that the sensorineural loss in all three of these patients was due to the cochlear otospongiosis and that bilateral cochlear otosclerosis without stapedial fixation can occur, based upon the findings of Valvassori and ourselves utilizing the polytomography technique.[12,14] Regardless of the cause of the sensorineural hearing loss in patients with otospongiosis, it appears that sodium fluoride will convert the otospongiotic phase to the otosclerotic phase and prevent the progression of the sensorineural component of the hearing loss. This treatment has been described by Shambaugh[11] and substantiated bv polytomography by Valvassori[12] and later, using strontium-85, by us.[13] If the mechanism of the production of the sensorineural hearing loss could be determined, it might be feasible to reverse the sensorineural hearing loss in these patients.

CONCLUSIONS

There is little doubt that otospongiosis involving the cochlear capsule can produce a sensorineural hearing loss. Light microscopic examination of the organ of Corti fails to reveal any abnormality of the hair cells to account for this loss in the majority of the cases.

Several theories have been proposed and passed to account for this hearing loss: toxic substances produced by the otospongiotic focus; vascular shunts between the inner ear vessels and the otospongiotic focus; and atrophy of the organ of Corti and stria vascularis due to unknown causes. In this paper we present yet another possibility: im-

pingement upon the cochlear walls by the otospongiotic focus, causing a narrowing of the lumen of the cochlea and distortion of the basilar membrane. In all probability, more than one of these factors is responsible for the hearing loss in each case.

Analysis of the clinical records of 100 patients with otospongiosis indicates that the degree of sensorineural hearing loss is greater than one would expect from presbycusis. We present microscopic examples of the various factors responsible for the sensorineural hearing loss. A mechanical model of the cochlea demonstrates that if the basilar membrane in the basal turn of the cochlea is loosened or narrowed that the propagation of the traveling wave through the rest of the cochlea becomes decreased, except in the area of relaxation where it is increased. The loosened area corresponds to that area of the basilar membrane that responds to frequencies higher than those tested by routine audiometry.

Sodium fluoride and calcium treatment has been shown to decrease the rapidity of the sensorineural hearing loss due to cochlear otospongiosis. It is hoped that further understanding of the causes of the sensorineural hearing loss will lead to prevention or possibly correction of the hearing loss.

Request for reprints should be sent to Fred H. Linthicum, Jr., M.D., Otologic Medical Group, Inc., 2122 West Third St., Los Angeles, California 90057.

REFERENCES

1. Glorig A, Davis H: Age, noise, and hearing loss. Ann Otol Rhinol Laryngol 70: 556, 1961

2. Siebenmann F: Multiple Spongiosierung der Labyrinthkapsel als Sectionsbefund bei einem Fall von progressiver Schwerhorigkeit. Z Ohrenheilk 34:356-374, 1899

3. Bretlau P, Causse J, Jorgensen MB, *et al*: Histiocytic activity in the otosclerotic bone. Arch Klin Exp Ohren Nasen Kehlkopfheilkd 198:301-316, 1971

4. Chevance LG, Bretlau P, Jorgensen MB, *et al*: Otosclerosis: An electron microscopic and cytochemical study. Acta Otolaryngol [Suppl] (Stockh) 272:1-27, 1970

5. Ruedi L: Histopathologic confirmation of labyrinthine otosclerosis. Laryngoscope 75: 1582-1609, 1965

6. Holleman IL Jr, Harrill JA: Cochlear otosclerosis: Report of a case, with postmortem histologic findings. Laryngoscope 77:493-507, 1967

7. Linthicum FH Jr: Correlation of sensorineural hearing impairment and otosclerosis. Ann Otol Rhinol Laryngol 75:512, 1966

8. Békésy G: *Experiments in Hearing.* New York, McGraw-Hill, 1960, pp 485-534

9. Tonndorf J: Shearing motion in scala media of cochlear models. J Acoust Soc Am 32:238-244, 1960

10. Guilford JP: *Fundamental Statistics in Psychology and Education.* Ed. 4, New York, McGraw-Hill Book Co., 1965

11. Shambaugh GE Jr: Sodium fluoride for inactivation of the otosclerotic lesion. Arch Otolaryngol 89:381-382, 1969

12. Valvassori GE: Otosclerosis: A new challenge to roentgenology. Am J. Roentgenol Radium Ther Nucl Med 94:566-575

13. Linthicum FH Jr, House HP, Althaus SR: The effect of sodium fluoride on otosclerotic activity as determined by strontium^{85}. Ann Otol Rhinol Laryngol 82:609, 1973

14 Britton BH Jr, Linthicum FH Jr: Otosclerosis. Histologic confirmation of radiologic findings. Ann Otol Rhinol Laryngol 79:1, 1970

RECONSTRUCTION OF THE OPEN MASTOIDECTOMY EAR: A SIX YEAR PROGRESS REPORT

MANSFIELD F. W. SMITH, M.D.

SAN JOSE, CALIFORNIA

SUMMARY – This report deals with 61 mastoid cavities which were revised or reconstructed using homograft techniques over a six-year period. Discussed are the variety of homograft procurement techniques and surgical homograft techniques which have been abandoned and included in a review of 16 consecutive mastoid revisions performed from 1973-1974 utilizing a standard surgical technique.

From 1968 to 1972 a series of mastoid revisions and reconstructions was performed utilizing standard otologic techniques but encompassing a variety of individual techniques incorporating autograft and homograft material. Based on this four-year experience, more standardized techniques of homograft reconstruction evolved, and during 1973 and 1974, these techniques were utilized in all mastoid revisions and reconstructions.

The substance of this report deals with the problems of homograft mastoid reconstructions and with the various surgical techniques which have been unsatisfactory. In addition, it is a review of 21 cases of mastoid reconstruction utilizing a standard surgical technique.

The otologic tissue discussed in this paper was processed and stored in tissue culture medium with Hank's salts with added antibiotic antimycotic mixture.[1]

Obtaining meaningful data on indications, surgical management, and functional results of surgical revision of these problem mastoid cavities is difficult because of varying methods of homograft preparation, changing surgical concepts, and revising prior operated patients. However, it is significant to indicate the combinations of autograft and homograft mastoid surgical reconstruction procedures that have not been satisfactory and why.

During the 1968 to 1972 period certain mastoid revision procedures with otologic homografts were not successful in our hands for a number of reasons. The first and most important reason for poor results was Eustachian tube dysfunction. Occasionally, there was a loss of continuity of the air column between the middle ear and the mastoid cavity. Failure of aeration resulted in loss or displacement of ossicular tissue, the tympanic membrane, and the reconstructed posterior osseous canal.

The second reason, also a major problem, lay in reconstructing the posterior canal and establishing the critical anatomical relationship between the lateral epitympanic plate, ossicles, and mesial wall of the posterior epitympanic space. Often, short-term anatomical appearance of the reconstructed posterior canal and tympanic membrane was good. However, in three to four years, it was not unusual for a posterior superior retraction pocket in the tympanic membrane to occur with resultant potential for cholesteatoma behind the reconstructed canal.

These experiences with Eustachian tube dysfunction and posterior superior retraction pockets engendered the following questions: Why convert an open small mastoid cavity into a closed cavity with at least a significant chance of Eustachian tube failure (in our series approximately 25%) with resultant homograft absorption and displacement? The critical question is that if the mastoid reconstruction procedure is going to fail, then what?

We considered it better to revise the

From the Department of Surgery, Division of Otolaryngology, Stanford University and Santa Clara Valley Medical Center, California.

mastoid cavity, line it with autograft connective tissue, and reconstruct the tympanic membrane, malleus, and stapes as a myringostapediopexy (Type III, modified radical mastoid) with healthy residual structures plus autografts and homografts when indicated. In this situation Eustachian tube dysfunction does not create an additional problem, and the scutum anatomical dilemma is obviated. Therefore, we have abandoned certain types of homograft processing and have discontinued certain autograft-homograft mastoid revision techniques.

Otologic homografts were prepared and stored in 70% ethanol from 1968 to 1972.* We were not satisfied with alcohol otologic homograft preparation for the following reasons: the healing of soft tissues over posterior osseous canal alcohol prepared homografts was often protracted. Further, the alcohol prepared ossicles behaved as sequestered dead bone, and for a period of between two and four years we noted bone absorption, particularly of homograft stapes. Such agents as alcohol, organic mercurial (ciliate), formalin, and gluteraldehyde all fix the osseous and fibrous otologic tissue. In addition, there are chemical changes in the tissue as well as gross anatomical alterations, such as stiffness of the fibrous tissue, particularly with formalin and gluteraldehyde. Such fixed chemically altered homograft tissue may take on the properties of alloplastic tissue with the potential of ultimate extrusion.

The autograft-homograft techniques that have been discontinued are the following:

Composite Homografts Consisting of the Three Ossicles. In addition to retraction pockets, absorption, and displacement with Eustachian tube dysfunction, the functional results with composite ossicular chain reconstruction have been poor, which has been a result of displacement and fixation of the ossicles.

Autograft Cortical Mastoid Bone Reconstruction of the Posterior Canal. This method is no longer utilized because of the difficulty of establishing the scutum in an appropriate anatomical relationship with a resultant retraction pocket posteriorly and superiorly.

Fibrous Tympanic Membrane Homograft. We have found fascia to be superior to a fibrous tympanic membrane homograft in routine tympanoplastic procedures. However, we occasionally use a fibrous tympanic membrane homograft with attached periosteal cuff after a fascia graft failure, particularly when there has been lateralization. We almost always overlay the fibrous tympanic membrane with fascia. We have not experienced delamination of the fascia from the fibrous tympanic membrane in the tissue culture prepared homograft tissue. The resultant tympanic membrane has been thin and mobile.

SURGICAL TECHNIQUES

The open mastoid cavity is revised by either reconstruction of the posterior canal and conversion to a closed cavity or revised and relined with a Mosher-Palva flap; thus, the cavity becomes in concept an enlarged external auditory canal (EAC).

Reconstruction of the posterior osseous canal is now carried out only when there is an extremely large mastoid cavity with a high facial ridge. The canal is also reconstructed when there are minor defects in the posterior osseous canal, such as an extensive atticotomy, where approximately 50% of the canal remains. These canal defects are reconstructed with a homograft posterior osseous canal, often with the attached fibrous tympanic membrane and long process of malleus and generous periosteal cuff when total tympanic membrane and malleus long-process re-

* All of the homograft otologic tissue discussed in this report was procured, processed, and stored by the Ear Transplant Unit of the Northern California Transplant Bank. The Northern California Transplant Bank is included in the organization of the Institute for Medical Research of the Santa Clara Valley Medical Center which is a nonprofit research organization for the Staff of the Santa Clara Valley Medical Center. The Santa Clara Valley Medical Center is one of the teaching hospitals affiliated with Stanford University.

placement is necessary. The advantage of this type of graft is that the relationship of the scutum to the fibrous tympanic membrane are anatomically correct by virtue of the orthotopic homograft. Also, the curvilinear shape of the homograft posterior canal is suitable.

In concept, revision of the open small cavity to a large EAC embodies the following principles: 1) removal of residual disease, 2) exteriorization of all areas of the mastoid and middle ear including an adequate meatoplasty, 3) lining of the cavity, and 4) entrapment of mucous membrane in the middle ear by reconstruction of the tympanic membrane.

All active disease is controlled preoperatively if possible. No open mastoidectomy ears with cholesteatoma of the mastoid were lined with a muscle periosteal flap.

In the following paragraphs, a revision of an open radical mastoidectomy ear without a stapes arch and with a mobile footplate is described. A postauricular incision with a superior hockey stick extension is made through the superficial fascia with elevation of a post-auricular muscle periosteal flap based on the pinna anteriorly as described by Mosher[2] and Palva.[3] The periosteal epithelial membrane is then dissected from the mastoid cavity over the facial ridge and medial aspect of the middle ear to the anterior osseous canal wall at the level of the fibrous annulus. The mastoid cavity is appropriately revised, all residual disease is removed, the facial ridge lowered, and, if there is a large mastoid tip, the osseous tip structure is removed to allow superior displacement of the digastric muscle to reduce the inferior portion of the mastoid cavity.

The recipient mobile foot-plate is denuded of all soft tissues. This is done in an anterior to posterior orientation with a fine sharp needle. The soft tissue is deflected from the foot-plate towards the VII nerve superiorly and onto the promontory inferiorly. In most instances, an envelope of soft tissue is developed inferior and superior to the oval window. The donor stapes footplate is placed adjacent to the recipient foot-plate without any interposition of soft tissue. The previously elevated soft tissues are then placed back over the foot-plate of the donor. A 4x4 mm .005 inch medical grade Silastic®* sheeting is cut on the diagonal to 0.1 mm of a corner. Each side of the halved square of silicone sheeting is placed on the promontory and the other on the facial nerve area. The intent in using the Silastic® is to prevent fibrous adhesions and ultimate displacement or fixation of the stapes. Gelfoam®** pledgets are then placed on the silicone sheeting to stabilize the stapes.

Reconstruction of the malleus is accomplished by inserting a homograft fibrous tympanic membrane with attached generous periosteal cuff of the donor EAC and also the attached long process of the incus. All epithelium has been removed from this graft. The head of the malleus has been removed because it is unnecessary in the shallow middle ear cavity of the open radical mastoidectomy ear. Any residual fibrous tympanic membrane and fibrous annulus are removed from the recipient preventing the problem of retained epithelial tissue in the fibrous annulus, particularly in the anterior sulcus. If there is residual osseous tympanic sulcus, the homograft annulus is then positioned into this sulcus. The periosteal cuff is incised from lateral to medial to the annulus at approximately the six o'clock position in order to drape the periosteal cuff onto the anterior osseous canal. The fibrous vascular strip area is placed superiorly onto the area of the horizontal semicircular canal. Temporalis fascia is placed onto the lateral aspect of the fibrous tympanic membrane and incised from inferior to superior in the area that would be adjacent to the long process of the malleus. In this manner the fascia adapts to the normal conical shape of the homograft

* Dow-Corning Chem. Co., Medical Products Div., Midland, Mich.
** The Upjohn Co., Kalamazoo, Mich.

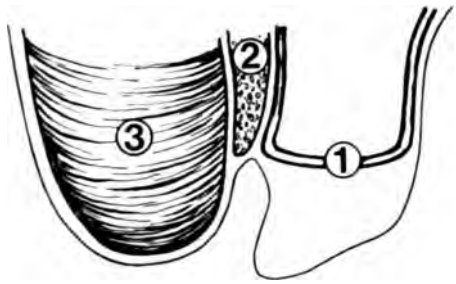

Fig. 1. Diagrammatic representation of middle ear and mastoid demonstrating the use of two pedicled soft tissue flaps and homograft bone. 1) Pedicled epithelial periosteal flap. 2) Homograft bone. 3) Pedicled muscle periosteal flap.

reconstructed drum. The fascia is carried posteriorly into the mastoid cavity, and the previously prepared periosteal muscle flap is placed into the mastoid cavity defect and onto the lateral aspect of the fascia and homograft fibrous posterior extension. Because of the shallow middle ear space, the homograft fibrous tympanic membrane is now draped over the homograft reconstructed stapes arch, thus forming a myringostapediopexy. If any of the residual epithelial periosteal membrane that was elevated from the mastoid cavity is healthy, it can be placed against the anterior limit of the periosteal muscle flap that is now in filling the mastoid defect (Fig. 1). This periosteal epithelial membrane that has been dissected from the mastoid cavity is based on the medial aspect of the pinna but anterior to the base of the muscle periosteal flap. Often this residual periosteal epithelium is healthy and allows for quick epithelialization of the Mosher-Palva flap on its anterior limit. These pedicled flaps do not obliterate the mastoid cavity in the long term, but they do afford excellent lining of the mastoid cavity and often substantially reduce the size of the cavity. The external auditory meatus is revised through an end aural incision as described by Stacke.[4] The area of the reconstructed tympanic membrane is then packed with Gelfoam® soaked in 10% Chloromycetin®* out to the level of the meatus. The post-auricular incision is repaired, and a mastoid pressure dressing is applied for at least one week.

* Parke, Davis & Co., Detroit, Mich.

RESULTS

From 1968 to 1974, 61 patients with open mastoid cavities have been revised. Part of these patients came from the author's private practice and the other part were supervised staff patients of the Stanford Otolaryngology Service at the Santa Clara Valley Medical Center. From January 1968 to June 1972, 40 open mastoid cavities were revised. However, because of varying methods of homograft preparation, changing surgical concepts, and revisions of prior patients, no meaningful data were obtained. However, the autograft homograft procedures for open mastoid cavity revision that have not been successful have been indicated.

From 1973 to 1974, 21 patients with open radical mastoid cavities were reconstructed. Five of the 21 patients were lost to follow-up, so 16 consecutive patients were observed. Preoperatively, eight of the 16 patients had recurrent drainage. All 16 were interested in having improved hearing. The primary interest of four of the 16 was having a "waterproof ear," enabling them to participate in water sports. In all 16 patients active infection was controlled preoperatively by conservative care. Eustachian tube patency or function or both was assessed clinically without unusual apparatus, and only one of the 16 patients had a proven preoperative air-containing middle ear space, in this situation a cavum minor.

At the time of surgery three patients were noted to have active cholesteatoma. The status of the stapes in the 16 patients at the time of surgery is as follows: 1) stapes arch present in five patients, 2) stapes arch absent in 11, 3) stapes foot-plate mobile in 15, and 4) stapes foot-plate fixed in one (One of the five patients with an intact arch).

Postoperative results were as follows: 1) the anatomic appearance of the cav-

ity was dry, clean, and shallow, in 16 of 16 patients; 2) the tympanic membrane was satisfactory in 12 of 16; unsatisfactory in four because of retraction and hypomobility in three and perforation in one; 3) the malleus position was satisfactory in 15; unsatisfactory in one; and 4) the middle ear was air-containing in 12 of 16; fluid in one; atelectatic in three.

The following describes the functional results. Two of the 16 patients were converted to normal hearing. One had a mild sensorineural loss of greater than 20 dB. All patients preoperatively had normal speech discrimination, which remained normal postoperatively. The maximum gain in hearing was a speech reception threshold (SRT) of 38 dB from a preoperative SRT of 74 and a postoperative SRT of 36. The average gain in the SRT was 17 dB.

DISCUSSION

The advantages of converting the open radical mastoid ear to a modified radical mastoidectomy with homograft and autograft material and lining of the disease free mastoid cavity with a Mosher-Palva flap are: 1) involves a one stage procedure, 2) does not require alloplastic material, 3) embodies well-defined ear surgical techniques with proven long-term anatomical and functional results, and 4) if there is failure of middle ear aeration, the procedure does not create any additional problems for the patient, such as absorption of a reconstructed posterior osseous canal or retraction of epithelium into a recreated closed mastoid cavity.

SUMMARY

Revision and reconstruction experience with 61 problem radical mastoid cavities over a six-year period is the basis of this report. Reconstruction of the posterior osseous canal with homograft osseous canal is carried out both in patients with very large mastoid cavities that have partially intact posterior canals, and also in patients with relatively minor defects in the posterior osseous canal regardless of the size of the mastoid cavity.

Included are the details of surgery and the anatomical and functional results of converting open radical mastoid cavities to a modified radical mastoid cavity using homograft and autograft material and lining of the mastoid cavity with an anterior pinna based periosteal muscle flap.

The tympanic membrane and malleus is reconstructed with homograft material consisting of the fibrous tympanic membrane, attached long process of the malleus and attached periosteal cuff of the EAC. The fibrous tympanic membrane contacts the stapes capitulum with a resultant myringostapediopexy. Forty-five patients with reconstructed open mastoid cavities, operated prior to 1973, were summarized by indicating the operative procedure used and the reason for its discontinuation.

Results of 16 consecutive revised radical mastoid cavities done in 1973 and 1974 were satisfactory. All 16 patients developed dry, clean, shallow cavities. Twelve of the 16 patients developed an air-containing middle ear space. However, four of the 16 (25%) did not have satisfactory Eustachian tube function, three developed atelectatic middle ears, and one, a serous otitis media. The average gain in the SRT of the 16 revised mastoid cavities was 17 dB.

Request for reprints should be sent to Mansfield F. W. Smith, M.D., 751 South Bascom Ave., San Jose, Calif. 95128.

REFERENCES

1. Smith MFW, Downie D: Otologic homograft indications, techniques and results. Trans Am Acad Ophthalmol Otolaryngol 80: 47-51, 1975

2. Mosher HP: A method of filling the excavated mastoid with a flap from the back of the auricle. Laryngoscope 21:1158-1168, 1911

3. Palva T: Surgery of chronic ear without cavity: results in 130 cases with musculoperiosteal flap and fasciotympanoplasty. Arch Otolaryngol 77:570-580, 1963

4. Stacke L: Stackes Operationsmethode. Arch Ohrenheilk 35:145, 1893

EXPERIMENTAL AURAL CHOLESTEATOMA CAUSING BONE RESORPTION

MAXWELL ABRAMSON, M.D.
IOWA CITY, IOWA

RICHARD G. ASARCH, M.D.
DENVER, COLORADO

WARD B. LITTON, M.D.
MOLINE, ILLINOIS

SUMMARY – A series of experiments were carried out on 55 guinea pigs in four groups to study the conditions fostering bone resorbing epidermal cysts. The first group had free grafts of canal wall skin applied to the cochlea with and without talc application. The second group had canal skin flaps applied to the cochlea with and without subsequent talc application. The third group had talc applied either to the tympanic membrane or on the cochlea. The fourth group had a canal skin flap inserted into a mucosal pocket in the bulla. The animals were killed three to four months after surgery and the temporal bones were prepared for histology. Epidermal cysts were found at the cochlea in 8 of 55 animals. Cochlear fistulas were found in 6 of 55 animals. The fistulas were associated with epidermal cysts in three cases, otitis media in two cases, and talc granuloma in one case. These experiments show that migrating skin attached to a source of epithelium is capable of inducing bone resorption. Chronic foreign body granulomas and chronic sepsis are also capable of resorbing bone. These three conditions all produce a layer of undifferentiated connective tissue containing chronic inflammatory cells lying against the resorbing bone.

Ever since Berberich began pouring hot tar into the external ears of laboratory animals almost fifty years ago,[1] otologists have been attempting to create an experimental model of middle ear cholesteatoma. A variety of inflammatory agents have been instilled through a defect in the tympanic membrane or bulla in order to induce epidermal cysts in the middle ear. Beginning with hot and cold tar,[1] these agents have included croton oil, olive oil, benzypyrene,[2] oxalic acid,[3] talc,[4] quinine,[5] and methyl cholantholene.[6] Friedmann[7,8] induced otitis media with a variety of bacterial cultures while Milstein[9] and more recently, Walsh and co-workers,[10] transplanted skin into the middle ear in attempts to create experimental cholesteatomas. These methods met with various degrees of success, supporting the hypothesis that cholesteatomas result from migration of canal wall skin into the middle ear and do not arise *de novo* from metaplasia. The likelihood of finding skin in the ears in these animals appears to correlate with the degree of inflammation caused by the agent and the extent of suppuration. Middle ear cholesteatoma in humans, however, occurs without external inflammatory agents and even without a history of antecedent acute suppurative otitis media.

We have defined middle ear cholesteatoma in both histologic and functional terms as an epidermal cyst containing subepithelial granulation tissue, characterized by progressive growth and the ability to induce underlying bone resorption. The mechanism of this

---

From the Department of Otolaryngology and Maxillofacial Surgery at the University of Iowa, Iowa City, Iowa.

This investigation was supported by PHS grant NS 10608 from the National Institute of Neurological Diseases and Stroke and the Deafness Research Foundation.

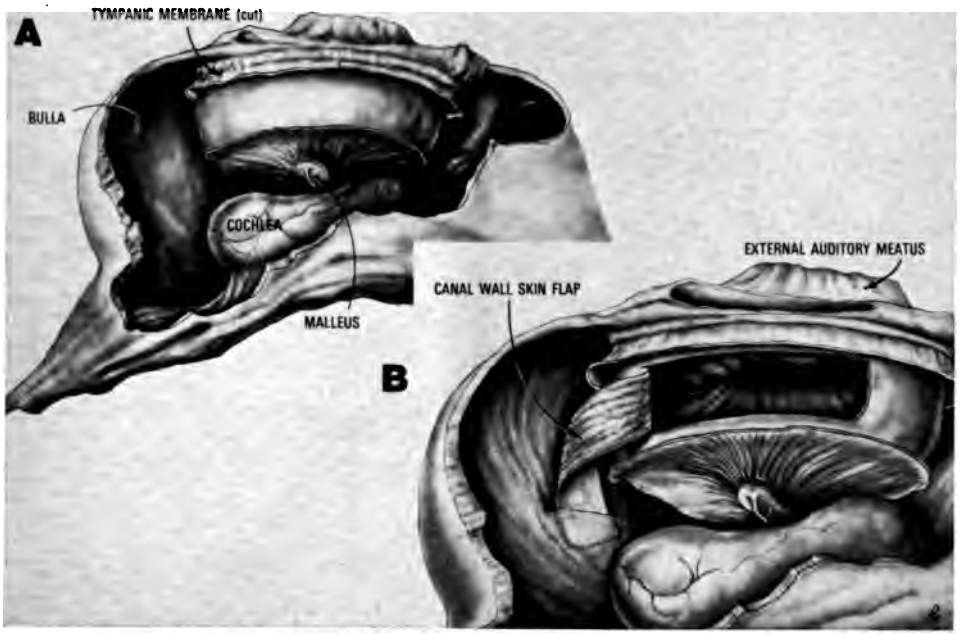

Fig. 1. View of the operative approach used in the experiments. The animal's left ear is shown from a ventral approach through the neck. The nose would be at the left side of the illustration and the left pinna would be at the top. A) The ventral wall of the bulla and the outer tympanic membrane have been removed in preparation for removal of ventral canal wall skin. B) The operation used on Group 4 is shown. A flap of canal skin has been inserted into a mucosal pocket in the bulla dorso-lateral to the cochlea.

bone resorption is perhaps the most important clinical question posed by the disease, since the morbidity of cholesteatoma results from loss of bone causing conductive hearing loss and exposing underlying soft tissues to injury. Our interest in the interaction of cholesteatoma and bone was stimulated by Abramson's finding of a collagen dissolving enzyme produced by cholesteatomas *in vitro.*[1] This enzyme was present in greatest amounts in the cholesteatoma matrix and in the skin of the bony ear canal compared with the cartilaginous ear canal and arm skin. If proteolytic enzymes produced by a cholesteatoma are relevant in the bone resorption process, then skin should be capable of resorbing bone without pressure or perhaps even without sepsis.

In this study we have sought to reproduce the conditions necessary to induce bone resorption in chronic otitis media by using various techniques to introduce skin into the ear of guinea pigs. We have focused our attention on the cochlea for two reasons. First, the peculiar configuration of the guinea pig's middle ear makes determination of the boundary difficult between the middle and external ear on histologic sections. Epidermal cysts at the cochlea would be unquestionably in the middle ear. Second, we needed to define a site where net resorption of bone could be clearly determined. The bone of the cochlea is not only thin but also encloses a delicate and easily altered organ. We used canal wall skin as free grafts, as pedicled grafts on the cochlea, and as pedicled grafts inserted into a mucosal pocket in the bulla. Talc was used to stimulate a granulomatous response either by itself or with skin since it is essentially inert and does not have a direct, injurious effect on bone. We were able to induce epidermal middle

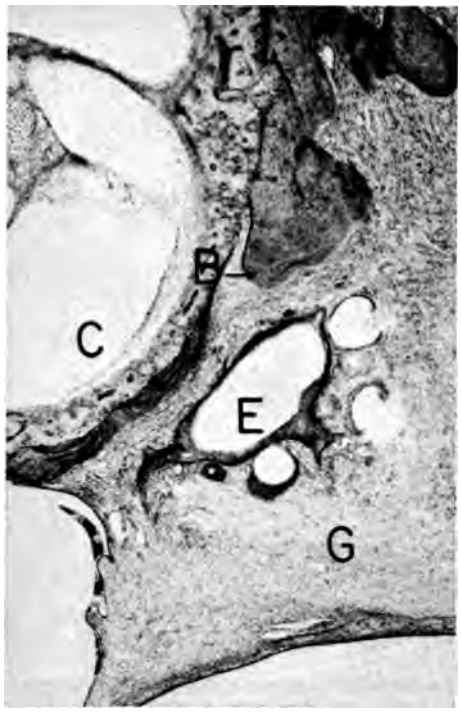

Fig. 2. Animal 4 from Group 1:B shown three months after a free graft of canal wall skin and talc was placed on the cochlea. A granuloma (G) as well as a cyst of hypertrophic squamous epithelium (E) is seen at the cochlea (C). There is new bone (B) at the cochlea. X40.

ear cysts and bone resorption under various conditions but with certain histologic features in common.

METHODS AND MATERIALS

Four groups of young guinea pigs (150 - 200 gm) were operated upon from a ventral approach through the neck exposing the middle ear through the bulla. In group I:A, ventral canal wall skin was removed as a free graft through a defect in the tympanic membrane and placed on the cochlea after removing the mucosa (Fig. 1A). Group I:B had talc placed on the cochlea at the same time as the skin graft. In Group 2:A, the canal wall skin was left attached nasally and rotated onto bare cochlea; shreds of mucosa removed from the cochlea were used to cover the tip of the flap. In Group 2:B, the bulla was reopened two months after the first operation and talc placed in the middle ear. Group 3:A had talc applied to the medial aspect of the intact tympanic membrane following the method described by Ruedi.[4] Group 3:B had talc applied to the bare cochlea. In Group 4, a pedicled flap was fashioned as in Group 2, rotated into the middle ear but placed in a mucosal pocket just dorso-lateral to the cochlea (Fig. 1B).

Animals were killed three to four months after initial surgery. The bullas were removed, fixed in 10% buffered formalin, decalcified, and embedded in celloidin. The bones were sectioned in a coronal plane from nasal to caudal, stained with H. and E., and examined under light microscopy.

RESULTS

Epidermal Cysts at Cochlea. Epi-

TABLE I

RESULTS OF EXPERIMENTAL CHOLESTEATOMA IN GUINEA PIGS

Group	*Method*	*Duration (months)*	*No. of Animals*	*Epidermal Cyst at Cochlea*	*Cochlea Fistula*	*Otitis Media*
1:A	Canal skin graft to cochlea	4	10	0	0	9
1:B	Canal skin graft and talc to cochlea	3	6	2	0	6
2:A	Canal skin flap to cochlea	4.5	11	1	0	0
2:B	Canal skin flap to cochlea then talc in middle ear	4.5	5	2	1	3
3:A	Talc to TM	4.5	7	0	1	0
3:B	Talc to cochlea	3	6	0	0	0
4	Canal skin flap under bulla mucosa	4	10	3	4	7
Total			55	8(15%)	6(11%)	25(45%)

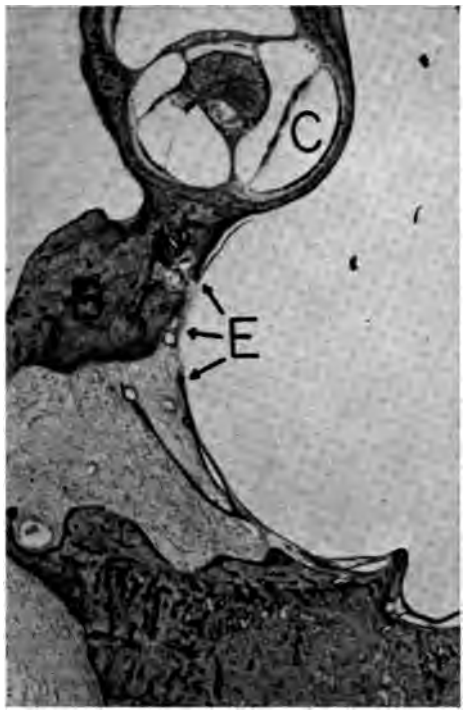

Fig. 3. Animal 4 from Group 2:A with a canal skin flap placed on the cochlea. New bone (B) is seen extending from bulla defect to the cochlea (C). The canal skin flap containing several small epidermal cysts (E) extends to the cochlea (C). X20.

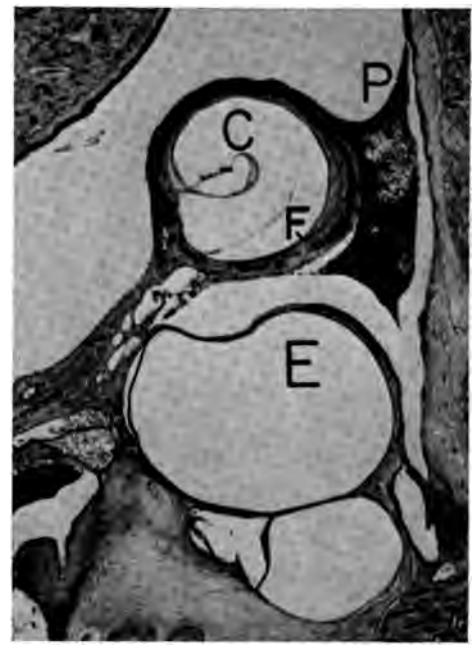

Fig. 4. Animal 5 from Group 2:B, two months after having a canal skin flap on the cochlea and talc instilled into the middle ear. A large epidermal cyst (E) is shown adjacent to a fistula (F) of the cochlea (C) wall as well as a collection of pus cells (P). X20.

dermal cysts at the cochlea were induced in 15% or 8 of 55 animals (Table I). Free grafts of canal wall skin, Group I:A, failed to produce epidermal cysts in ten animals. The addition of talc, Group I:B, resulted in epidermal cysts at the cochlea in two of six animals (Fig. 2).

Small epidermal cysts were found in only 1 of 11 animals with canal wall skin flaps (Fig. 3) but were present in two of five animals having subsequent talc placements (Fig. 4). We were not able to produce epidermal cysts with talc alone in 13 animals, either at the tympanic membrane or on the cochlea. Epidermal cysts were found in three of ten animals having skin placed in the mucosal pocket at the bulla (Figs. 5, 6, and 7). These experiments indicate that free grafts of canal skin do not

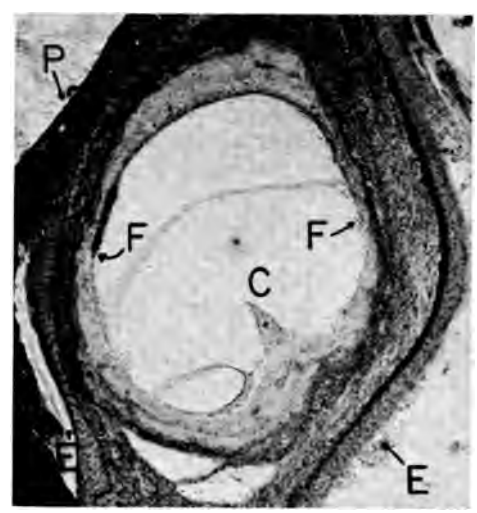

Fig. 5. Animal 6 from Group 4, with a canal skin flap placed under bulla mucosa. Squamous epithelium (E) has migrated around the cochlea (C) producing a cochlear fistula on both sides (F and F). Purulent exudate (P) is also present at the cochlea. X40.

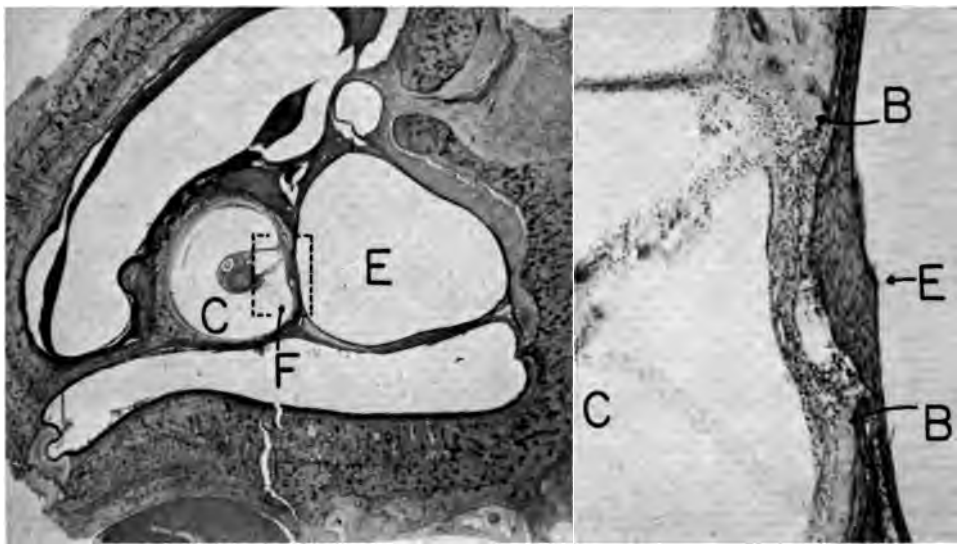

Fig. 6. Animal 3 from Group 4, showing a large epidermal cyst (E) in the middle ear eroding the bony wall of the cochlea (C) at F. There is no retained epithelial debris or sign of sepsis in the area of bone resorption. X15.

Fig 7. Animal 3 showing the area in brackets on Figure 6 in higher magnification. The hypertrophic epidermal layer (E) is shown resorbing the cochlea (C) wall at B. There are no pus cells. Loosely arranged subepithelial connective tissue covers the bony defect. X100.

readily grow on the cochlea. Epidermal proliferation seems to be enhanced, however, by the inflammatory effect of talc. Skin that is well covered by mucosa (Group 4) and is attached to a source of epithelium is most likely to migrate and proliferate into a cyst.

Bone Resorption at the Cochlea. A cochlear fistula or complete resorption of otic capsule at the cochlea was induced in 6 of 55 animals for an incidence of 11% (Table I). Bone resorption was not seen in Group I with free skin grafts on the cochlea despite the presence of otitis media in 15 of the 16 animals.

Otitis media, defined by the presence of purulent exudate in the middle ear cavity, occurred in 21 animals for an incidence of 21% (Table I). The exudate consisted primarily of decomposing neutrophils, as in acute otitis media.

In Group 2:B, a fistula of the cochlea occurred in one animal in which a canal wall flap was made and talc was applied. An epidermal cyst plus purulent exudate is seen adjacent to the defect (Fig. 4).

Cochlear fistula occurred in one animal in which talc only was applied to the tympanic membrane (Fig. 8). Connective tissue could be seen extending from the tympanic membrane to the cochlea. Talc particles were evident at the tympanic membrane but were not seen at the cochlea. The connective tissue at the bony defect contained some inflammatory cells but no exudate was found in the middle ear (Fig. 9).

Four cochlear fistulas occurred in Group 4 with a canal skin flap in the bulla. They occurred in two animals with otitis media alone (Figs. 10 and 11), one animal with skin plus otitis media (Fig. 5), and one animal with skin only (Figs. 6 and 7).

Table II lists the six cases of bone resorption in terms of the tissue adjacent to the cochlea. Cochlear fistulas occurred in three of eight animals with epidermal cysts of the cochlea, including one of three with skin but no otitis media at the cochlea and two of five animals with skin plus otitis media at the cochlea. Bone resorption also occurred in 2 of 21 animals with otitis

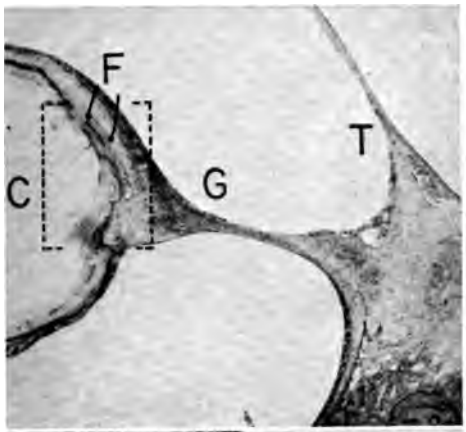

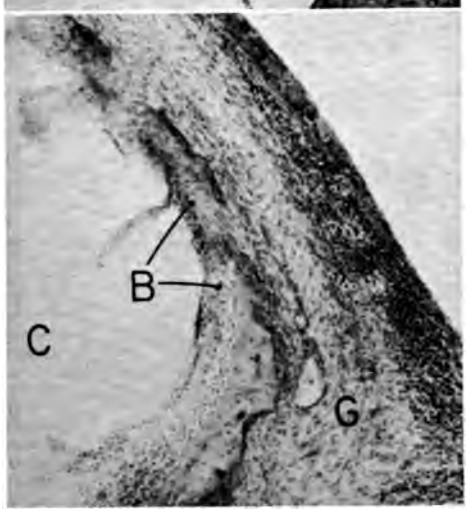

Fig. 8. Animal 7 from Group 3:A, which had talc placed on the medial aspect of the tympanic membrane (T). Granulation tissue (G) can be seen extending from the tympanic membrane (T) to the cochlea (C) producing a fistula at F. There is no evidence of suppurative otitis media. X40.

Fig. 9. Animal 7. The area outlined in brackets on Figure 8 is shown in higher magnification revealing bone resorption (B) of the cochlea (C) wall. The granulation tissue (G) contains numerous inflammatory cells but no foreign body giant cells or talc particles. X100.

media without skin and in one animal with a talc granuloma having neither skin nor otitis media.

These results show that bone resorption occurs from otitis media alone, from epidermal cysts without adjacent sepsis or pressure, and also from chronic granulomas. Bone resorption is more likely to occur, however, in association with a migrating, proliferating epidermal cyst (Table II). Typical appearing osteoclasts could not be identified at the absorbing margin. Each of the fistulas was covered by a cellular, loosely arranged connective tissue layer containing numerous fibroblasts, lymphocytes, macrophages, and capillary buds (Figs. 7, 9, and 11).

TABLE II

INCIDENCE OF BONE RESORPTION

Adjacent Tissue	*No. of Animals*		*No. of Cochlea Fistulas*
Total epidermal cyst	8		3 (38%)
With otitis media		5	2
No otitis media		3	1
Total no epidermal cyst	47		3 (6%)
with otitis media		21	2
No otitis media		26	*1
Total		55	6 (11%)

* Talc granuloma

DISCUSSION

This study has not entirely resolved the question of the relative role of sepsis in the bone resorption of chronic otitis media. The absence of exudate at the sites of bone resorption in two animals in our series (Figs. 6 and 8) might be due to sampling error. A histologic study of this type cannot rule out the possibility of a transient episode of sepsis at some time prior to the animal's death.

Otologists are often faced with the problem of if and when to operate on a dry cholesteatoma. Perhaps a dry ear is a safe ear. Histologic evidence from our study suggests that there must be an inflammatory stage at some time in the proliferation of epithelium into a bone resorbing cyst. This would not have to be septic or bacterial in origin and would not necessarily lead to perforation at the tympanic membrane and drainage even if it were due to sepsis. The crucial activity occurs at the interface with bone and not at the external aspect of the tympanic membrane.

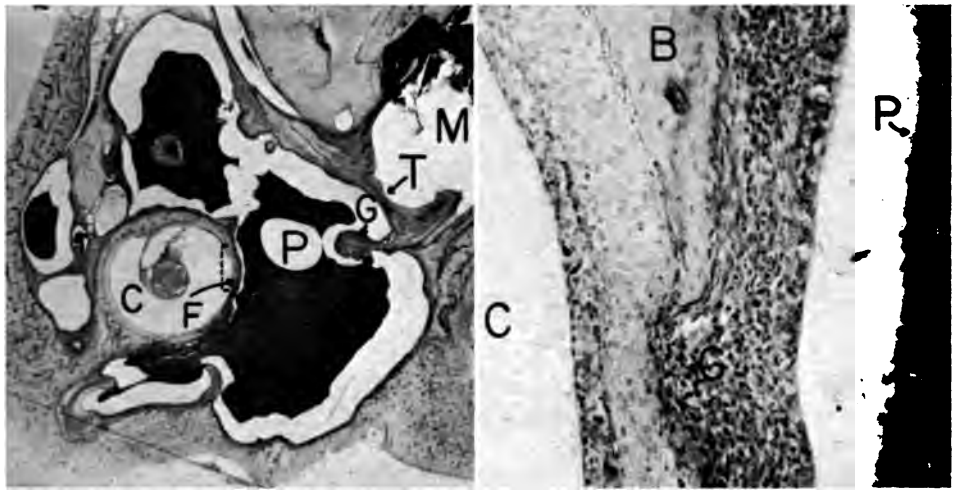

Fig. 10. Animal 7 from Group 4, showing a cochlea (C) fistula (F) secondary to sepsis in the middle ear without adjacent epidermal cysts. The external auditory meatus (M) and healed tympanic membrane (T) are shown as well as a granulomatous polyp (G) at the site of the canal skin flap. The middle ear is filled with purulent exudate (P). The middle ear and cochlea are lined with a thick granulomatous mucosa. X15.

Fig. 11. Animal 7. The area of cochlea fistula outlined in brackets in Figure 10 is shown in higher magnification. The pus cells (P) are separated from the resorbing bone (B) by a layer of cellular connective tissue (G) containing numerous capillary buds, fibroblasts, lymphocytes, and macrophages. X250.

As otologists, we tend to look at cholesteatomas in the same way that we examine a patient, from the outside in. To study bone resorption, one must look from the bone's point of view, or from the inside out. Resorbing bone is covered by a layer of loosely arranged connective tissue resembling the mesenchyme seen in embryonic development or a healing wound. This inflamed connective tissue has recently been described under bone resorbing cholesteatomas in man by Thomsen and co-workers.[12] As in our study, they were unable to find osteoclasts at the resorbing margin of bone.

The process of bone resorption is not well understood, but it is clearly an active process involving a series of events. Bone resorption can be viewed in terms of two initial stages: first, an inflammatory stage, and second, a proliferative stage. The inflammatory stimulus can be sepsis, a foreign body reaction or a migrating epithelial layer. The organism responds to these various inflammatory stimuli with a single proliferative mesenchymal reaction. This mesenchyme shares histologic features with other destructive processes. It resembles a pannus lying against resorbing articular cartilage in rheumatoid arthritis and is essentially identical with the primitive connective tissue in an invasive epidermoid carcinoma located between tumor and host. These destructive processes differ from a healing wound in the chronicity of the inflammatory stimulus and the persistence of the proliferative response.

Sadé and Halevy[13] recently recorded the effects of chronic otitis media on bone removed surgically. They point out that chronic otitis media without cholesteatoma commonly causes bone resorption. Their data show that ossicles from patients undergoing surgery for chronic otitis media without cholesteatoma had a 42.5% incidence of resorption, while ossicles from patients with cholesteatoma had an 84% incidence of resorption. This coincides with the results of our study in which the incidence of bone resorption with suppurative otitis without cholesteatoma is 10%, or 2 of 21 animals, while the inci-

dence of bone resorption with cholesteatoma is 38%, or three of eight animals. The epidermis of cholesteatoma is not simply passive but appears to play an active and significant role in bone resorption. The intercellular communication that results in bone resorption in the ear is an example of an epithelial-mesenchymal interaction. The biochemistry of this interaction is still obscure, but is the subject of current investigations in our laboratory.

Request for reprints should be sent to Maxwell Abramson, M.D., Dept. of Otolaryngology and Maxillofacial Surgery, University of Iowa Hospitals and Clinics, The University of Iowa, Iowa City, Iowa 52242.

Richard G. Asarch, M.D., is now at the Division of Dermatology, University of Colorado, Denver, Colorado. Ward B. Litton, M.D., is now located in Moline, Illinois.

ACKNOWLEDGMENT—The slides were prepared by Joan K. Schnute and Crystal Smith. The illustration was prepared by Ronald J. Ervin.

REFERENCES

1. Berberich J: Das experimentalle Mittelohrcholesteatom. Z Hals-Nas-Ohrenheilk 10: 881, 1927

2. Schroer R: Entwicklungsgeschichtliche und experimentelle Untersuchungen zur genese des Mittelohrcholesteatoms. Arch Klin Exp Ohren Nasen Kehlkopfheilkd 170:265-316, 1957

3. Dota T, Nakamura K, Saheki M, *et al*: Cholesterol granuloma. Experimental observations. Ann Otol Rhinol Laryngol 72:345-356, 1963

4. Ruedi L: Cholesteatoma formation in the middle ear in animal experiments. Acta Otolaryngol 50:233-242, 1959

5. Fernandez C, Lindsay JR: Aural cholesteatoma. Experimental observations. Laryngoscope 70:1119-1141, 1960

6. Nishiura I: Experimental studies on cholesteatoma. J Otolaryngol Jap 72:719-747, 1969

7. Friedmann I: The comparative pathology of otitis media – experimental and human. I. Experimental otitis of the guinea-pig. J Laryngol Otol 69:27-50, 1955

8. Friedmann I: The comparative pathology of otitis media – experimental and human. II. The histopathology of experimental otitis of the guinea-pig with particular reference to experimental cholesteatoma. J Laryngol Otol 69:588-601, 1955

9. Milstein T: Contribution a l'etude experimentale de la genese du cholesteatome. Acta Otolaryngol (Stockh) 25:311-327, 1937

10. Walsh TE, Covell WP, Ogura JH: The effect of cholesteatosis on bone. Ann Otol Rhinol Laryngol 60:1100-1113, 1951

11. Abramson M: Collagenolytic activity in middle ear cholesteatoma. Ann Otol Rhinol Laryngol 78:112-125, 1969

12. Thomsen J, Jorgensen MB, Bretlau P, *et al*: Bone resorption in chronic otitis media. A histological and ultrastructural study. II. Cholesteatoma. J Laryngol Otol 88:983-992, 1974

13. Sadé J, Halevy A: The aetiology of bone destruction in chronic otitis media. J Laryngol Otol 88:139-143, 1974

DISCUSSION

JUERGEN TONNDORF, M.D.: I would like to draw your attention to a paper which was published either by Rudolph Link himself in Germany or by one of his associates in the 1950's. They also used the guinea pig, but instead of employing a flap from the inferior aspect, they made use of the dual development of the external ear canal, the upper part coming from the squama and the lower one from the tympanic bone.

They interfered with the blood supply of the squamous part and then employed benzeprene as an irritant. In this way, they produced an invasion of the upper canal skin into the middle ear.

I do not think they followed up on this earlier attempt, but it seems to me that this is a promising route to try producing an active invasion.

SHIRLEY BARON, M.D. (San Francisco, California): Mr. President, I am not just sure that this can be accomplished in the guinea pig. It would be interesting to see if Dr. Abramson and his group could reproduce a situation which we perform in humans by externalizing the cholesteatoma.

If he could do this in animals and follow them for a considerable period of time, it would be interesting to see what happens to the resorption factor after a prolonged period of externalization.

I hope he can give this some consideration.

LESTER A. BROWN, M.D.: What do you mean by a considerable amount of time? What would you call a considerable amount of time?

SHIRLEY BARON, M.D.: Well, I would say in the guinea pig six months, if you can keep them alive that long – I am not conversant with this, but six months to a year.

IDIOPATHIC FACIAL PARALYSIS, PREGNANCY, AND THE MENSTRUAL CYCLE

RAYMOND L. HILSINGER, JR., M.D.

KEDAR KARIM ADOUR, M.D. H. E. DOTY

OAKLAND, CALIFORNIA

SUMMARY – The records of 42 women with Bell's palsy during pregnancy, and of 91 nonpregnant women, whose dates of onset of Bell's palsy and of the preceding menstrual cycle were precisely known, were studied for factors that might show relation between pregnancy or the menstrual cycle and Bell's palsy. Of the 42 cases in pregnancy, 31 occurred in the third trimester, five in the first two weeks postpartum, and six in the first two trimesters combined. Our calculated frequency of Bell's palsy in pregnant women is 45.1/100,000 births; for nonpregnant women of the same age group the calculated incidence is 17.4/100,000 per year. No causative relation was found between toxemia, hypertension or primigravidity, and Bell's palsy. Over 60% of the cases in nonpregnant women occurred in the first 14 days of the menstrual cycle with peaks on the first and seventh days and near ovulation. No clear evidence for an etiologic relationship was seen with edema or hormonal changes in either pregnancy or the menstrual cycle. A number of factors in pregnancy and the menstrual cycle suggested an etiologic role for herpes simplex virus reactivation in Bell's palsy. There was no evidence that prednisone treatment is contraindicated during pregnancy.

In 1830, Bell alluded to the possible association of pregnancy with paralysis of the facial muscles.[1] Since that time, several unsuccessful attempts have been made to establish or refute a definite relationship between idiopathic facial paralysis (Bell's palsy) and pregnancy.[2-15] Although none of the authors felt that their reports showed a statistically valid association, they hoped that their articles would point out the need for further study in this area.[5-7,10,11,14,15]

Reports of large series of patients with facial paralysis have shown a slightly greater overall incidence in females than in males;[16-20] and between the ages of 10 and 20 years, the female is two to four times more likely to contract Bell's palsy than is her male counterpart.[16,18,20] After age 50, women are less likely than men to have the disease.[16,18,20] In El-Ebiary's patients,[20] recurrence was twice as common in females as in males; he offered the interesting suggestion that premenstrual water retention might be a predisposing factor.

Although these facts suggest a relationship between Bell's palsy, menarche and menopause, and pregnancy, we have seen no published effort to analyze incidence statistics in the light of a potential link between Bell's palsy and the menstrual cycle. This article examines those relationships.

METHODS AND MATERIALS

The patients were members of the Kaiser Foundation Health Plan, a prepaid health care program which has approximately one million subscribers in Northern California. While devoid of the indigent and extremely wealthy, the characteristics of this population, including its age-sex distribution, compare closely to a

From the Facial Paralysis Research Clinic, Department of Otolaryngology, Kaiser Permanente Medical Center, Oakland, Calif.

Supported by the Community Service Program of the Kaiser Foundation Hospitals.

TABLE I

FACIAL PARALYSIS RECOVERY PROFILE

Site	No. of Points Assigned to Each Unit of Recovery*				
	0	0%-25%	25%-50%	50%-75%	75%-100%
Forehead	0	+1	+1	+2	+2
Eye	0	+1	+2	+3	+4
Mouth	0	+1	+2	+3	+4

* Return of facial function measured in units of 25%.

cross section of the population of California, and probably of the United States as a whole. All patients with facial paralysis seen in the ten Northern California Kaiser Permanente Medical Centers in the San Francisco Bay area (the center in Sacramento, at a greater distance, is excluded) are evaluated in the Facial Paralysis Research Clinic of the Department of Otolaryngology in the Oakland facility. Each patient receives our standard workup, which has been outlined in previous publications.[17,21]

Pregnancy. To facilitate precise statistical comparison of incidence figures, we selected a three-year period (1969-1972) during which the number, age and sex distribution, the number of births in these medical centers, and the number of cases of idiopathic facial paralysis were known. For the total study, we included the 53 pregnant women, with facial paralysis from any cause, who were seen between 1966 and 1974. Among these 53 cases of facial paralysis, one each resulted from acute otitis media, a central nervous system (CNS) disease (hemiplegic migraine), and mumps; eight resulted from herpes zoster oticus. The remaining 42 cases were considered to be idiopathic. These 42 women ranged in age from 16 to 40 years; their average age was 25.3 years.

Menstruation. In 91 women, the exact dates of onset, both of the idiopathic facial paralysis and of the preceding menstrual period, were known. Any case in which these data were ambiguous, or the menstrual cycle was longer than 40 days, was excluded from this consideration. Because our early records did not routinely include the precise date of onset of menstruation, this is not a consecutive list of cases. We now record the onset, duration, and periodicity of the menstrual cycle and the use and type of birth control pills.

The 91 cases were analyzed as to symptomatology, physical findings, treatment, and recovery from facial paralysis. The final means of assessing outcome was the previously described[17,21] Facial Paralysis Recovery Profile (FPRP) and the Facial Paralysis Recovery Index (FPRI). The FPRP is a simple, accurate, reproducible method of assessing the degree of return of function in the region of forehead, eye, and mouth, and of cosmetic result (Table I). Possible scores range from 0 to +10, equating with 0 to 100% recovery of facial function: a FPRP score of +5 equals 50% recovery of muscle motion; +7 equals 70% recovery. The FPRI takes into consideration the negative effect of complications of the facial paralysis on the final result. Contracture, synkinesis, facial spasm, gustatory tears, and ptosis of the eyebrow are each assigned one minus point and the total is then subtracted from the final FPRP. Consequently, a FPRP of +9 and a FPRI of +7 means 90% return of facial function with two complications.

FINDINGS

Of the 446 cases of idiopathic facial paralysis seen during 1969-1972, 234 (52%) were in women; 138 (31%) of the cases were in women of the childbearing age (15-39 years). Our calculated overall incidence of idiopathic facial paralysis in women is 16.9/100,000 per year; in women of the childbearing age, the incidence is 17.4/100,000 per year.

Pregnancy. During the same three years, 37,655 births occurred in our health plan population, and we saw 17 cases of idiopathic facial paralysis among those pregnant women. Thirteen of the 17 cases occurred during the third trimester or within the first two weeks postpartum. Thus, the frequency of idiopathic facial paralysis in pregnant women was 45.1/100,000 births. Per year of exposure, the risk to pregnant women was 3.3 times the risk to nonpregnant women of the same age group. Assuming 14 weeks for each trimester plus two weeks postpartum, the incidence for the third trimester and early puerperium alone is 118.2/100,000 per year of exposure.

Of the 42 cases of Bell's palsy seen in pregnant women over the longer period 1966-1974, 31 occurred in the third trimester, five in the early puerperium, and only six in the first two trimesters combined. Two of the 42 women had toxemia of pregnancy, described in one instance as a mild case of preeclampsia. There were no instances of hypertension due to other causes.

Statistics from the entire health plan population in this area for 1960-1966 showed that 29.7% of all mothers who delivered were primigravidas. Among the 42 women with Bell's palsy in pregnancy, 15 (35.7%) were primigravidas. Obviously, no statistical comparison can be made between these data from disparate timespans; but the risk of Bell's palsy does not appear to be greater in the first than in subsequent pregnancies.

Twenty-six of the 42 pregnant women with Bell's palsy received prednisone starting with 40-60 mg daily and tapering to zero in 8-10 days. Fourteen of the 16 who did not receive prednisone were seen between 1967 and 1969. All but two of the patients seen since 1970 have been treated with prednisone.

Thirty-one of the overall total had long-term follow-up. Their average FPRP was +9.74; their average FPRI, +9.16. Seven of the eight mothers with herpes zoster facial paralysis had adequate follow-up. Their average FPRP was +8.6; their average FPRI, +7. The average FPRP for the 23 prednisone-treated patients with long-term follow-up was +10; their average FPRI was +9.43. Only six of 12 untreated mothers had significant follow-up; their FPRPs and FPRIs both averaged +9.83. Two patients originally in the untreated group developed partial denervation and underwent decompression of the vertical segment of the facial nerve. Their eventual FPRPs were +10 and +3; their final FPRIs, +8 and 0. Contracture and synkinesis developed in both; facial spasm, in one. None of the other untreated patients had these complications. Five of the prednisone-treated group had contracture and synkinesis; two of these had, in addition, facial spasm. Three of the five with these complications were treated with 40 mg of prednisone on the first day of palsy, rather than the 60 mg we use now. Three of the five cases of contracture and synkinesis were minimal and were unnoticeable to the patient.

Three of the prednisone-treated group without long-term follow-up had an average FPRI of +5 when last seen. One of the three had contracture and synkinesis and an FPRI of 0. Her prednisone had been discontinued by another physician after one day of therapy (40 mg). Severe occipital pain recurred. When she was retested three days later, there was complete loss of nerve excitability (complete denervation), whereupon prednisone was restarted. This was the only pregnant woman with Bell's palsy in this series in whom complete denervation developed. If her score is excluded from the group, the average FPRI of the three prednisone-treated patients with incomplete follow-up, when last seen, was +7.5. The six untreated patients who had inadequate follow-up had an average FPRI of +6.3 when last seen.

Effects on Infants. Twenty of the infants of mothers with Bell's palsy were male, 22 female. In 100 consecutive births at the Oakland facility during January-February 1975, the average one-minute Apgar score of infants was 8.4. The one-minute Apgar scores of 40 infants delivered to mothers with Bell's palsy are known; these averaged 9.0, ranging from 10.0 in 18 infants to 5.0 in two infants. The Apgar scores of infants of the 11 mothers with facial paralysis of demonstrable cause averaged 8.55. The Apgar scores of the infants of 25 of 26 women with Bell's palsy who received prednisone are known; they averaged 8.88. Adding the Apgar scores of six infants of mothers with herpes zoster facial paralysis treated with prednisone, the average for the 31 infants in the prednisone-treated group was 8.7. There were no complications before or during childbirth, or during the neonatal hospitaliza-

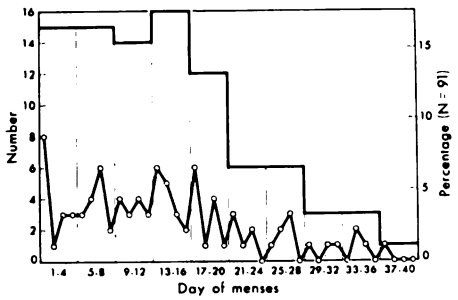

Fig. 1. Number of cases of Bell's palsy occurring each day after onset of menses in 91 women. Bar graph (4-day intervals) shows that the vast majority of cases occur during the first half of the cycle.

tion, that were related to prednisone therapy.

Menstruation. The entire group of 91 menstrual women included seven whose cycles were as long as 37 days; in 84, the cycle was 28 days. The number of cases of Bell's palsy occurring on each day after onset of menstruation in the 91 women is shown in Figure 1. The rate is highest on the first menstrual day; secondary peaks of incidence are seen on the seventh, thirteenth, fourteenth, and seventeenth day of the cycle. Although 60.4% of the cases in the total group occurred within the first 14 days of the menstrual cycle, among the 84 women with a 28-day cycle, 65.5% of the cases occurred within the first half of the cycle.

The presenting signs and symptoms seen in these 91 women — ageusia, epiphora, pain, and subjectively or objectively decreased tearing — were similar in incidence to those in a general population with idiopathic facial paralysis. Except that hyperacusis, which indicates more widespread disease, was somewhat more frequent among these patients than in a general population with Bell's palsy, the eventual FPRPs of the 91 patients were similar to those generally seen.

DISCUSSION

Nerve Disease in Pregnancy. Altered body needs as well as changed hormonal, fluid, and electrolyte levels are among the factors thought to contribute to the presence of neurologic abnormalities during gestation.[22,23] Of the many possible neurologic complications of pregnancy, peripheral mononeuropathy has not been considered common.[10,22,23] Vascular disorders of the brain and spinal cord, chorea, and polyneuritis are linked with pregnancy, as is the tendency to exacerbation or aggravation of chronic neurologic diseases.[10]

The peripheral nerve diseases most commonly associated with pregnancy are brachial neuralgia, disease of the lumbosacral plexus and nerves, or peripheral polyneuritis.[23] A possible complication is the carpal tunnel syndrome. While its cause is not known,[10,22,23] it has been suggested that hormonal alterations of pregnancy[22] lead to an increase in the volume of the content of the carpal tunnel canal. Ischemia of the compressed nerve is believed to cause paresthesias and sensory disturbance, weakness, and atrophy of the abductor pollicis brevis and opponens pollicis muscles. Treatment is conservative, in expectation of complete postpartum recovery. A case of oculomotor palsy in pregnancy, with a similar course, has also been described.[10]

This report adds idiopathic facial paralysis to the list of pregnancy-related diseases. Women are at an increased risk of Bell's palsy when pregnant, particularly in the third trimester. Why this is true and what changes occur in pregnancy that account for this increased risk are not known.

Toxemia and Facial Palsy. While no statistical analysis has appeared of a possible relation between facial paralysis and toxemia of pregnancy, three authors have suggested that toxemia might be an etiologic factor in the development of facial palsy.[5,9,11] Mild elevation of blood pressure or toxemia of pregnancy was observed in 45% and 60% of two series: the 20 patients reported by Pope and Kenan[5] and the 15 reported by Robinson and Pou.[11] Gerber and Collins[9] and Bezjian, Spellacy, and Little[8] noted single cases of preeclampsia with Bell's palsy. A review of Ed-

wards'[3] study shows that three of the 11 pregnant women with facial palsy had hypertension.

The high incidence of toxemia noted by some of these authors[3,5,11] may have been due to a selection factor since their cases were collected in the southeastern United States. Fifteen of the total of 20 cases of Bell's palsy in women with mild to severe toxemia reported by them were in Negroes. The incidence of toxemia has been believed to be related to socioeconomic factors, and has been shown to be comparatively high in the Negro population and in the southeastern United States.[22-25] During 1960-1966, 22.7% of the total deliveries to members of our Health Plan in Northern California were to Negro women; and subscribers to this plan are employed persons and their dependents. Two of the women with Bell's palsy in the present series had toxemia in pregnancy; one was Negro, the other Mexican-American. No statistical relationship exists between toxemia and idiopathic facial paralysis of pregnancy.

Hypertension and Facial Palsy. Hypertension as a cause of isolated facial nerve palsy was first reported in a single patient by Moxon in 1869;[26] no statistical analysis of a possible relation between these entities has appeared. Merwarth[27] published 24 cases of peripheral facial paralysis associated with hypertensive vascular disease: in 16 of the patients the facial paralysis was considered to be a direct result of the hypertensive disease; in the remainder it was believed to be Bell's palsy with coexisting hypertension. Clarke and Murphy[28] saw seven cases of unilateral facial (and one of abducens) nerve palsy among 79 patients with malignant hypertension involving the nervous system. Lloyd, Jewitt, and Still,[29] reviewing 35 cases of severe hypertension in children, noted that six of the patients had had single or multiple episodes of unilateral peripheral facial paralysis. In 1966, an editorial in the *British Medical Journal* on facial paralysis in hypertension called attention to the "well-documented association between lower motor neurone facial paralysis and severe hypertension."[30] Miller[31] commented on the relation between facial paralysis and both severe hypertension and toxemia of pregnancy. Adour and Wingerd[32] noted that hypertension was one of several prognostic indicators in Bell's palsy and that patients with hypertension were therefore overrepresented in series of cases of Bell's palsy from hospital and specialty clinic populations, leading to a false impression of causality. No significant relation was seen between facial paralysis and hypertension in the present series.

Gravidity and Facial Paralysis. No evidence for a significant relation between facial paralysis and the occurrence or nonoccurrence of previous pregnancy was seen in this study: 29.7% of Health Plan members delivering at a given time and 35.7% of mothers with Bell's palsy were primigravidas. It has been suggested[10] that primigravidas tend to contract Bell's palsy in the last week of gestation. In our series, only two of 15 primigravidas contracted the palsy during the last week of pregnancy; in an additional three of the 15, the onset occurred during the penultimate week. In four multiparas, Bell's palsy had its onset during the last week; in five, during the penultimate week.

EDEMA HYPOTHESIS

The first of two widely considered hypotheses for the causation of Bell's palsy is that a vasospastic response leads to edema and mechanical compression of the facial nerve in the fallopian canal resulting in paralysis.[33,34]

Pregnancy. A suggestion which has gained increasing acceptance is that the edema of pregnancy[7,8,10] is a secondary or even the primary factor leading to Bell's palsy in pregnant women. Mair, Elverland, and Johannessen,[15] however, concluded that tissue edema is not the cause of idiopathic facial paralysis, on the grounds that no association had been observed between facial paralysis and tissue edema due to other states, notably the use of oral contraceptives, or second or subsequent pregnancies. They also noted that there had not been

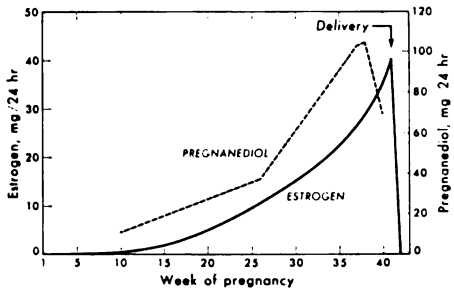

Fig. 2. Urinary excretion of pregnanediol and estrogen during pregnancy.

an increase in recurrence of facial paralysis in the Melkersson-Rosenthal syndrome with pregnancy.

Water retention is, indeed, an integral part of pregnancy. Early in gestation, plasma volume increases faster than extracellular fluid; this relation reverses about 80 days before labor, when a marked increase in the interstitial fluid volume occurs, augmented by a prelabor decrease in plasma volume. After delivery, plasma volume diminishes rapidly but the interstitial fluid volume returns only slowly to normal. The increased incidence of facial paralysis in pregnancy and the early postpartum period certainly coincides with the curve of interstitial fluid volume, but whether and how the fluid volume might sensitize the facial nerve is not clear.

Menstrual Cycle Edema. It has also been proposed[20] that the edema of the premenstrual period, although considerably less than that of pregnancy, is a primary or secondary cause of Bell's palsy. In the menstrual cycle, edema begins with ovulation and continues until the onset of menses. If edema, related or not to vasospasm, were the primary or secondary cause of Bell's palsy one would expect the incidence of the disease to increase after day 14 of the cycle. Two-thirds of the cases of facial paralysis in the nonpregnant women of the present series occurred during the first 14 days after the onset of menses.

HORMONAL CHANGES

During Pregnancy. Bezjian and co-

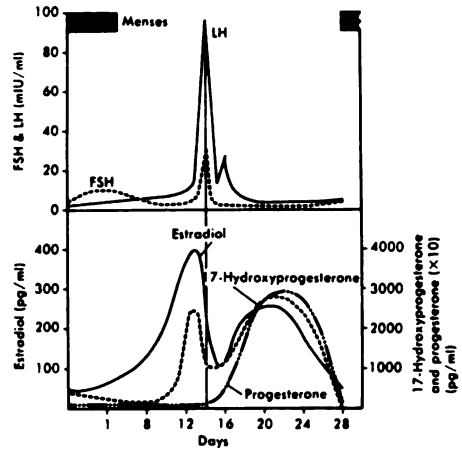

Fig. 3. Schema of the fluctuations in serum luteinizing hormone (LH), follicle stimulating hormone (FSH), progesterone, 17-hydroxyprogesterone, and estradiol during the normal menstrual cycle. (Reproduced by permission from Odell WD, Moyer DL: *Physiology of Reproduction*, St. Louis, The C. V. Mosby Company, 1971, p 66, Fig 5-2.)

workers[8] and Korczyn[10] speculated that the rise of incidence of Bell's palsy late in pregnancy reflects hormonal increases with length of gestation. The hormones that increase during pregnancy are predominantly progesterone and estrogen (Fig. 2). These are measured in the urine as pregnanediol, the major known urinary metabolite of progesterone, and as estrogen. Both peak in the last trimester, as does the incidence of Bell's palsy in pregnant women. While estrogen remains high until the end of pregnancy, however, progesterone starts to fall shortly before delivery. To determine whether the levels of these hormones or changes in them are related to the occurrence of Bell's palsy, it would be necessary to make serial hormone determinations in pregnant women with and without idiopathic facial paralysis.

During the Menstrual Cycle. There was no apparent correlation between the hormonal changes that characterize the phases of the menstrual cycle and the observed higher incidence of Bell's palsy during the first half of the cycle of the women in this series (Fig. 3).

Follicle-stimulating hormone (FSH) increases early in the cycle and stimulates release of estradiol and 17-hydroxyprogesterone, which rise to a peak just before ovulation. The estradiol causes release of luteinizing hormone (LH) (Fig. 3) and to a lesser degree, of FSH; these induce ovulation and formation of the corpus luteum. Progesterone is then secreted in progressively larger amounts, peaking in the second half of the cycle together with estradiol and 17-hydroxyprogesterone, which rise after a postovulatory dip to attain a second peak in the midluteal phase. If the ovum is not fertilized, all three diminish and menstruation results.[24,25,35] Although the incidence of Bell's palsy in the women of this series showed peaks around the time of ovulation, no gonadotrophic hormone is at a high level at the onset of menses. These events may also cast doubt on the possible etiologic relation of hormones to facial paralysis in pregnancy.

VIRAL HYPOTHESIS

The second major hypothesis for the causation of Bell's palsy suggests a viral inflammatory reaction with subsequent demyelinization.[36-41] Mumps, rubella, and herpes simplex have been suggested as possible etiologic agents.[36,39,41] Herpes zoster is an accepted cause of facial paralysis;[41] it was the etiologic agent in eight of the pregnant women in our total series.

Naib and coworkers[42] have demonstrated that the incidence of herpes simplex virus in pregnant women is higher than in nonpregnant women. Herpes simplex virus can be reactivated by upper respiratory tract infection, a cold draft, exposure to ultraviolet rays or sunlight, emotional upsets, dental extraction, or menstruation.[41,43] Most recently, this virus has been implicated in Bell's palsy.[39,41] Gestational immunosuppression,[44] induced by the steady rise in cortisol levels through each trimester, is believed to be the stimulus for reactivation of the virus in pregnancy. That herpes simplex is reactivated by menstruation and by body temperature elevation may explain the cluster of cases of Bell's palsy that we noted on the first day of the menstrual cycle, towards the end of menstruation, and at or around the ovulation date when body temperature rises temporarily. Further confirmation of these peaks will be needed with a larger series and a consecutive list of cases.

The consideration that 100% of patients with Bell's palsy have evidence of previous infection with herpes simplex virus[41] lends very believable support to the viral hypothesis for causation of this disease. Furthermore, support for the viral hypothesis comes from factors extraneous to pregnancy and menstruation: Bell's palsy is not a unilateral mononeuropathy of the facial nerve in the fallopian canal; it is a cranial polyneuritis involving the sensory and motor branches of the trigeminal nerve, the acoustic-vestibular nerve, the glossopharyngeal nerve, and often the clinically uninvolved contralateral facial nerve. In some cases, CSF shows increased protein, lymphocytic pleocytosis, or both.[45-48]

Thus, if we were to select a hypothesis for the cause of Bell's palsy that fits the clinical picture, we would have to choose the viral rather than the vasospasm-edema concept.

PREDNISONE THERAPY OF BELL'S PALSY

During Pregnancy. Treatment of idiopathic facial paralysis has varied in pregnant women as it has in the general population. Some authors have advised symptomatic treatment only, since they feel that Bell's palsy in the last month of pregnancy is a relatively innocuous disease, which will resolve shortly after delivery of the infant.[4,10] Surgical decompression under local or general anesthesia has been advised.[5,7,11,49-51] One observer has encouraged induction of delivery early in the last week of pregnancy for women with facial paralysis to allow for facial nerve decompression under general anesthesia.[50]

The use of prednisone in pregnant women has been controversial in view of possible detrimental effects on the embryo and fetus.[4,8] Occasional reports

of adrenal insufficiency in infants whose mothers have received steroids has increased the reluctance of many physicians to use these substances.[52] Recent work has shown that the placenta oxidizes the majority of the biologically active glucocorticoids to their corresponding ketones, which are probably inactive.[53] Beitins and coworkers[53] demonstrated that fetal levels of trihydroxyprednisone and trihydroxyprednisolone are nearly equal to one another and are exceeded eight- to tenfold by maternal trihydroxyprednisolone concentration. Consequently, there is very little likelihood that prednisone, even if given in high concentration, will have an adverse effect on the fetus. None of the 31 infants of mothers in our total series who had received prednisone for facial palsy due to any cause had any complications believed to be associated with this agent; the infants' average one-minute Apgar score was 8.7. Recovery of facial function in the vast majority of these women has been excellent: in 93.5% of those who had Bell's palsy while pregnant, the FPRP was +10. Consequently, we believe that in the pregnant woman as in other patients, prednisone is the treatment of choice for Bell's palsy. We have seen no evidence to support surgical intervention for idiopathic facial paralysis whether or not the patient is pregnant.

That the FPRP and FPRI scores for the treated (+10/+9.43) and the untreated (+9.8/+9.8) pregnant women in this series should be so nearly identical is most interesting, since in our general patient population, the average outcomes for untreated Bell's palsy are FPRP 8.96; FPRI 8.02. There may be some selection factor since these groups were from different timespans (the untreated women were seen between 1967 and 1969; the treated, between 1970 and 1974), and six of our 12 untreated pregnant women were lost to follow-up. However, the difference in timespan is also true of the treated and untreated groups in our general population. When last seen, the FPRI scores of four of the six untreated women were +7, +8, +9, and +10; in the other two, these scores were +1 and +3.

In pregnancy, a dichotomous situation exists in which the high levels of circulating cortisol are immunosuppressant, while at the same time they reduce inflammatory response. It is well known that inflammatory reaction in other diseases is reduced during pregnancy; rheumatoid arthritis, severe dermatologic conditions, and allergic states tend to be in remission in the last trimester. It may be that the high levels of cortisol in the pregnant woman give her a better chance for successful recovery from Bell's palsy without prednisone treatment. The fact that all of the pregnant women in our series who had contracture, synkinesis, and facial spasm were in the third trimester at the time they contracted Bell's palsy may, however, negate this hypothesis.

The effects of prednisone on the embryo and fetus during the first trimester are unknown. Four of our patients received prednisone during the first or second trimester; none had complications of pregnancy and each delivered a normal infant. We know that the therapeutic addition of 40-60 mg of prednisone daily affects the natural course of Bell's palsy, even in pregnancy. Occipital (postauricular) pain subsided 12-24 hours after treatment was started in these patients. Abrupt cessation of treatment in one led to recurrence of occipital pain. Because of this known effect, we elect to treat women who have Bell's palsy in the second and third trimester. We are probably overtreating some, even in giving them prednisone. Further work is needed to determine which mothers will and which will not benefit from prednisone. We now give 60 mg in divided doses for the first few days, and taper to 5 mg at the end of ten days. If postauricular pain recurs, or if partial denervation is suggested by a rise in the nerve excitability threshold

as determined by comparison with the opposite side, the dose is raised to 60 mg. Since the active disease process seems to be resolved within two weeks, we do not believe prednisone treatment is needed beyond 21 days.

Request for reprints should be sent to Dr. Raymond L. Hilsinger, Jr., Kaiser Permanente Medical Center, 280 West MacArthur Boulevard, Oakland, California 94611.

REFERENCES

1. Bell C: *The Nervous System of the Human Body.* London: Longman, Rees, Orme, Brown, and Green; J. Taylor, 1830, Appendix pp iv-v

2. Faris BD: Facial paralysis during pregnancy. Med Times 83:185, 1955

3. Edwards CE: Bell's palsy in the last trimester of pregnancy and the puerperium. Am J Obstet Gynecol 89:274-276, 1964

4. Smith PN, Newton M: Bell's palsy in pregnancy. Obstet Gynecol 30:134-136, 1967

5. Pope TH, Kenan PD: Bell's palsy in pregnancy. Arch Otolaryngol 89:52-56, 1969

6. Adour KK: Bell's palsy (letter to the Editor). Arch Otolaryngol 91:310, 1970

7. Pope TH, Kenan PD: Reply [to Adour[6]]. Arch Otolaryngol 91:310-311, 1970

8. Bezjian AA, Spellacy WN, Little WA: Idiopathic Bell's palsy in pregnancy. Florida Med Assoc J 57:25-27, 1970

9. Gerber AH, Collins MJ: A case of preeclampsia with Bell's palsy and concomitant fetal anomalies. Med Ann DC 40:317-319, 1971

10. Korczyn AD: Bell's palsy and pregnancy. Acta Neurol Scand 47:603-607, 1971

11. Robinson JD, Pou JN: Bell's palsy; a predisposition of pregnant women. Arch Otolaryngol 95:125-129, 1972

12. Levy AH: Bell's palsy (letter to Editor). Arch Otolaryngol 95:192, 1972

13. Donaldson JA: Reply; Donaldson on Robinson. Arch Otolaryngol 95:192-193, 1972

14. Robinson JR, Pou JW: Reply to Levy and Donaldson. Arch Otolaryngol 95:193, 1972

15. Mair IWS, Elverland HH, Johannessen TA: Idiopathic facial palsy and pregnancy. Ann Otol Rhinol Laryngol 82:235-239, 1973

16. Hauser WA, Karnes WE, Annis J, *et al*: Incidence and prognosis of Bell's palsy in the population of Rochester, Minnesota. Mayo Clin Proc 46:258-264, 1971

17. Adour KK, Swanson PJ Jr: Facial paralysis in 403 consecutive patients. Emphasis on treatment response in patients with Bell's palsy. Trans Am Acad Ophthalmol Otolaryngol 75:1284-1301, 1971

18. Adour KK, Bell DN, Wingerd J: Bell palsy. Dilemma of diabetes mellitus. Arch Otolaryngol 99:114-117, 1974

19. Waterman GA: Facial paralysis: a study of three hundred and thirty-five cases. J Nerv Ment Dis 36:65-76, 1909

20. El-Ebiary HM: Facial paralysis: a clinical study of 580 cases. Rheumatol Phys Med 11:100-110, 1971

21. Manning JJ,, Adour KK: Facial paralysis in children. Pediatrics 49:102-109, 1972

22. Haynes DM: *Medical Complications during Pregnancy.* New York, McGraw-Hill, 1969, pp 225-301

23. Krieger HP: Neurologic complications, in Rovinsky JJ, Guttmacher AF (eds): *Medical, Surgical, and Gynecologic Complications of Pregnancy*, edition 2. Baltimore, The Williams & Wilkins Company, 1965, pp 418-452

24. Wilson JR, Beecham CT, Carrington ER: *Obstetrics and Gynecology.* St. Louis, The C. V. Mosby Company, 1966, pp 59-71, 236-262, 281-288, 349-360

25. Reid DE, Ryan KJ, Benirschke K: *Principles and Management of Human Reproduction.* Philadelphia, W. B. Saunders Company, 1972, pp 7-16, 16-22, 110-123, 221-249, 335-361, 745-769

26. Moxon: Apoplexy into canal of Fallopius in a case of Bright's disease, causing facial paralysis. Trans Pathol Soc London 20: 420-421, 1869

27. Merwarth HR: The occurrence of peripheral facial paralysis in hypertensive vascular disease. Ann Intern Med 17:298-307, 1942

28. Clarke E, Murphy EA: Neurological manifestations of malignant hypertension. Br Med J 2:1319-1326, 1956

29. Lloyd AVC, Jewitt DE, Still JDL: Facial paralysis in children with hypertension. Arch Dis Child 41:292-294, 1966

30. Editorial: Facial paralysis in hypertension. Br Med J 2:1547, 1966

31. Miller H: Facial paralysis. Br Med J 3:815-819, 1967

32. Adour KK, Wingerd J: Idiopathic facial paralysis (Bell's palsy): factors affecting severity and outcome in 446 patients. Neurology 24:1112-1116, 1974

33. Hilger JA: The nature of Bell's palsy. Laryngoscope 59: 228-235, 1949

34. Blunt JM: The possible role of vascular changes in the aetiology of Bell's palsy. J Laryngol Otol 70:701-703, 1956

35. Swerdloff RS (moderator), Odell WD, Bray GA, *et al*: Complications of oral contraceptive agents – a symposium. West J Med 122::20-49, 1975

36. Saunders WH, Lippy WH: Sudden deafness and Bell's palsy: a common cause. Ann Otol Rhinol Laryngol 86:830-837, 1959

37. Saunders WH: Viral infections and cranial nerve paralysis. Arch Otolaryngol 78: 101-106, 1963

38. Schuring A, Saunders WH: Facial diplegia, a viral disease? Arch Otolaryngol 80: 103-105, 1964

39. McCormick DP: Herpes-simplex virus as a cause of Bell's palsy. Lancet 2:937-938, 1972

40. Adour KK, Doty HE: Electronystagmographic comparison of acute idiopathic and herpes zoster facial paralysis. Laryngoscope 83:2029-2034, 1973

41. Adour KK, Bell DN, Hilsinger RL Jr: Herpes simplex virus as causative agent in idiopathic facial paralysis (Bell palsy). JAMA. To be published

42. Naib ZM, Nahmias AJ, Josey WE, *et al*: Relation of cytohistopathology of genital herpesvirus infection to cervical anaplasia. Cancer Res 33:1452-1463, 1973

43. Nahmias AJ, Roizman B: Infection with herpes-simplex viruses 1 and 2. N Engl J Med 289:781-789,1973

44. Jewett JF: Herpes simplex encephalitis. N Engl J Med 292:531, 1975

45. Hopf HC: Electromyographic study on so-called mononeuritis. Arch Neurol 9:113-118, 1963

46. Safman BL: Bilateral pathology in Bell's palsy. Arch Otolaryngol 93:55-57, 1971

47. Chaco J: Subclinical peripheral nerve involvement in unilateral Bell's palsy. Am J Phys Med 52:195-197, 1973

48. McNair Scott TF, Tokumaru T: The herpesvirus group, in Horsfall FL Jr, Tamm I (eds): *Viral and Rickettsial Infections of Man*, edition 4. Philadelphia, J. B. Lippincott Company, 1965, pp 892-903

49. Glasscock ME III: [Bell's palsy in pregnancy]. Collected letters. Int Corresp Soc Ophthalmol Otolaryngol 19:42, 1974

50. Pulec JL: Collected letters. Int Corresp Soc Ophthalmol Otolaryngol 19:42-43, 1974

51. Elliott DC: Collected letters. Int Corresp Soc Ophthalmol Otolaryngol 19:43-44, 1974

52. Grimm G (Question), Villee DB (Answer): What risk to fetus from maternal steroid therapy. JAMA 230:1202, 1974

53. Beitins IZ, Bayard F, Anees IG, *et al*: The transplacental passage of prednisone and prednisolone in pregnancy near term. J Pediatr 81:936-945, 1972

DISCUSSION

ROBERT J. RUBEN, M.D. (Bronx, New York): I feel the authors have done a very valuable service in further elucidating some of the epidemiology in this syndrome complex.

However, my comments come from the use of prednisone or any steroid in women who are pregnant. The animal experiments are quite clear-cut that this is a very real inducing agent for cleft palate and clinically there is a modest suspicion that women in first trimester with steroids seem to have a somewhat higher incidence of cleft palate in children.

Again the admonition to use in the second and third trimester, I think one would have to be somewhat reserved, especially with some of the other data we have seen over the last few days that placebo may do just as well.

JACK W. POU, M.D. (Shreveport, Louisiana): Several years ago, we reported a paper on the same subject from Shreveport but we did not have the statistics that Dr. Hilsinger had. We just realized that a large percentage of our patients we were finding as candidates for facial nerve decompression, were pregnant in their third trimester, or immediately in the postpartum area.

In fact, we had one that was at term that had bilateral Bell's palsy. We have a school where we do decompress when the nerve excitability test indicates, so we induced this patient and did a bilateral facial nerve decompression.

We did not have the statistics but we certainly agree with Dr. Hilsinger's opinion on this.

INNERVATION OF THE COCHLEA OF THE GUINEA PIG BY USE OF THE GOLGI STAIN

CATHERINE A. SMITH, PH.D.

PORTLAND, OREGON

SUMMARY – Nerve fibers with distinctive branching patterns have been demonstrated in guinea pigs by use of the Golgi stain. The cochlear nerve fibers in the basal turn tend to supply a limited segment of the basilar membrane and have most endings on a single row of hair cells. The efferent olivocochlear nerve fibers ramify in a manner which varies from base to apex. Some efferents which terminate on outer hair cells also give branches which course in the inner spiral bundle. Other nerve fibers were studied in the spiral lamina which did not penetrate into the organ of Corti.

Our first study on the terminal branching of the cochlear nerve fibers in the guinea pig after use of the Golgi method, reported in 1973,[1] gave preliminary evidence for distinctive branching patterns of both cochlear nerve dendrites and efferent nerve axons. In later studies,[2] we confirmed our assumption that some of the more apical cochlear nerve fibers supply a larger segment of basilar membrane than do the basal fibers, by means of electron microscopy. Since that time, more observations have been made on a larger number of newborn guinea pigs. A résumé of our present results is presented in this study. This is not to be considered the final story, for there is enough variation in terminal ramification to make it necessary that more observations be made before final conclusions can be reached.

METHODS AND MATERIALS

Thirty-six guinea pigs were used in this study. Eighteen of them were adults; 18 were newborns, sacrificed at times ranging from 4-36 hours postpartum. The ears from 34 animals were fixed by intralabyrinthine perfusion and impregnated as previously described.[1] The rapid Golgi method as given by Valverde[3] was used throughout.

The ears from one newborn were fixed with Dalton's 1% OsO_4 while the animal was under anesthesia, by our standard method of labyrinthine perfusion,[4] and embedded in araldite for electron microscopy. The cochleas from another newborn guinea pig were incubated and stained for acetylcholinesterase with the technique given by Karnovsky,[5] and used by Takasaka and Smith[6] for the pigeon's basilar papilla.

After impregnation or staining was complete, in all the animals except those prepared for electron microscopy, the bony otic capsule was removed from each cochlea. The entire organ of Corti was dissected free from the modiolus and mounted on slides for study.

Camera lucida drawings were made either with a 40x high-dry, or 50x or 100x oil-immersion lenses and 10x or 15x eyepieces. Photographs were taken with Panatomic X or Ektachrome X film.* The fibers were studied by either a Wild** or Zeiss*** microscope, the latter being equipped with Nomarski-interference optics.

After the above preparations were completed, some specimens were floated free of the slide and cover-slip by overnight soaking in xylene. They were embedded in araldite, using toluene as an intermediary agent. Serial sections were made of the nerve fibers previ-

---

* Eastman Kodak Co., Rochester, N.Y.

** Wild Heerbrugg Instruments, Inc., Farmingdale, N.Y.

*** Carl Zeiss, Inc., N.Y., N.Y.

From the Department of Otolaryngology, University of Oregon Health Science Center, Portland.

Supported by PHS Grant No. NS-08813.

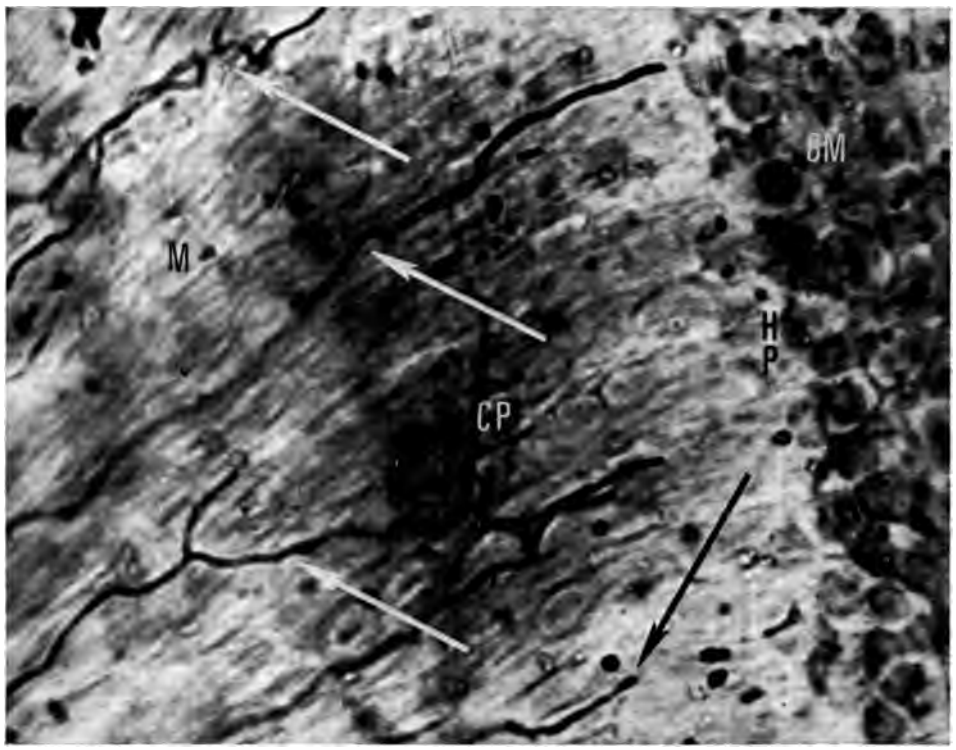

Fig. 1. Photomicrograph of spiral lamina from the apical turn of No. 534R. A number of impregnated nerve fibers cross the field from left to right (white arrows). The fiber at lower center terminates in a small end bulb (black arrow): BM: basilar membrane, CP: capillary, HP: habenula perforata, M: myelinated nerve fibers. X1,000

ously drawn, with either glass or diamond knives. In order to avoid any further precipitate which might be introduced by heavy metal staining, the sections were put into the microscope and photographed without any further treatment. Use of the 40 Kv accelerating voltage in the EMU 300* and a double-strength HRP developing solution** enhanced the contrast.

FINDINGS

Any nerve fibers that are present in the tissue can be stained by the Golgi method. The cochlear nerve fibers, the olivocochlear axons, and some other nerve fibers in the spiral lamina which correspond in location and pattern to the adrenergic fibers described by Spoendlin and Lichtensteiger,[7] Teryama, *et al*,[8] and Spoendlin[9] have been studied.

Nerve Fibers in the Spiral Lamina. Some nerve fibers have been consistently seen in the spiral lamina which do not enter into the membranous cochlear duct. Some of these approach the habenula perforata but before reaching it (0.1 to 0.14 mm distant in three fibers measured) reverse themselves and loop back toward the modiolus. Most give off a few branches in their course through the spiral lamina; some branches also turn back toward the modiolus, whereas others are short and slender, with delicate end bulbs. Other fibers are straight and end within the spiral lamina. Some of the latter reach the neighborhood of the habenula perforata and seem to terminate occasionally by means of small end bulbs (Fig. 1). These nerve fibers have been studied in the apex where, because of the deficient bony shelf, they can be visualized more readily.

---

* Philips Electron Instruments, Inc., Mt. Vernon, N.Y.
** Eastman Kodak Co., Rochester, N.Y.

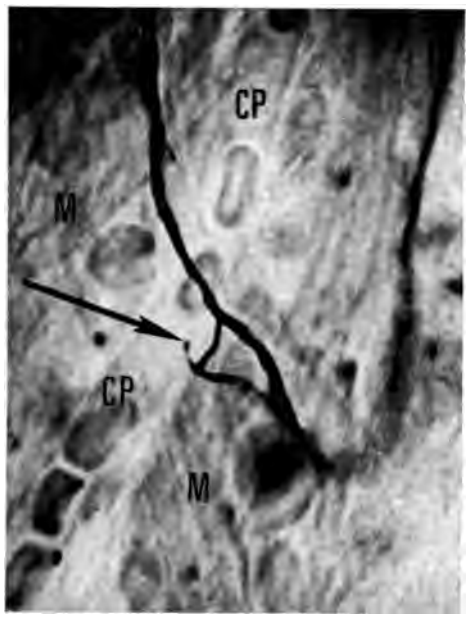

Fig. 2. Photomicrograph of the apical turn of spiral lamina from No. 533L. A looped nerve fiber enters and exists at top. It has a branch whose end bulb (arrow) is situated close to the capillary wall (CP). M: myelinated nerve fibers. X1,250

For the most part, those fibers which end, or seem to do so, send their terminal branches among the myelinated nerve fibers. A smaller number are closely related to the capillaries. Small end bulbs on slender branches have been visualized, under oil immersion and by means of Nomarski optics, which lie between the capillary wall and the myelinated nerve fibers. However, as seen in Figure 2, the nerve fibers do not follow the capillaries, but rather give off branches as they approximate or cross the blood vessels.

Cochlear Nerve Fibers. It was found that the cochlear nerve fibers were more easily impregnated in newborn animals than in adults, and many have been found and studied in the newborn cochleas. Preliminary observations reported in the previous studies[1,2] indicated that the branching pattern of the external spirals varied from basal to apical ends. The present studies are in general agreement, but there are still problems in the absolute identification of some fibers in the apical half of the cochlea. For the most part, the present findings will be confined to the basal external spiral nerve fibers. Table I includes a selection of 15 nerve fibers most of which are in the basal turns of the cochleas. One from the second turn whose identity has been provided by electron microscopy is included, for it illustrates the different apical branching pattern.

The fibers given in the table (except for No. 531L, T_2) are typical of the cochlear fibers in the basal coil (the basal 9 mm of basilar membrane[10]). The complete distance they coursed along the basilar membrane was in many cases indeterminate because the fibers were broken. However, the cochlear nerve fibers appear to cross the tunnel immediately after emerging from their respective foramina in the habenula and to turn toward the basal end of the cochlea in between the Deiters cells (Fig. 3) where they course in a spiral direction for distances ranging up to approximately 0.6 mm before branching. They branch over a shorter segment of basilar membrane, generally not much over 0.1 mm, and often less. The terminal branching length of the fiber from No. 542L (Table I) is only 43 μ. The length of basilar membrane innervated depends to some degree on the number of hair cells supplied, and this varies from 6 to 20. However, if the terminals do not supply consecutive hair cells, the branching length increases. A consecutive versus a nonconsecutive sensory cell innervation accounts for the 63 micron difference in the basilar membrane segments innervated by the first and fourth nerve fibers in No. 531L, T_1, mid (Table I) whose number of nerve endings differs only by one, and number of hair cells innervated only by two.

A second feature of the basal nerve fibers is their tendency to have an innervation preference for a single row. Figure 3 is a photomicrograph of the third nerve fiber in No. 531L, T_1, mid (Table I). A number of nerve endings are visible, all terminating on outer hair cells in the first row. Many nerve fibers

TABLE I

SAMPLES OF COCHLEAR NERVE FIBERS IN THE BASAL TURN (EXCEPT ONE IN THE LOWER SECOND TURN) FROM SIX DIFFERENT EARS (FIVE INDIVIDUALS)

Animal No.	*Cochlear Locus*	*Length of External Spiral (in microns)*	*Length of Terminal Branch (in microns)*	*Number of Nerve Endings*	*Number of Hair Cells Innervated*	*Nerve Endings on Hair Cell Rows*
		500	84	18	12	all on ohc II
370	T_1	430	68	11	6	all on ohc I
L	Lower	706	102	16	12	all on ohc III
531	T_1	336•‡	91	20	13	19 on 12 ohc I 1 on 1 ohc II
L	Mid					
		308•	112	20	20	17 on ohc I 3 on ohc II
		235•	117	20	13	all on ohc I
		560•	154	21	15	all on ohc II
		420•‡	126	23		all on ohc II
531	T_2	469‡	284	62		32 on ohc II 30 on ohc III
L	Lower					
542	T_1	316	73	20	13	7 on 5 ohc I 8 on 4 ohc II 5 on 4 ohc III
R	Upper					
542	T_1	at least 193	43	11	7	10 on 6 ohc I 1 on 1 ohc II
L	Lower					
543	T_1	at least 160	73	21	11	20 on 10 ohc I 1 on 1 ohc II
L	Lower					
556	T_1	230	90	14	10	all on ohc I
R	Lower	140	73	13	8	7 on ohc I 1 on ohc II
		197	93	16	12	11 on ohc I 1 on ohc II

• - Estimates; ‡ - embedded & sectioned ohc - outer hair cells

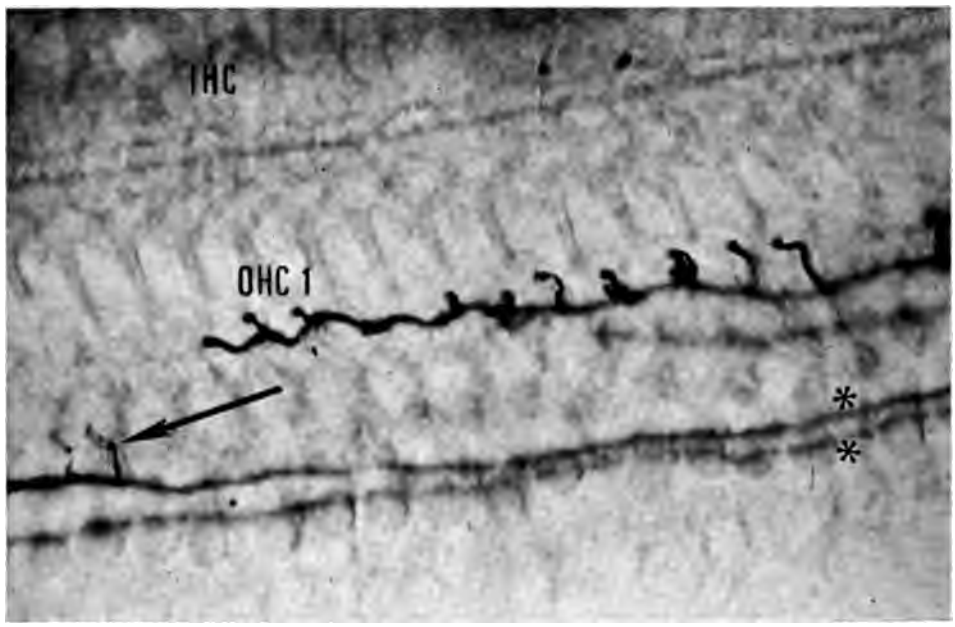

Fig. 3. Photomicrograph of external spirals in basal turn, No. 531L. The upper fiber has many branches on outer hair cells (OHC) in row 1 only. The other fibers are out of the focal field (asterisks); one at extreme left has two nerve endings on row 2 (arrow). X975

do innervate only a single row of outer hair cells; some give a few nerve endings to another row. The only exception to this seen to date is the fiber in No. 542R (Table I), whose nerve endings are rather evenly divided between the three rows; a camera ludica drawing of this fiber is shown in Figure 4.

The latter type of branching pattern is more typical of the upper half of the cochlea. The nerve fiber from the lower second turn of No. 531L (Table I) illustrates the pattern generally seen in the upper turns. A large number of nerve endings, 62 are divided between the hair cells in the second and third rows (Figs. 5 and 6). Not all the nerve fibers in the upper turns which display the afferent branching features supply several rows of outer hair cells, but they are much more frequently found there.

Several of the nerve fibers have been embedded, sectioned in a series, and studied by electron microscopy. A camera lucida drawing and photomicrograph of the first fiber in T_1, mid No. 531L in Table I are shown in Figures 7 and 8. Figure 9 is an electron micrograph from the same fiber, or an outer hair cell in row 1, where all but one nerve ending from that fiber terminated. The parent fiber, the impregnated dendrite, is visible at the lateral edge of the tunnel, in a channel formed by the Deiters cell processes approximately 12 μ below the hair cell. Other nonimpreg-

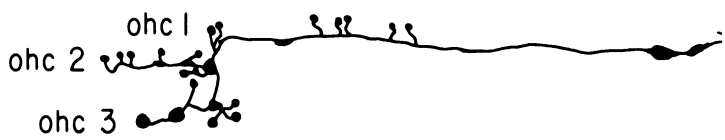

Fig. 4. Camera lucida drawing of nerve fiber from the upper basal turn, No. 542R. This nerve fiber, with nerve endings evenly divided between rows 1, 2, and 3 of outer hair cells is the only one of this type so far found in the basal turn.

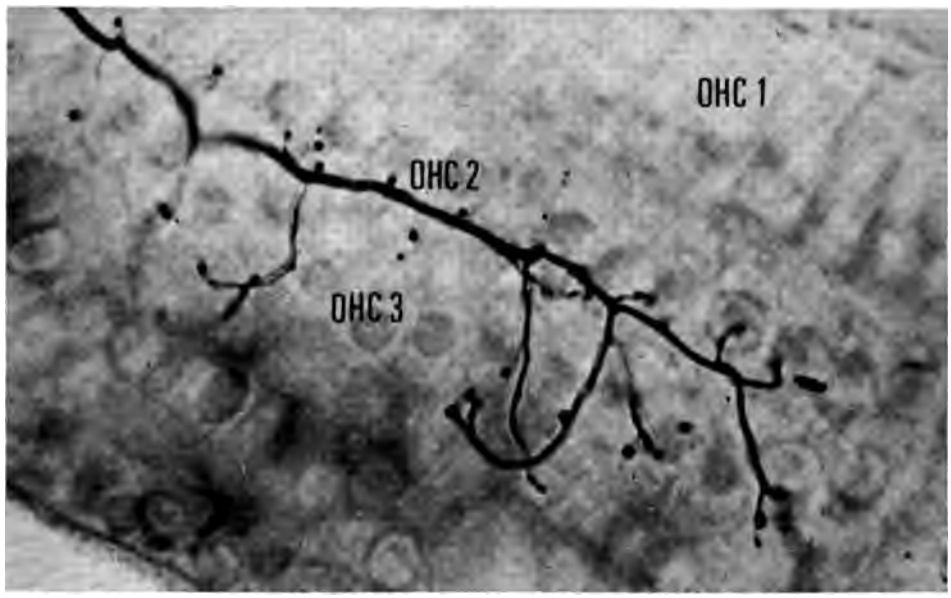

Fig. 5. Photomicrograph of the terminal end of an external spiral fiber in the second turn of No. 531L. Most nerve endings are on row 2 (OHC 2) and row 3 (OHC 3) of outer hair cells. Some branches turn out to Hensen's cells. X975

nated external spirals are visible nearby. In other micrographs the slender preterminal branch could be followed up to the small end bulb at the base of the outer hair cell, visible here. Figure 10 shows another ending from this nerve fiber, on another hair cell at higher magnification. This terminal is heavily impregnated with the dense precipitate; synaptic organelles are either masked or have been destroyed. Some of the precipitate often falls out during sectioning and/or flotation prior to collecting the sections on the grids. Cytoplasmic organelles in the surrounding cells are remarkably well preserved when one considers the long soaking process to which the tissue has been exposed.

Figure 11 is an electron micrograph from the nerve fiber in the second turn, illustrated in Figures 5 and 6. It shows an impregnated, small bulbous nerve ending with attached preterminal at the base of a hair cell in the second row. It is similar in form and size to the adjacent cochlear nerve endings. The nerve endings studied by electron microscopy are identified by their size and shape. Previous experimental studies have shown that in the guinea pig,[11] the chinchilla,[12,13] and the rat,[14] the small, one micron, nerve endings on outer hair cells are those that survive after efferent nerve section and that these are the afferent cochlear nerve terminals. Electron microscopic observations on the newborn cochleas revealed that the nerve fibers and nerve endings were similar to those in adult animals.

The Olivocochlear Efferents. The



Fig. 6. Camera lucida drawing of the entire branching pattern of the fiber in Figure 5.

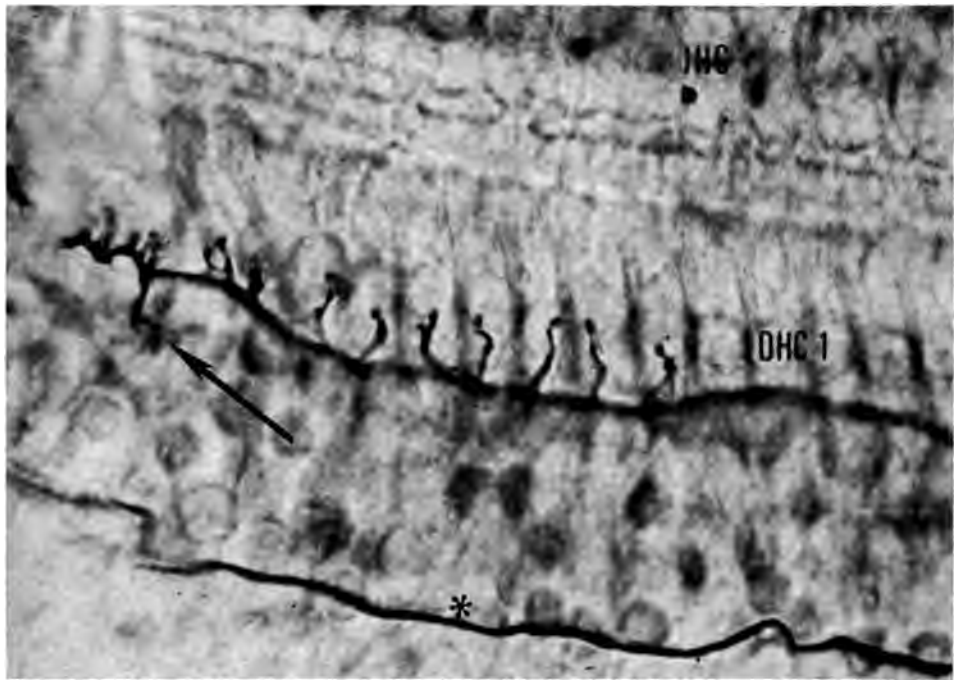

Fig. 7. Photomicrograph of external spirals in basal turn of No. 531L. The upper fiber gives most branches to row 1 (OHC 1) and one to a single hair cell in the second row (arrow). An unbranched fiber is below (asterisk). IHC: inner hair cells. X975

axons and nerve endings which belong to the olivocochlear tract can usually be recognized by the size of the endings (Fig. 12) which are approximately three times as large as the cochlear nerve terminals.[15,16] They can also be recognized by their course which was studied, as a whole by the AChE stains and, in the past, in de-efferented chinchillas.[12,13,16,17]

Experimental studies have previously shown[12] that they form a large part of the inner spiral bundle, the tunnel bundle, and the large nerve endings on the outer hair cells. AChE stains on the newborns also demonstrated a spirally directed network not far distant from the basal ends of the outer hair cells. All of these features, plus some others, are evident in the Golgi-stained fibers.

There are many fibers that course long distances (more than 1 mm) in the inner spiral bundle. One in the basal coil coursed for approximately

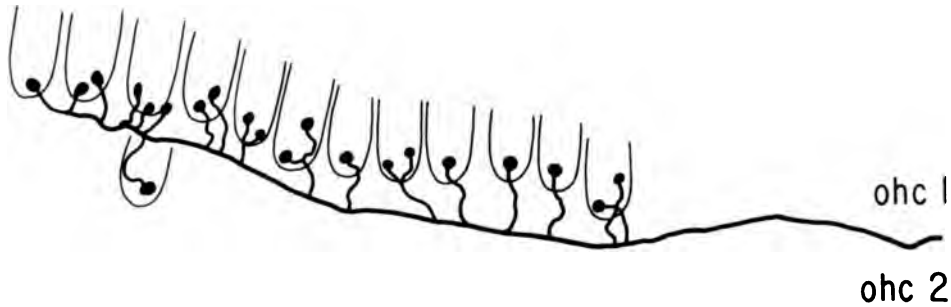

Fig. 8. Camera lucida drawing of the fiber in Figure 7.

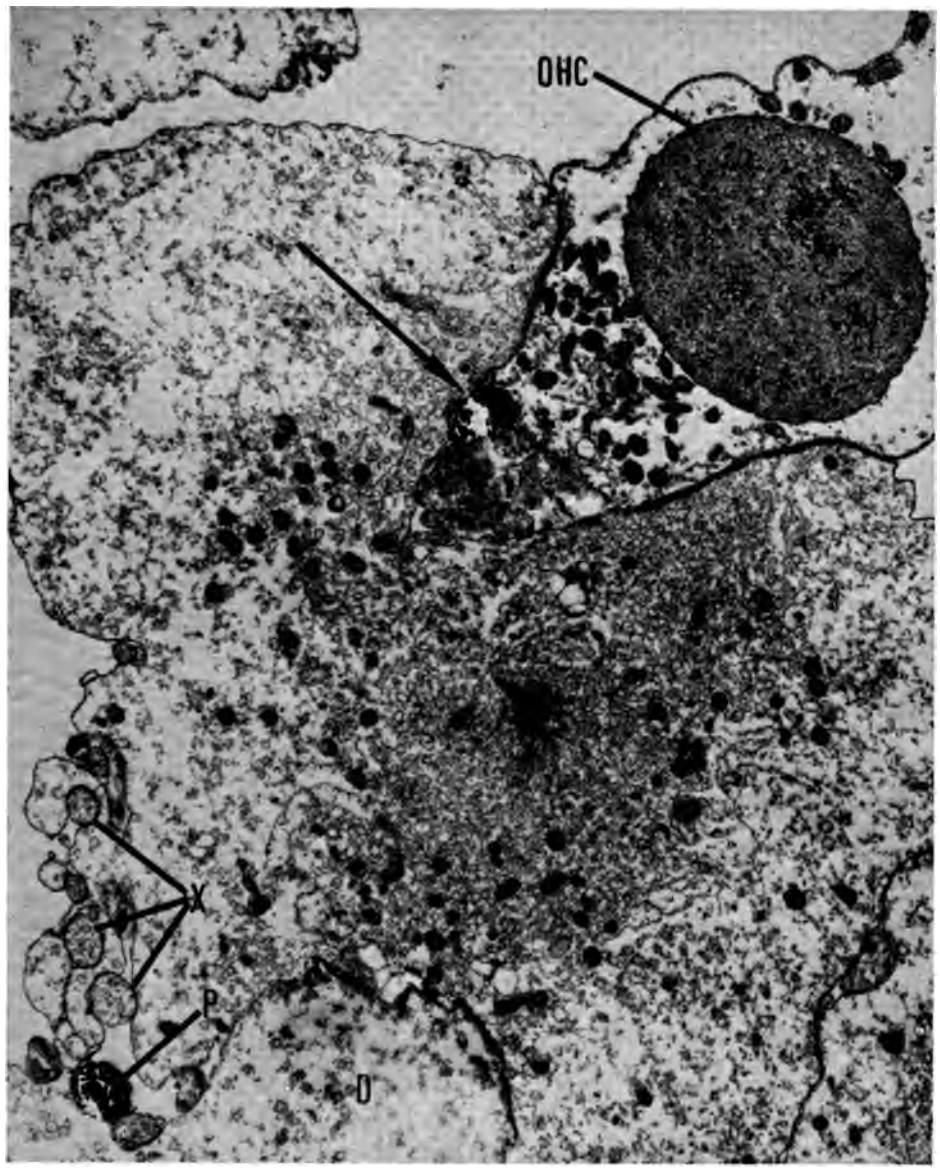

Fig. 9. Electron micrograph of outer hair cell (OHC), with small nerve ending filled with precipitate (arrow), from the nerve fiber in Figures 7 and 8. The parent dendrite (P) is at lower left in a Deiters cell (D) channel. X: other external spirals. X7,600

560 μ, without branching for most of that distance; it finally bifurcated, and one branch appeared to terminate on an inner hair cell. The fibers in the inner spiral bundle have many beaded enlargements. They also have short side branches with end bulbs, but these are infrequent. These latter branches are not generally near the inner hair cells, although some do touch the inner hair cells, as shown by electron micrographs (Fig. 13). Some inner spirals give branches which course in the tunnel bundle, or the main fiber itself may turn out to join the tunnel bundle. In ears where many fibers were stained in

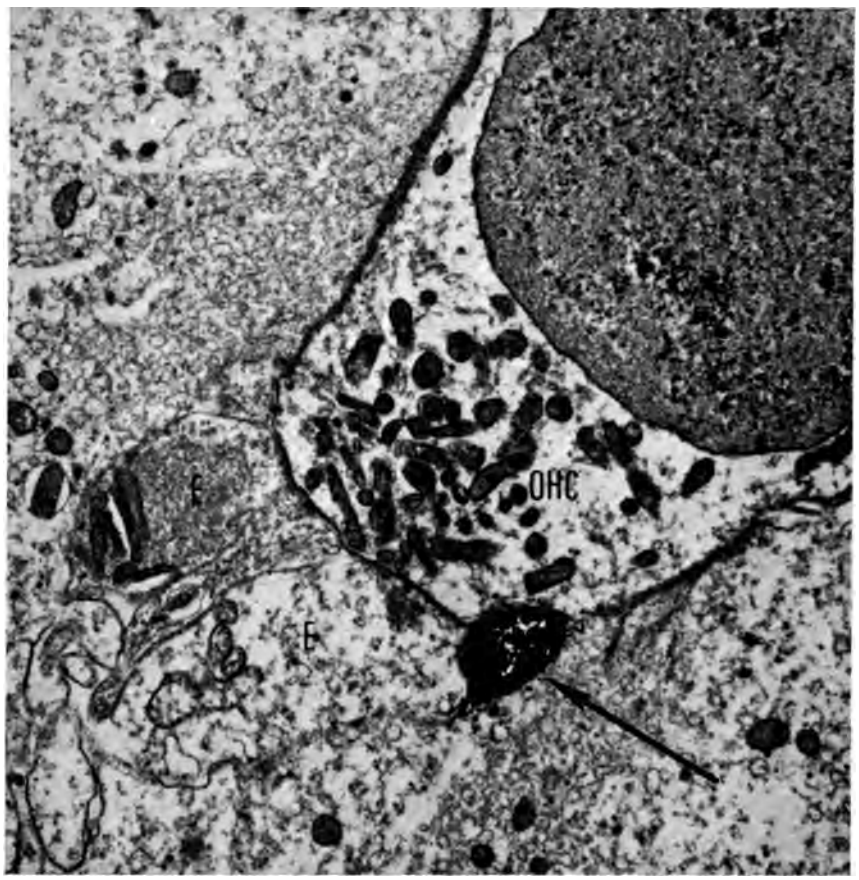

Fig. 10. Electron micrograph of outer hair cell (OHC) with impregnated nerve endings at arrow, from the nerve fiber in Figures 7 and 8. E: efferent nerve endings. X12,000

both inner spiral and tunnel bundles, there were repeated communications crossing between the inner hair cells, indicating a common source of the two bundles. This was also obvious in the AChE-stained cochleas. Wright and Preston[18] have recently demonstrated these communications between tunnel and inner spiral bundles by use of the Maillet stain.

Some of the efferent axons enter the organ of Corti through the foramina nervosa and directly cross the tunnel to the outer hair cells. Here, they ramify among the Deiters cells (between rows 1 and 2 in the lower part of the cochlea). In the basal turn, the nerve endings per terminal axon branch tend to be few in number (3, 5, 8, *etc.*) and to be distributed over a short segment of basilar membrane, to one, two, or three rows (Fig. 14). The large nerve endings on the long slender stalks look much like bunches of grapes hanging from an arbor, and we[1] have called the pattern a "grape arbor" form.

Other efferent terminal axons do not directly cross the tunnel, but course in the inner spiral bundle for some distance before crossing. Or they give off a branch which courses with the inner spiral bundle. One inner spiral fiber (upper third turn) sent a branch to the tunnel bundle where it traveled for 100 μ, finally giving off three branches. Branches one and three crossed the tunnel, ramified, and terminated in approximately eight large nerve endings

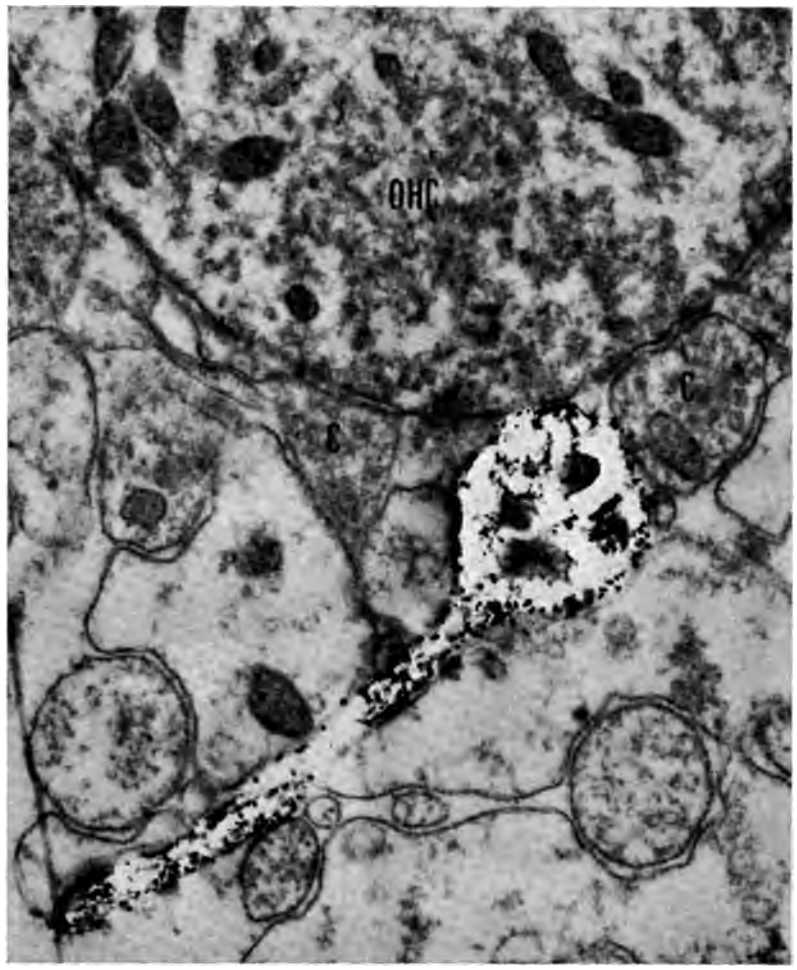

Fig. 11. Electron micrograph of an impregnated nerve ending with slender preterminal, synapsing on an outer hair cell (OHC) in second turn from the nerve fiber in Figures 5 and 6. C: unimpregnated cochlear nerve endings. X27,300

on the first row, and smaller ones to the second and third rows of hair cells. The middle branch simply made a blind loop in the tunnel.

Figure 15 is a drawing of an efferent axon in the apical coil which bifurcated shortly after emerging from its foramen. Both branches terminated on the outer hair cells, but one coursed for 190 μ in the inner spiral bundle before doing so. There is no evidence in the present study, whether these axons have their source in the homo- or contralateral olivocochlear tracts.

The position of the spirally directed efferent network beneath the outer hair cells in the upper part of the third turn shifts laterally. It is thinner and is located beneath the second row of outer hair cells. The ramification of the axons also changes in the upper part of the cochlea (Fig. 15). Fewer hair cells in the second and third rows have efferent nerve endings, and the segment of basilar membrane innervated by a single axon is broader than in the basal turn. In the apical turn only scattered islands of hair cells in rows two, three, and four are innervated, mostly by beaded enlargements. Some branches are diverted toward the Hensen's cells.

There are some spiral efferents in the

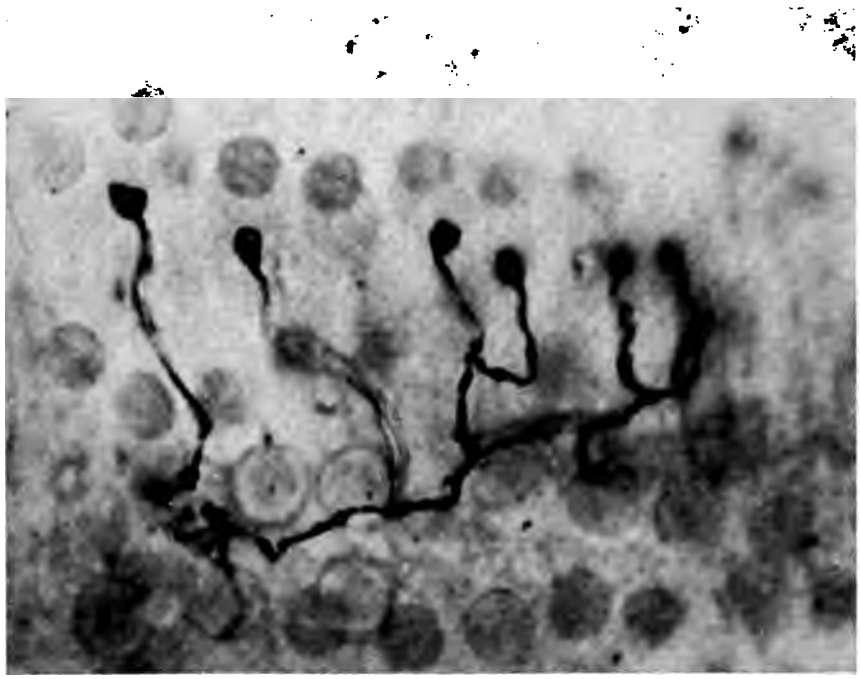

Fig. 12. Photomicrograph of efferent nerve fiber and terminals, from the third turn of No. 556L. X1,250

upper turns (also noted by Wright and Preston[18]). One from the fourth turn was studied and drawn. This nerve fiber coursed for a distance of approximately 235 μ toward the apex and then turned and completely reversed its course. When it coursed in the neighborhood of the first row of the outer hair cells, branches with large nerve endings were given off; when it coursed somewhat distant from the hair cells, there were no branches. These efferent spiral fibers, which seem quite rare, are different from the cochlear spiral fibers in that they take a rambling course, and are not "arrow-straight," such as the cochlear nerve fibers tend to be.

DISCUSSION

The results emphasize once more that cochlear innervation is not simple and that information going in to the cochlear nuclei reflects not only neural activity generated by sensory cells in response to the wave form along the basilar membrane, but also possible interaction between different neural systems. First, there are the efferent axons of the olivocochlear tract. The close relationships of these axons to the cochlear nerve fibers beneath the inner hair cells was described in the guinea pig by the present author in 1961,[19] and in the cat by Spoendlin and Gacek.[20] Axodendritic synapses have also been demonstrated beneath outer hair cells in several species.[21] There are close relationships between the efferents in the tunnel and cochlear nerve fibers coming from outer hair cells in the chinchilla.[17] There is also the possibility of influence by sympathetic or parasympathetic fibers.

The presence of adrenergic nerve fibers in the spiral lamina was first demonstrated by Spoendlin and Lichtensteiger[7] and Terayama, *et al.*[8] Spoendlin[9] later found that there were two plexuses, one related to blood vessels and one which was independent of the vascular elements. A recent electron microscopic study by Densert and Flock[22] showed that adrenergic nerve

Fig. 13. Photomicrograph of inner hair cell (IHC) from the apical turn of No. 535R. A large impregnated efferent nerve ending with slender preterminal is visible at the hair cell membrane (arrow). A few other stained fibers are seen below (asterisks). The dense material associated with the tear at lower right could be artifact. ISB: inner spiral bundle. X12,000

fibers reach and apparently terminate at the habenula but do not pass through the foramina into the organ of Corti. The fibers presently described in the spiral lamina could be those fibers. Some appeared to actually end close to the habenula although there is always the possibility these could have been incompletely impregnated fibers. Other nearby fibers made loops and turned back toward the modiolus. The latter gave off small branches, some of which were close to the capillaries, others of which terminated among the myelinated nerve fibers. At present, no nerve fibers have been seen which actually followed the capillaries. Possibly the observations are biased by the fact that only the apical spiral lamina could be examined in these animals. It seems that the fibers presently studied belong to the adrenergic plexuses previously described[7-9,22] although further study is needed.

There are many basic questions being



Fig. 14. Camera lucida drawing of three efferent fibers from the lower basal turn of No. 534L, showing the limited branching pattern found in the basal turn. The nerve fiber at right was broken during dissection. T - tunnel.

raised today about cochlear innervation, mostly stimulated by studies of single nerve responses initiated by Tasaki,[23] and so successfully pursued by Kiang.[24] Responses from single nerve fibers can best be correlated with knowledge about single nerve fiber patterns. However, the present studies have yielded data regarding the external spiral cochlear fibers only. Most of the response curves in physiological studies probably would have been obtained from nerve fibers from the inner hair cells, which seem to be in preponderance.[25] Because of the tendency for all fibers to respond in a manner fairly similar, it has been suggested that there may be some bifurcation or branching of a fiber which terminates on the outer hair cells, whereby it supplies both inner and outer hair cells. Perkins[26] found that in young cats and rats, the external spirals formed at least one angular enlargement beneath the inner hair cells. In the present studies, there is no evidence that the external spirals in their course from the habenula to the tunnel give any branches, or even pass close to the inner hair cells. The more completely developed ears of the newborn guinea pigs used here may account for this difference. A recent study by Pfeiffer and Kim[27] has indicated that cochlear nerve fibers might be classed in two groups if one looks at responses to increased sound pressure levels. A small percentage of single fibers from cats produced an increasing number of peaks in response to increased sound pressure level (SPL). This would seem to fit in with the branching pattern of the external spirals, where summation of activity generated by a large number of hair cells innervated by a single fiber could occur. The nerve fiber in No. 531, T_2, with 62 nerve endings would be more likely to respond in this manner than some of the external spirals in the basal turn which innervate only six, seven, or eight hair cells.

The newborn guinea pigs are relatively mature animals at birth. They move about quite freely within an hour postpartum. They have good pinna reflexes, and microscopic examination reveals their middle ears to be free of gelatinous material such as found in newborn rats and cats. Electron microscopic examination showed the innervation of the hair cells to be similar to those of adult animals. In all probability, the afferent neural pattern herein described is greatly similar, if not identical, to that of full-grown animals. The efferent axons apparently enter the organ of Corti at a period postdating that of VIII nerve innervation. According to Kikuchi and Hilding,[28] the efferent terminals are not present in the young mouse until the tenth day postpartum. Mice, rats, and cats, however,

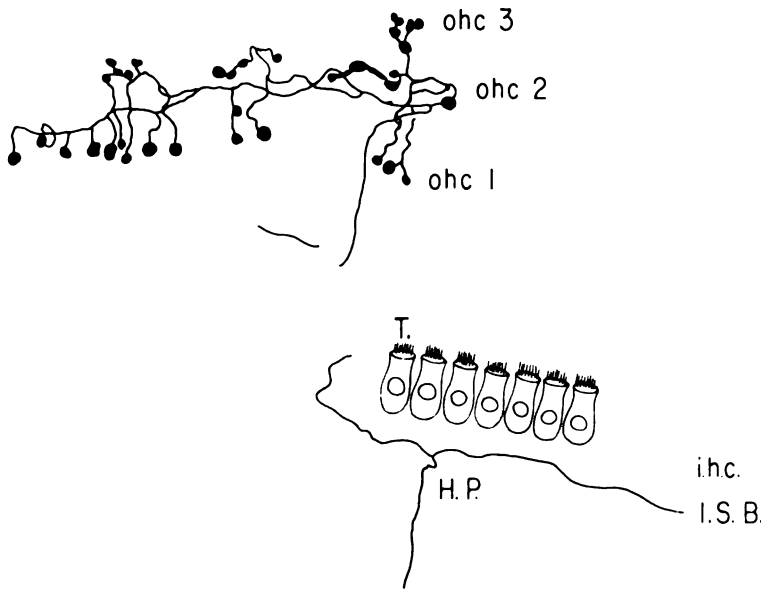

Fig. 15. Camera lucida drawing of an efferent nerve fiber in the third turn of No. 530R. The nerve fiber bifurcates after penetrating the habenula perforata (H.P.) and sends one branch to the inner spiral bundle (I.S.B.). The other branch crosses the tunnel (T.) (broken in dissection) and ramifies under the outer hair cells.

are quite immature at birth and it is well known that the cochleas of rodents are not fully developed until about two weeks postpartum. Rossi[29] found that colored precipitate did not appear lateral to the tunnel, in the apical turn of the guinea pig cochlea after use of the AChE stain, until the fiftieth day of life. This is not in agreement with the present findings, for an AChE - positive plexus beneath the outer hair cells of the fourth turn was demonstrable in the newborn cochlea. However, we used a later, improved Karnovsky technique[5] with prior fixation of the ear. Rossi did not fix his sections and the smaller amount of enzyme in the apex may have diffused away. At any rate, some of the present data regarding Golgi-stained efferents was obtained from older, adult animals. We have seen no obvious differences between efferent innervation of the newborn and animals of 400-500 g weight.

The efferent pattern presently described does demonstrate an interesting feature, which has also been seen in the cat and rat by Perkins and Morest.[30] That is that some of the axons, after penetration of the habenula, bifurcate with one branch being diverted to the inner spiral bundle, whereas the other crosses the tunnel to terminate on the outer hair cells. The branching is sometimes more complex, but the critical feature is that a single terminal efferent branch with this pattern thus has the possibilities for influencing information coming from both inner and outer hair cells. Of course, one must remember that only the terminal branching is visualized here. According to Rasmussen[31] considerable ramification has already occurred in the spiral lamina before this point so that possibly a single fiber which comes through the habenula and turns into the inner spiral bundle may have the same parent fiber in the spiral lamina, with one that leaves the habenula and directly crosses the tunnel to terminate on the outer hair cells. The studies made by Wiederhold and Kiang,[32] Wiederhold,[33] and Teas, Konishi, and Neilsen,[34] in which stimulation of the crossed olivocochlear bundle caused changes in discharge rates of most of the nerve fibers studied, could best be explained by a pattern

whereby at least some crossed efferents were in a position to influence cochlear nerve fibers coming from inner as well as outer hair cells. The present data demonstrates that this could occur, assuming the fibers stained were from the crossed tract. They could also be homolateral fibers, for we[17] have recently found that some of these terminate on outer hair cells.

The present observations are not entirely consistent with Spoendlin's[25] recent schema derived from electron microscopic observations on cats although this may be a species difference. As pointed out before, the fibers in the guinea pig's basal turn only rarely supply all three rows such as he illustrates. Neither is the efferent innervation of outer hair cells a simple radial pattern throughout the cochlea.

Continuing observations, the results of which have been given here, appear to confirm our preliminary assumption that the cochlear innervation pattern in guinea pigs varies from basal to apical turns. The apical external spirals more frequently innervate a longer and wider segment of basilar membrane than in the basal turn. In efferent innervation, also, a limited innervation by a single fiber was more frequently seen in the lower turns, whereas a longer segment of basilar membrane was supplied by single fibers crossing the tunnel in the apical turns. So that again, we appear to have more evidence for the variation in innervation from base to apex, such as we found previously[15] in hair cell innervation. Nevertheless, many more observations are necessary before we can establish a true picture of innervation characteristics from base to apex.

Lastly, this description is based on the assumption that only two kinds of nerve fibers (afferent and olivocochlear) are in the organ of Corti, for we have no good evidence, at this time, for the presence of others.

Request for reprints should be sent to Catherine A. Smith, Ph.D., University of Oregon Medical School, Department of Otolaryngology, 3181 S.W. Sam Jackson Road, Portland, Ore. 97201.

ACKNOWLEDGMENTS—The expert assistance of Susan Cameron, Betty Haglan, Robert Richter, and Ruth Robbins is gratefully acknowledged. The author also appreciates the courtesy of Dr. Kent Morest in supplying a preprint of Perkins and Morest: "A Study of Cochlear Innervation Patterns in Cats and Rats with the Golgi Method and Nomarski Optics."

REFERENCES

1. Smith CA, Haglan BJ: Golgi stains on the guinea pig organ of Corti. Acta Otolaryngol (Stockh) 75:203-210, 1973

2. Smith CA, Haglan BJ: Golgi stains of the cochlear nerve fibers. J Acoust Soc Am 54: 283-284, 1973

3. Valverde F: The Golgi method. A tool for comparative structural analysis, in Nauta W, Ebbesson S (eds) *Contemporary Research Methods in Neuroanatomy*. New York, Springer-Verlag, 1970, pp 12-31

4. Smith CA, Dempsey EW: Electron microscopy of the organ of Corti. Am J Anat 100:337-368, 1957

5. Karnovsky MJ: The localization of cholinesterase activity in rat cardiac muscle by electron microscopy. J Cell Biol 23:217-252, 1964

6. Takasaka T, Smith CA: The structure and innervation of the pigeon's basilar papilla. J Ultrastruct Res 35:20-65, 1971

7. Spoendlin H, Lichtensteiger W: The adrenergic innervation of the labyrinth. Acta Otolaryngol (Stockh) 61:423-434, 1966

8. Terayama Y, Holz E, Beck C: Adrenergic innervation of the cochlea. Ann Otol Rhinol Laryngol 75:69-86, 1966

9. Spoendlin H: Autonomic nerve supply to the inner ear, in de Lorenzo AJ (ed): *Vascular Disorders and Hearing Defects*. Baltimore, University Park Press, 1972, pp 93-109

10. Fernandez C: Dimensions of the cochlea (guinea pig). J Acoust Soc Am 24:519-523, 1952

11. Kimura RS, Wersall J: Termination of the olivo-cochlear bundle in relation to the outer hair cells of the organ of Corti in the guinea pig. Acta Otolaryngol (Stockh) 55: 1-32, 1962

12. Smith CA, Rasmussen GL: Recent observations on the olivo-cochlear bundle. Ann Otol Rhinol Laryngol 72:489-507, 1963

13. Iurato S, Smith CA, Eldredge DH, *et al*: Electron microscopic observations and cochlear potentials after section of the crossed olivo-cochlear tract in the chinchilla; in *4th Europ Reg Conf on Electron Microscopy*, Rome, 1968, pp 561-562

14. Iurato S: Efferent fibers to the sensory cells of Corti's organ. Exp Cell Res 27:162-164, 1962

15. Smith CA, Sjostrand F: Structure of the nerve endings on the external hair cells of the guinea pig cochlea as studied by serial sections. J Ultrastruct Res 5:523-556, 1961

16. Smith CA, Rasmussen GL: Degeneration in the efferent nerve endings in the cochlea after axonal section. J Cell Biol 26:63-77, 1965

17. Iurato S, Smith CA, Eldredge DH, Henderson D: Distribution of the crossed olivo-cochlear bundle in the chinchilla's cochlea. To be published

18. Wright CG, Preston RE: Degeneration and distribution of efferent nerve fibers in the guinea pig organ of Corti. A light and scanning electron microscopic study. Brain Res 58:37-59, 1973

19. Smith CA: Innervation pattern of the cochlea. Ann Otol Rhinol Laryngol 70:504-527, 1961

20. Spoendlin H, Gacek RR: Electronmicroscopic study of the efferent and afferent innervation of the organ of Corti in the cat. Ann Otol Rhinol Laryngol 72:1-27, 1963

21. Smith CA: Morphological features of axo-dendritic relationships between efferent and cochlear nerves in the cochlea of mammal and pigeon, in von Euler C, Skoglund S, Soderberg U (eds) *Structure and Function of Inhibitory Neuronal Mechanisms.* New York, Pergamon Press, 1968 pp 141-146

22. Densert O, Flock A: An electron-microscopic study of adrenergic innervation in the cochlea. Acta Otolaryngol (Stockh) 77:185-197, 1974

23. Tasaki I: Nerve impulses in individual auditory nerve fibers of guinea pig. J Neurophysiol 17:97-122, 1954

24. Kiang NY-S: *Discharge Patterns of Single Fibers in the Cat's Auditory Nerve.* Boston, MIT Press, 1965

25. Spoendlin H: Neuroanatomy of the cochlea, in Zwicker E, Terhardt E (eds) *Facts and Models of Hearing.* New York, Springer-Verlag, 1974, pp 18-32

26. Perkins RE: Innervation patterns in cochleas of cat and rat: study with rapid Golgi techniques. Anat Rec 175:410, 1973

27. Pfeiffer RR, Kim DO: Response patterns of single cochlear nerve fibers to click stimuli: descriptions for cat. J Acoust Soc Am 52:1669-1677, 1972

28. Kikuchi K, Hilding D: The development of the organ of Corti in the mouse. Acta Otolaryngol (Stockh) 60:207-222, 1965

29. Rossi G: L'acetylcholinesterase au cours du development de l'oreille interne du cobaye. Acta Otolaryngol (Stockh) [Suppl] 170, 1961

30. Perkins RE, Morest DK: A study of cochlear innervation patterns in cats and rats with the Golgi method and Nomarski optics. J Comp Neurol. To be published

31. Rasmussen GL: Efferent fibers of the cochlear nerve and cochlear nucleus, in Rasmussen G, Windle W (eds) *Neural Mechanisms of the Audiotory & Vestibular Systems.* Springfield, Ill., CC Thomas, 1960, pp 105-115

32. Wiederhold ML, Kiang NY-S: Effects of electric stimulation of the crossed olivocochlear bundle on single auditory nerve fibers in the cat. J Acoust Soc Am 48:950-965, 1970

33. Wiederhold ML: Variations in the effects of electric stimulation of the crossed olivocochlear bundle on cat single auditory nerve fiber responses to tone bursts. J Acoust Soc Am 48:966-977, 1970

34. Teas DC, Konishi T, Nielsen DW: Electrophysiological studies on the spatial distribution of the crossed olivocochlear bundle along the guinea pig cochlea. J Acoust Soc Am 51:1256-1263, 1972

DISCUSSION

JUERGEN TONNDORF, M.D.: The audience will probably recall that Henry Spoendlin from Switzerland startled us about three years ago with his finding in the cat, that 95% of all fibers go to the inner hair cells and only 5% to the outer hair cells.

I know, Catherine, you hate to count fibers, but maybe you can tell us your impression, *i.e.*, whether or not the same situation prevails in the guinea pig.

LESTER A. BROWN, M.D.: Dr. Lurie, do you agree with that branching between six-tenths and seven-tenths of a millimeter?

MOSES H. LURIE, M.D. (Boston, Massachusetts): Well, I listened with a little bit of amazement at the fine work that Dr. Smith is doing right now because forty years ago we were playing with the Golgi stain and we never succeeded in having such good end results as she did.

The techniques have become revolutionized and today we have seen the results of some very brilliant work with regard to innervation of the cochlea and again this seems to confirm what a great many of us have known for years, not only a dual mechanism is in the organ of Corti, but there are some very different mechanisms that enable us to differentiate between the different types of sound that come into the ear, and I think this is going to produce a lot of nice information and new theories. I congratulate Dr. Smith and I thank her.

CATHERINE A. SMITH, M.D. (closing): Yes, I do think Dr. Spoendlin is correct. There is a preponderance of nerve fibers to the inner hair cells. It will vary with species.

In the chinchilla it is about eight to one. I do not know what it is in the guinea pig.

TEMPORAL BONE HISTOPATHOLOGICAL FINDINGS IN TRISOMY 13 SYNDROME

ABSTRACT*

ISAMU SANDO, M.D.
ALBERTO LEIBERMAN, M.D. LAVONNE BERGSTROM, M.D.
DENVER, COLORADO
SOJI IZUMI, M.D.
YOKOHAMA, JAPAN
RAYMOND P. WOOD II, M.D.
DENVER, COLORADO

The histopathological findings of 14 temporal bones of infants with trisomy 13 syndrome are reported.

The temporal bones were removed from the refrigerated cadavers and placed in 10% formalin solution. They were then decalcified in 1% nitric acid solution, embedded in celloidin, sectioned with 20 microns thickness, and stained with H. and E.

The most primitive anomalies in the structures of the inner and middle ears in the present series are those of the semicircular canals, particularly of the horizontal canals; flattened horizontal canal cristae; absence or opening of the utricular endolymphatic valve; small facial nerve and obtuse angle of the geniculate ganglion area of the facial nerve. Each ear demonstrated more than one of these anomalies. The anomalies have features similar to those found in the structures of the normal six to ten weeks fetus. Many other anomalies such as the straight and shortened course of the endolymphatic duct and sac ending blindly in the otic capsule, shortening of cochlear length, wide cochlear aqueduct, bulky or thick stapes resembling the fetal form, malleus and incus containing large bone marrow cavities, absence of the pyramidal eminence, absence of the antrum, *etc.*, seen in our cases, are similar to features of later fetal life.

Most of the anomalies found in the inner and middle ears of these cases appear to be the result of poor development of the structures for reasons which are not now clear. Some abnormal inner ear findings which seem unrelated to poor development, such as endolymphatic hydrops in the cochlea, were also present in a few cases.

Except for partial saccular dysplasia in three ears, all cases demonstrated well-developed vestibular and cochlear end-organs, even though there were macroscopic anomalies of the membranous labyrinth. These anomalies did not seem to correspond entirely with anomalies previously described such as: 1) complete failure of the development of the inner ear (Michel type); 2) incomplete development of bony and membranous labyrinth (Mundini type); 3) incomplete development of membranous labyrinth (Bing-Siebenman type); 4) membranous cochleo-saccular aplasia (Scheibe type); and 5) membranous cochlear aplasia (Alexander type).

In addition to these anomalies, middle ear infection was found in all cases. The possibility of such infection being secondary to upper respiratory infection in the presence of the cleft plate is mentioned.

From the Department of Otolaryngology, University of Colorado School of Medicine, 4200 East Ninth Avenue, Denver, Colorado.

This study was supported by NIH Research Grant 2 R01 NS09293-041A CMS, Training Grant NIH 5T01 NS05504-09 and Dr. Wood's Contract HSM 77-27-171.

* The complete manuscript was published as Supplement 21, Vol. 84, July-Aug., 1975, No. 4, Part 2, with *The Annals of Otology, Rhinology and Laryngology.*

DISCUSSION

ROBERT J. RUBEN, M.D.: I think that the group from Colorado should be highly congratulated on pooling a large number of specimens and the paper demonstrates very well the biological variability that you have with perhaps one common cause.

I would like to ask the authors two questions: One, do they have any antecedent etiologies for any of their trisomy cases and is there some variability?

And, second, was there an examination of the brains either gross or microscopic, and what type of correlation may have been found between the two types of anomalies or the severity of the anomalies?

HAROLD F. SCHUKNECHT, M.D. (Boston, Massachusetts): This is a very excellent description of a rather rare disorder.

As you know, there are three main types of dysplagia of the ear, the first being the Scheibe type of cochlear saccular dysplasia, the second being Mondini, and both of these are genetically determined.

Then the third large group would be the one that was described here, that is, the trisomy group. I guess you all wonder what is so important about these trisomy ears when, in fact, all of these kids die within two or three weeks of birth.

But I think it is very important because you have a mixed up combination of anatomical errors in this disorder that could produce some very interesting information.

For example, suppose we find some of these ears having an absence of any endolymphatic sac with good secretory structures. We might be able to draw some conclusions about the function of the sac. Possibly we will find ears with absence of the stria vascularis. What will the absence of the stria do to the ear?

So, in spite of the fact that these will not be clinical problems, I think they could be very interesting from the scientific viewpoint.

JOHN E. BORDLEY, M.D. (Baltimore, Maryland): This is a most interesting paper. I believe that you reported that all these children had otitis media and I was wondering if you could describe the Eustachian tubes in some of these and give us some idea whether they had played some part in this condition.

RICHARD MARCUS, M.D. (Skokie, Illinois): We have observed in the Waardenburg syndrome radiologically what appeared to be the Mondini type deformity, a result therefore of a genetic defect.

The only histopathologic study that I know of in the Waardenburg syndrome indicated an aplasia of the organ of Corti, without indication of bony involvement.

We found also in some of our cases that radiologically the cochlea was dwarfed without other osseous changes and this would of course correspond with what Dr. Bergstrom has shown here, that the length of the cochlea is considerably reduced.

However, in her instance the organ of Corti seems to be perfectly normal and this is of some considerable interest to me. There appear to be similarities in certain osseous changes in both these genetic syndromes, but the cochlear neuroepithelium is spared in the trisomy 13-15. Could this be due to its different embryologic origin or to some other factor in the translocated chromosome?

ROBIN P. MICHELSON, M.D.: I certainly enjoyed this paper very much. I do have a question. I did not see anything that looked like the spiral ganglion and were there spiral ganglion cells?

LAVONNE B. BERGSTROM, M.D. (closing): I may have to get Dr. Sando up here to help me, but let me try.

In response to Dr. Ruben's question as to whether we thought there were any antecedent etiology underlying the trisomy 13, I do not believe that we were able to make that conclusion from any of our cases. We have some other cases of chromosomal defects in our laboratory in which there was some evidence of viral infections but that was not true so far as I can recall with this group.

With respect to the brains, yes, they were examined and the one consistent finding was, as has been described before in trisomy 13, arrhinencephaly. I believe some of the cases had absence of the corpus callosum as well. Dr. Sando will have to correct me or add if there are any other findings.

I would like to thank Dr. Schuknecht for his comments. I think, as always, he has found the possible practical application of some of these cases which, I must also say, do not give us much chance to practice any of our clinical expertise.

In response to Dr. Bordley's question, there was nothing unusual about the Eustachian tubes in terms of their anatomy, but in some of the ears the inflammatory reaction did extend into the tubes.

Many of these children had cleft palates as well, and one would anticipate that there would at least be some functional disorder of the Eustachian tube that would have been clinically significant.

In answer to the comment by Dr. Marcus, I really think the question he raised as to whether the neuroepithelium was involved in these instances may be valid. We did not make any specific conclusion with regard to that.

In response to the last commentator whose name I did not catch, yes, in many of these ears the spiral ganglion was present.

GENETIC SENSORINEURAL DEAFNESS IN ADULTS

MICHAEL M. PAPARELLA, M.D.

DAVID G. HANSON, M.D. K. N. RAO, M.D.

ROLF ULVESTAD, M.D.

MINNEAPOLIS, MINNESOTA

SUMMARY – Progressive genetic sensorineural hearing loss is a common problem in adults which is frequently incorrectly diagnosed or escapes diagnosis as to etiology altogether. If the hearing problem becomes manifest in the twilight of the patient's life it is often identified with the nondescriptive term "presbycusis." In all patients with sensorineural hearing loss, extrinsic (environmental) causes should be ruled out after which intrinsic or genetic etiology should strongly be considered, recognizing that extrinsic factors can be superimposed. A group of young adults was studied and diagnosed as having genetic progressive hearing loss. Polytomography ruled out the theoretical possibility of cochlear otosclerosis. The diagnosis of this disorder rests most heavily on the history and audiometric configuration which is characteristically flat or basin shaped with fairly good discrimination. Of further diagnostic significance was the fact that some patients, early in the course of their difficulty, presented with a predominantly low- or high-frequency loss which, over time, assumed a flat audiometric shape. The most important pathological finding from human temporal bone studies was atrophy of the stria vascularis.

The best available statistics estimate that between eight and nine million people (10 to 15% of the adult population) in the United States are affected by significant hearing loss. Yet, in the face of these figures, we know relatively little about many of the causes of this problem. In the 1968 National Center for Vital Health Statistics survey,[1] 20% of patients with significant hearing loss ascribed it to an infectious etiology, and 7% felt their hearing loss was due to trauma. Thirty-five percent listed hearing loss as due to unknown causes. "Other ill-defined conditions" included another 35%. These "ill-defined conditions" included old age, heredity, and noise trauma.

Hearing loss has long been accepted by the general population as an inevitable product of aging. The term "presbycusis" was coined to describe this process by Zwaardemaker in 1893.[2] Unfortunately the term "presbycusis" does not further elucidate the nature of the causes of adult hearing loss. Interest in noise trauma has raised the question of its role in the deafness of aging. Accumulative ototoxic effects may also have a role in aged hearing loss. However, it is clear that the etiology of deafness of aging is not at all well understood. If presbycusis is due only to the aging process, why do some people become deaf at 60 years of age and others have good hearing into their eighties? Environmental factors do not explain the wide range of variability of hearing loss in people who have lived and worked in the same environment all of their lives.

The role of hereditary influence on adult hearing loss is certainly most significant but is still not adequately ap-

---

From the Department of Otolaryngology, University of Minnesota, Minneapolis, Minn.

This study was supported by NINDS Training Grant 5-T01-NS05349-14 and NINDS Program Project Grant 1 PO1 NS 12125-01.

preciated. It is our purpose here to emphasize the place of adult genetic hearing loss and describe briefly how these patients may be identified in practice. We will also describe briefly some of the genetic characteristics and discuss, with temporal bone evaluation, possible relationships to cochlear otosclerosis and the deafness of aging.

PATTERNS OF INHERITANCE

A brief simple review of single gene inheritance may be in order. The development of the ear is dependent on perhaps thousands of genes controlling anatomy and physiology in the development and maintenance of hearing function. While organ development may be dependent on many genes, an abnormality in any single gene may have profound influences on hearing. Likewise, genetic patterns may be influenced by several factors. When a given gene is present, it may not be apparent clinically. "Penetrance" is the term referring to the frequency with which a genotype is morphologically manifest. "Expressivity" refers to the degree to which a gene is expressed, *i.e.*, some offspring may not show full expression of a phenotype even though the gene is dominant or homozygous recessive.

Autosomal Dominant Inheritance. This pattern is carried vertically from one generation to another. The trait is carried on an autosomal gene, and the trait is inherited in the presence of that gene. The affected parent passes on the trait to approximately 50% of offspring. Males and females are equally affected.

Autosomal Recessive Inheritance. It takes two genes, one from each parent, for the recessive trait to be expressed. Usually the parents are clinically normal and transmit the trait (phenotype) to one-quarter of their children (homozygous). Another one-quarter of the children do not carry the gene or trait, and one-half of the children are heterozygous or have one gene for the trait, as do the parents. Parental consanguinity is not unusual in recessive inheritance patterns, especially in rare disorders. Chung, *et al*,[3] used statistical techniques in studying frequency of consanguinity of parents in relationship to the incidence of deafness in the population. They estimated that there may be 24 to 48 types of recessive hearing loss and felt that there may be one in eight people heterozygous for at least one of the genes which can affect deafness.

X-Linked Inheritance. In x-linked inheritance there is never male-to-male transmission. The trait is carried on the x-gene. One-half of males will receive the affected gene from a carrier mother. The affected heterozygote male will likewise pass on the gene to all of his daughters. Heterozygotic females may be affected by the gene as one chromosome is often suppressed, allowing the affected gene to be expressed (the Lyon hypothesis). Rarely, a homozygous female results from the union of an affected male and a female heterozygote.

TABLE I

SENSORINEURAL HEARING LOSS

I. Congenital Hearing Loss
   A. Genetic (intrinsic)
      1. Associated with other abnormalities (syndromes)
      2. Occurring alone
   B. Nongenetic (extrinsic)

II. Progressive or Delayed Hearing Loss
   A. Genetic (intrinsic)
      1. Associated with other abnormalities (syndromes)
      2. Occurring alone
   B. Nongenetic (extrinsic)

ADULT GENETIC HEARING LOSS

Table I suggests a general outline of sensorineural hearing loss. This paper concerns the category of progressive genetic hearing loss not associated with other abnormalities. Hereditary hearing loss occurs in many forms. It can be transmitted in dominant, recessive, or x-linked patterns. The large majority (90%) of genetic congenital deafness is recessive in inheritance patterns. Most adult, progressive, genetic hearing loss is inherited in a dominant manner.

Genetic hearing loss is thought to be responsible for deafness in as many as

50% of congenitally deaf patients. Hereditary deafness may occur as often as one in 650 school children.[4] Approximately one-third of these children have other associated anomalies. Hereditary deafness syndrome associated with other system abnormalities are rather well defined because of the obvious associated anomalies.

Isolated hearing loss without other organ anomalies has been less readily recognized as being genetic in origin. Yet, there are perhaps more than 15 types of hereditary hearing loss with no associated abnormalities.[5] Many can be separated from each other by mode of transmission, age of onset, severity of hearing loss, and audiogram type. Even less frequently recognized has been genetic hearing loss, which may be delayed in onset well into the adult years. This classification has been adapted from Konigsmark and Gorlin.[6] In all probability, these groups will be further fragmented into distinct disorders as they are more carefully identified and studied. Audiometric and vestibular testing is usually rudimentary in even the best-studied genetic groups at present. In the future, further sophisticaiton of testing and the addition of temporal bone tomography, histopathology, and histochemistry with biochemical evaluation of associated enzyme defects (in the case of recessive disorders) will define specific gene disorders.

The recognition and classification of deafness due to dominant inheritance and of delayed onset unassociated with other abnormalities began in the 1920's and is generally credited to Albrecht.[7] Subsequently, several types of adult genetic hearing loss appear to have emerged as separate entities.

Dominant Progressive Early Onset Sensorineural Hearing Loss. A type of early onset progressive hearing loss beginning in early adult life has been described by Stevens and Dolowitz,[8] Johnsen,[9] Huizing, *et al*,[10] Lenzi,[11] and Nance and Sweeney.[12] Teig's study of a family of 25 members showed progression of hearing loss over a 15-year follow-up.[13] Typically the pattern in these families is of high-frequency loss, onset in late childhood or early adulthood years, progressing to a flat audiogram. Positive recruitment tests were characteristic. Heredity appears to be autosomal dominant.

Dominant Low-Frequency Sensorineural Hearing Loss. Hearing loss progressing from low-frequency deafness to a later involvement of all frequencies was described by Konigsmark, *et al*,[14] and by the Vanderbilt study group.[15] Other audiometric testing showed the SISI test positive in about 75% of cases. Tone decay was negative, discrimination was good, and vestibular testing was normal. Temporal bone tomograms were also normal. Each of the kindreds with this syndrome has shown autosomal dominant transmission.

Dominant Midfrequency Sensorineural Hearing Loss. Hearing loss involving the midfrequencies and a basin-shaped curve audiometric pattern in childhood or young adult years has been described by Martensson,[16] Williams and Roblee,[17] and Konigsmark, *et al.*[18] This pattern is progressive, involving all frequencies in later life. Tone decay tests were negative, and SISI tests were usually positive. Caloric testing was normal.

Recessive Early Onset Sensorineural Hearing Loss. The only recessive pattern of progressive hearing loss not present at birth is described in the cases of several kindreds and progresses rapidly to complete deafness at an early age.[6]

X-Linked Progressive Sensorineural Deafness. X-linked early onset sensorineural deafness likewise was described by Mohr and Mayeray.[19] It is transmitted in an x-linked pattern and progresses rapidly during childhood years. Livan described a family with an apparent x-linked pattern of inheritance of a slowly progressive sensorineural hearing loss which was first noted at about the age of ten.[20] The hearing loss progressed to involve high frequencies first, and later, low frequencies.

There are other genetic patterns of

TABLE II

PATIENTS WITH PURE APPARENT PROGRESSIVE HEARING LOSS

Pt. Name	Age	Onset	Type of Loss	Severity (R&L Average) 500	1000	2000	4000	Polytomes
AM	53	13-15	Flat	70	70	75	80	Negative
CM	31	16	Flat	45	55	45	48	Negative
HM	29	15	Low Basin	45	50	38	15	Negative
DLM	20	15	Low Basin	45	40	28	23	
WM	4	Asymp	Low Basin	50	48	13	10	
DKM	25	12	Low Basin	52	52	42	15	Negative
VM	26	5	Flat	55	55	55	40	
MG	66	60	Flat	48	50	45	50	Negative
RS	56	38	Flat → High Tone	33	38	30	65	
MS	51	36	Flat Basin	38	45	55	50	Negative
HR	66	19	Flat	68	78	75	75	Negative
GB	47	38	High Tone	35	50	65	68	Negative
MB	50	18	Flat	55	63	63	58	
JM	42	17	Flat	58	53	45	48	
JK	31	20	Flat → High Tone	30	38	43	55	Negative
EB	78	15	Flat	55	55	55	65	Negative
PS	51	35	Basin	23	40	48	28	Negative
JC	47	21	Flat	50	50	58	75	
PH	58	35	High Tone	33	45	70	75	
LC	24	13	Flat	80	85	75	65	Negative
KP	12	9	Basin	18	40	50	35	
OM			High Tone	40	52	55	70	

hearing loss progressing in adult years which are well described. These are more easily identified because of other associated syndromes. These syndromes will not be discussed here; the interested reader is referred to a textbook by Bruce W. Konigsmark and Robert J. Gorlin, soon to be published.[6]

Diagnosing Genetic Adult Hearing Loss. In the practice of otology, we encounter many patients with progressive sensorineural hearing loss of unknown etiology. If the patients are older, they may be labeled with the nondescriptive term "presbycusis." However, in this study we were especially interested in identifying these problems in young adults, recognizing the problem was not apparent unless the speech reception threshold (SRT) had reached, generally, a level of 40 dB or higher. The audiometric patterns in this group were, in the main, flat or basin shaped with fairly good speech discrimination. Some of these patients were misdiagnosed by others or could easily have been misdiagnosed as having pure cochlear otosclerosis. Polytomography ruled out this theoretical possibility. Some patients had positive family histories of similar auditory involvement; others did not. For those who had an absence of a positive family history, having ruled out all possible extrinsic causes, (*e.g.*, drugs, trauma, noise, infection) we were, by process of exclusion, left with an intrinsic cause, genetic sensorineural hearing loss.

These patients were selected as a random sampling. Thus, no inferences can be drawn as to incidence although such studies are highly worthwhile. Twenty-two patients from 18 families are represented in Table II. All of these patients had completely normal otological examinations with the exception of their abnormal audiograms. No significant history of noise exposure, trauma,

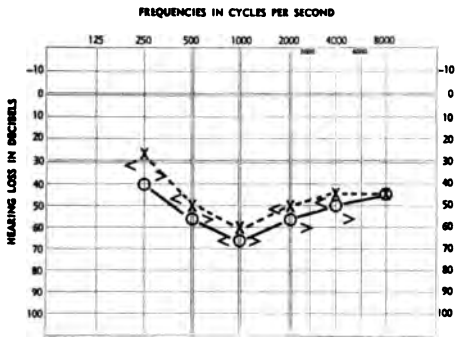

Fig. 1. Audiogram (MB.)

ototoxic drugs, or significant illnesses could be detected by careful history in any of these patients, all of whom were considered reliable historians.

Several variables were found in these patients, including age of onset of symptomatic hearing loss which varied from childhood to the late thirties. Fifty percent of patients had symptomatic onset between the ages of 15 and 30 years of age. These patients also demonstrated a variety of audiometric patterns of loss, but most had a flat or basin-type audiogram. A number of patients, who had hearing loss with similar characteristics, onset in young adult years, often with similar family histories, are not included in this report because of superimposed middle ear or other problems or because of a questionable history of trauma or noise exposure. It is likely, however, that these additional patients also had genetic hearing loss. Further, other patients with probable genetic hearing loss were simply not identified for this study.

CASE REPORTS

The following five patients are representative and characteristic of the different ways in which hearing loss presented in this group.

Case 1. M.B., a 50-year-old female,

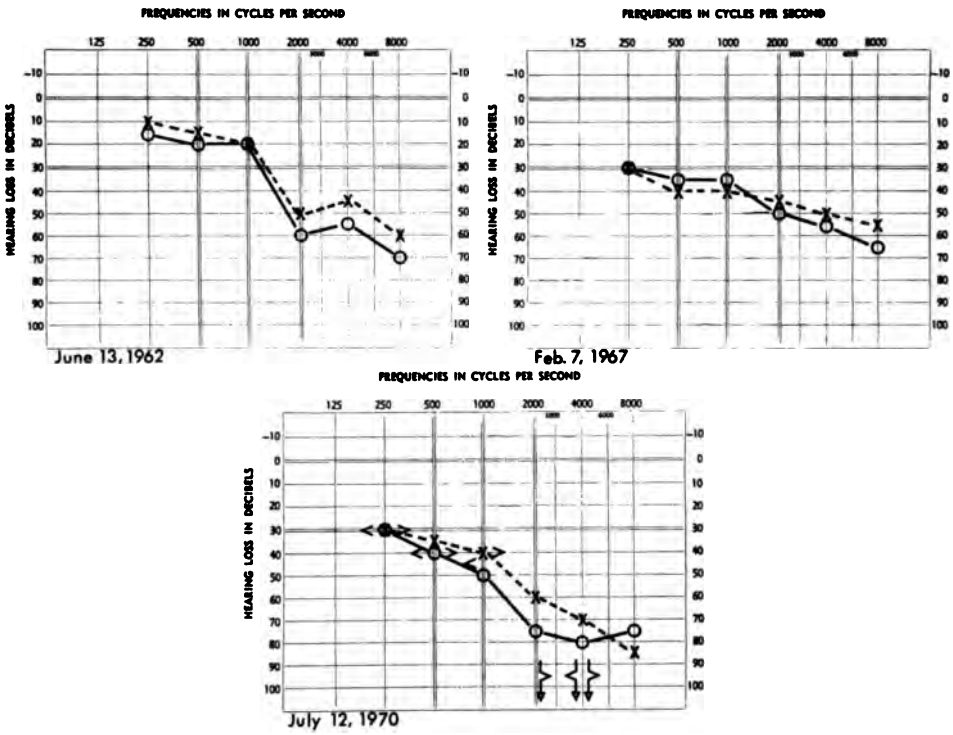

Fig 2. Three successive audiograms, over a period of time, showing progression of loss. (PH)

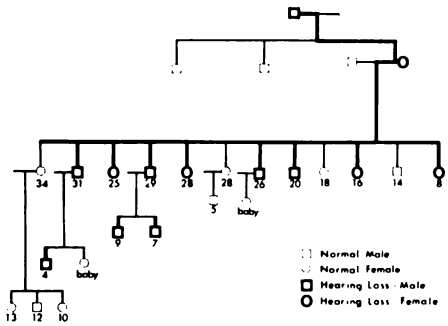

Fig. 3. Family tree of D.K.M. Affected family members (dark lines) show basin-shaped sensorineural losses of moderate to severe degree. Temporal bone tomograms are normal on all family members studied.

the third of 11 children, noted onset of symptomatic hearing loss at age 18. Four of the 11 children in her family developed symptomatic hearing loss before the age of 30. The patient had taken no ototoxic drugs, and there was no history of significant noise trauma or temporal bone trauma (Fig. 1). Temporal bone polytomography was normal, showing no abnormality of the osseous labyrinth.

Case 2. P.H. is a 58-year-old male with hearing loss of symptomatic onset at age 35. Three successive audiograms (Fig. 2) show progressive hearing loss in the high frequencies. It is of interest that the initial high-frequency loss eventually assumes a flatter configuration. The patient's 93-year-old father recalls that his own hearing loss began at about age 40. Again, there is no history of ototoxic drugs, trauma, or noise exposure. Temporal bone polytomography was normal.

Case 3. D.K.M., a 25-year-old female clerical worker, is one of eight siblings with a similar hearing loss in a family of 12. Figure 3 shows a family tree for this patient. This patient's audiogram (Fig. 4) is typical for the family with the greatest loss in the low- to mid-range. It is of interest that D.K.M's affected siblings appear to have onset of hearing loss at a younger age than the preceding generation. Temporal bone polytomography of D.K.M. and other members of her family have been normal.

Case 4. P.S. is a 51-year-old male real estate agent with onset of hearing loss at age 35. His audiograms show a basin-shaped loss with more involvement for the midfrequencies. Examination and history were otherwise negative. Temporal bone polytomography was normal (Fig. 5).

Case 5. G.P. was a female patient who died October 13, 1965, at the age of 52. Her case represents, to our knowledge, the first described temporal bone findings in a case of genetic, adult, progressive sensorineural hearing loss.[21]

CLINICAL INFORMATION

This patient had a history of bilateral hearing loss since late childhood. There was a strong history of deafness, and the patient's mother and one sister also

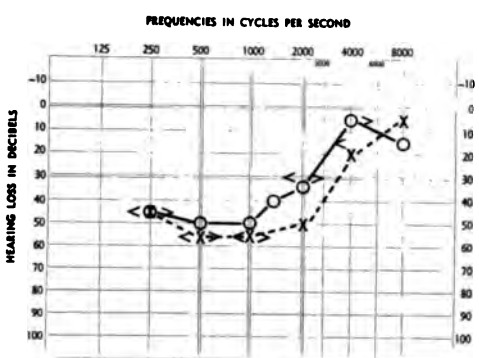

Fig. 4. Audiogram (D.K.M.)

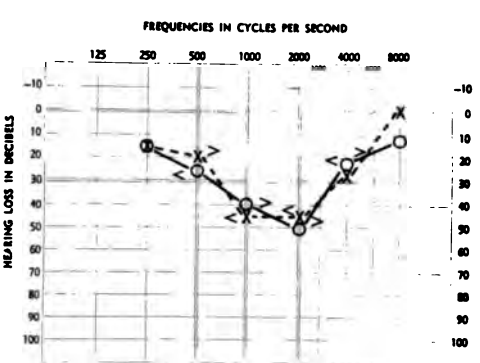

Fig. 5. Audiogram (P.S.)

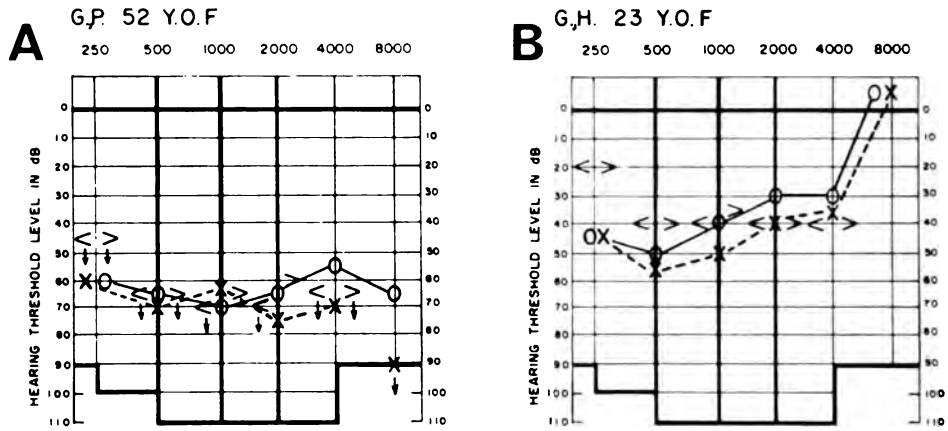

Fig. 6. A) Mother's audiogram (G.P.). B) Daughter's audiogram.

had what was considered to be either congenital deafness or deafness occurring during childhood. This patient had noted bilateral, severe tinnitus, especially over the past many years, decreasing somewhat in recent years. The hearing progressively worsened, and during the past few years she had worn binaural aids with adequate results. There was no history of acoustic trauma, maternal rubella, severe infection, or other causes to suggest other nongenetic types of congenital or acquired deafness. An exploratory tympanotomy was done by another otolaryngologist in an apparent attempt to rule out a diagnosis of stapes fixation and cochlear otosclerosis. None was found. The patient had two daughters, one of whom, at the age of 23 years, has the same difficulty. Otological and audiological information was available for this daughter. The audiogram revealed a bilateral, relatively flat sensorineural hearing loss at approximately a 40-45 dB level, with a rise at 8 kHz (Fig. 6A, B).

Complete physical examination revealed no associated congenital or genetic lesions. The patient received a careful otological and audiometric examination which was negative with the exception of hearing dysfunction. This patient's last audiogram was approximately ten months prior to death (Fig. 6A), demonstrating a severe, flat sensorineural loss around 65 to 70 dB with discrimination scores of 60% and 68% using phonetically balanced maximum words. The patient had developed carcinoma of the breast two years prior to death. She had a mastectomy but developed metastases throughout the body and finally died. There were skull metastases without evidence of temporal bone involvement. She was treated with chemotherapeutic agents and had large doses of irradiation to the brain prior to death.

TEMPORAL BONE HISTOPATHOLOGY

The temporal bones were removed seven hours after death. The same findings were present on both sides and are described together.

Middle Ear and Mastoid. There were some slight chronic changes in the middle ear mucosa in the region of the round window niche, characterized by secretory elements with thickened mucosa. Otherwise, the middle ear and mastoid were normal.

Inner Ear. Osseous Labyrinth: The osseous labyrinth appeared normally developed throughout. There was no evidence of otosclerosis. Membranous Labyrinth: The labyrinth was in a fairly good state of preservation. The vestibular labyrinth was essentially normal in appearance. The saccular wall appeared somewhat collapsed although the macula of the saccule appeared

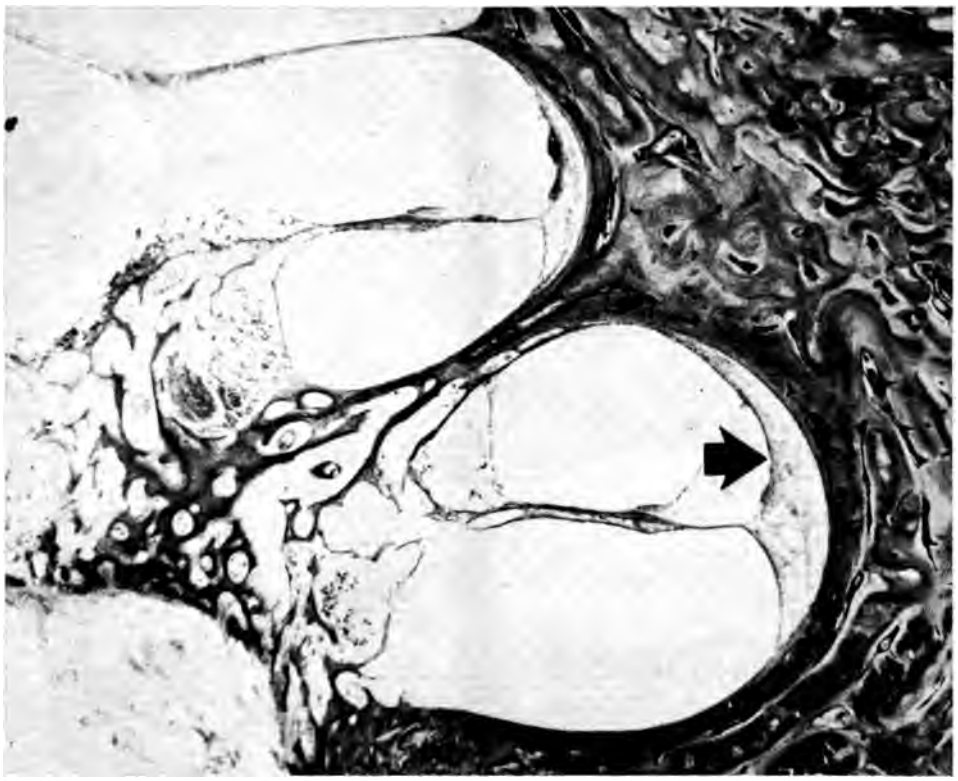

Fig. 7. Temporal bone of mother (G.P.). Note strial atrophy in basal turn (arrow).

normal, as did the utricle. The pathological findings of interest were located primarily in the anterior membranous labyrinth. There was complete loss of the organ of Corti in the basal turn. Corti's organ could be identified in the apex and in certain areas of the middle turn but was seen largely as a clump of cells. Hair cells and other elements could not be distinguised. The tectorial membrane appeared shrunken. Associated with these changes, there was a normal-appearing spiral ligament in all turns. The stria vascularis appeared markedly atrophic or missing in a spotty distribution. The stria was better seen in certain areas of the upper cochlear turns but had severely degenerated in the basal turn. In some areas Reissner's membrane appeared slightly collapsed, as in the upper basal turn. This may have been related to histological preparation. Neural Structures: There was a marked loss of spiral ganglion cells, especially well seen in the upper basal turn area, as well as in the lower basal turn and hook area (Fig. 7). In some places there appeared to be as much as an 80% loss of ganglion cells. The spiral ganglion canal of the apex appeared to contain relatively normal numbers of ganglion cells. The loss of ganglion cells was more marked on the right than on the left ear. Peripheral dendrites appeared missing in proportion to the loss of ganglion cells. Axons and ganglia within the internal auditory canal (IAC) appeared normal.

Summary of Pathological Findings. This patient had many cochlear findings which would account for the sensorineural hearing loss including: loss of the organ of Corti, especially in the basal turn; marked degeneration of the stria vascularis in an irregular distribu-

Fig. 8. Temporal bone pathology (PM). Note strial atrophy (arrow).

tion; and loss of ganglion cells more marked in the basal turn.

The pathological correlate of atrophy of the stria vascularis has been described and substantiated by Schuknecht and Ishii[22] in cases of presbycusis. In a study of nine patients with slowly progressive hearing loss and flat audiometric patterns, they established the finding of atrophy of the stria vascularis. They attributed the uniform involvement of all frequencies to biochemical and bioelectrical alterations in endolymph. In 1974, Schuknecht described 160 ears from 101 individuals which showed slowly progressive hearing loss by history or audiograms and had no known cause for loss by history or examination. Strial atrophy was thought to be the principal lesion in 52 ears of 35 individuals.[23]

We analyzed our temporal bone collection for older patients with no hearing loss or with no apparent explanation for their hearing loss, such as infection or trauma. One hundred and thirty-five cases were studied of patients older than 45 years of age, includ-

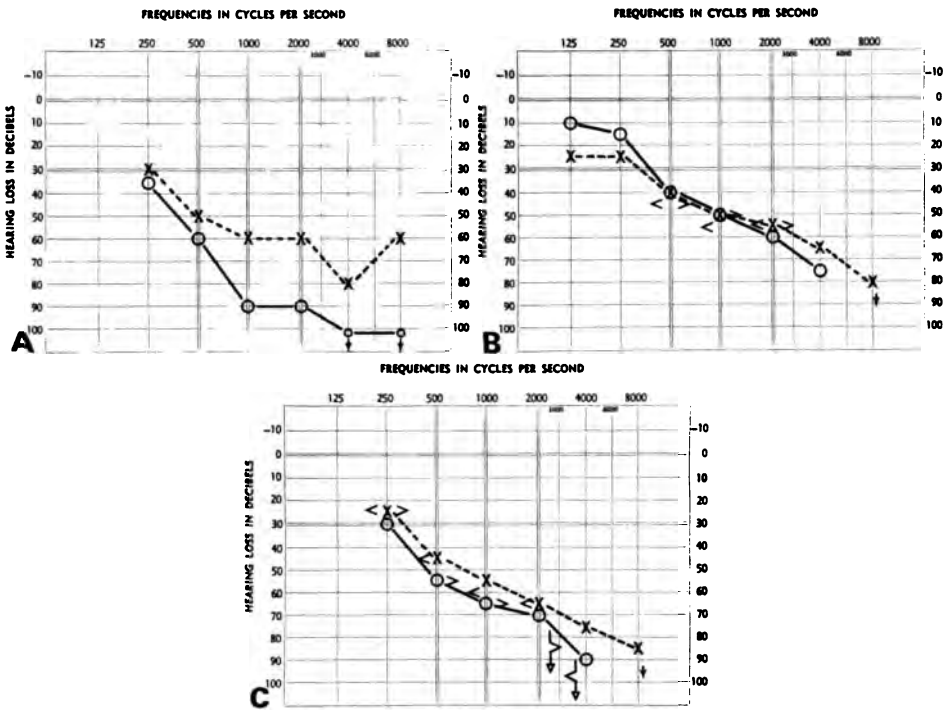

Fig. 9. A) Audiogram (P.M.) B) Audiogram (I.K.) C) Audiogram (C.B.)

ing 115 cases in patients 60 years or older. The pathological features are summarized according to findings in the stria vascularis and other changes (Fig. 8). Temporal bones of 21 cases showed pathological changes including changes of the cochlear duct, organ of Corti, ganglion cells, and stria vascularis. Thirteen cases showed bilateral pathology. Atrophy of the stria vascularis was seen in 18 cases and appeared marked or severe in seven cases. "Severe" refers to complete absence of the three layers of the stria vascularis in one or more cochlear turns. "Moderate" refers to atrophy of the epithelial or middle layer of the stria in one or more turns. In addition to these pathological findings, audiograms were available on some patients (Figs. 9A, B, C, 10, and 11).

DISCUSSION

It is our belief that genetic hearing loss is far more prevalent in adults than is currently realized. In the practice of medicine every attempt should be made to diagnose a disease or disorder according to etiology before steps are taken toward treatment or rehabilitation. It is our firm conviction that too many adult patients with sensorineural hearing loss are not properly diagnosed and are unaware of the nature of their problem or its potential effect on offspring in future generations. In the diagnosis of progressive sensorineural hearing loss, every attempt should be made to identify extrinsic causative factors. Having done so, we are left with the likelihood of an intrinsic problem, and genetic hearing loss should strongly be considered.

Our study indicates that the two most important diagnostic considerations are the history and the audiometric configuration, including audiometric changes over time. The history, with all of its imperfections, is still our most important tool. Genetic hearing loss associated with other abnormalities (syndromes) is more easily identified than

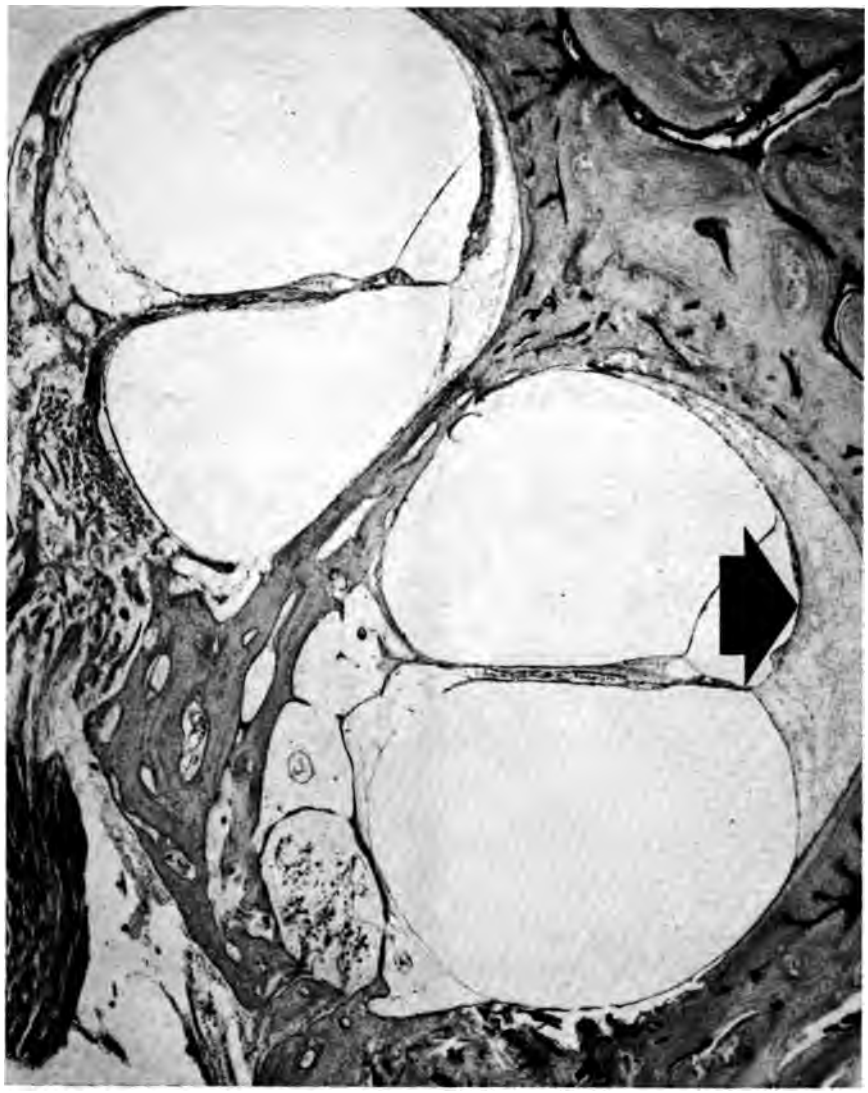

Fig. 10. Temporal bone pathology. Note strial atrophy in basal turn (arrow).

genetic hearing loss occurring alone. This latter category, although more nebulous, represents by far the most common type of genetic adult hearing loss. A positive family history is, of course, helpful, but a negative family history does not preclude the diagnosis of genetic hearing loss because of such considerations as lack of information or forgetfulness on the part of the patient, lack of penetrance, and mutations occurring over generations. Also, although otosclerosis is the best understood example of adult genetic hearing loss, it is not uncommon to have a confirmed diagnosis at the time of surgery with no family history of involvement.

The audiometric picture is a flat or basin-shaped curve with fairly good discrimination. A very interesting and important observation in our patients is that patients in the early course of their problem may demonstrate a predominant low-or high-frequency loss,

Fig. 11. Temporal bone pathology. Note strial atrophy in basal turn (arrow).

but over a period of time, a flat audiometric pattern evolves. If this finding is confirmed, it has diagnostic significance. It might be added here that patients with genetic hearing loss are subject to all of the environmental factors which affect anyone else. Thus, as the patient grows older, there is no reason, for example, that the effects of environmental noise cannot superimpose themselves on a genetically induced loss, thus altering the audiogram.

Presbycusis is not the specific subject of this discussion, but it relates to it. The term "presbycusis" is a nondescriptive catch all term referring to the vague concept of aging deafness. It is too easy to categorize hearing loss in older patients as "presbycusis," thus negating the need to apply careful, differential diagnostic methods as we are more apt to do for younger patients. Hopefully, some day we will be able to retire the term "presbycusis" with its due dignity,

allowing health professionals to properly diagnose sensorineural hearing loss in older adults according to extrinsic or intrinsic etiologies as is done with all other patients. Genetic, adult sensorineural hearing loss can become manifest as a hearing problem at any age; childhood, younger, middle, or old adulthood. In all cases, the initial onset of hearing loss occurs years prior to the patient's complaint because of the insidiously progressive nature of its occurrence. In this study, we concentrate on genetic hearing loss in young adulthood, recognizing that these patients could be identified as having presbycusis later in life. Indeed, Cawthorne and Hinchcliffe employed the term "abiotrophy" referring to premature presbycusis although he fully understood this to be a manifestation of genetic hearing loss.[24]

This study is largely exploratory in nature and suggests the need for more definite studies of genetic sensorineural hearing loss in adults of all ages, including, especially, those currently diagnosed as "presbycusis." Laboratory studies would be beneficial, but there is a more urgent need for clinical, otological, and audiological studies. In the meantime, as diagnosticians concerned with the hearing welfare of our patients, we should consider genetic hearing loss in every patient with progressive sensorineural hearing loss accompanied by a flat or relatively flat audiometric pattern.

Request for reprints should be sent to Michael M. Paparella, M.D., Dept. of Otolaryngology, University of Minnesota Medical School, Minneapolis, Minnesota 55455.

REFERENCES

1. *Characteristics of Persons with Impaired Hearing.* United States Ser 10:No. 48, National Center for Vital and Health Statistics, November, 1968

2. Zwaardemaker: Ueber das presbyakustische Gesitz an der unteren Grenze unseres Gehoers. Arch Klin Exp Ohren Nasen Kehlkopfheilkd: 35:299, 1893

3. Chung CS, Robinson OW, Morton NE: A note on deaf mutism. Ann Hum Genet 23:357-366, 1959

4. Sank D, Kallman FJ: The role of heredity in total deafness. Volta Rev 68:461-470, 1963

5. Konigsmark BW: Hereditary deafness in man. N Engl J Med 281:713-720, 1969

6. Konigsmark BW, Gorlin RJ: *Hereditary Deafness and Deafness Syndromes.* To be published, 1975

7. Albrecht W: Über die Vererbung der konstitutionell sporadischen Taubstummheit der hereditären labyrinthschwer Hörigkeit und der Otoscleroses. Arch Klin Exp Ohren Nasen Kehlkopfheilkd 110:15-48, 1923

8. Stephens FE, Dolowitz DA: Hereditary nerve deafness. Am J Hum Genet 1:37-51, 1949

9. Johnsen S: The heredity of perceptive deafness. Acta Otolaryngol (Stockh) 42:539-552, 1952

10. Huizing EH, van Bolhuis AH, Odenthal DW: Studies on progressive hereditary perceptive deafness in a family of 355 members. Acta Otolaryngol (Stockh) 61:35-41, 161-167, 1966

11. Lenzi P: Sulle sordità ereditarie (studio genetico e clinico di un ceppo familiare). Arch Ital Otol 80:453-485, 1969

12. Nance WE, Sweeney A: Genetic factors in deafness of early life. Otolaryngol Clin North Am 8:1, 19-48, 1975

13. Teig E: Hereditary progressive perceptive deafness. Acta Otolaryngol (Stockh) 65:365-372, 1968

14. Konigsmark BW, Mengal MC, Berlin CI: Familial low frequency hearing loss. Laryngoscope 81:759-771, 1971

15. Vanderbilt University Hereditary Deafness Study Group: Dominantly inherited low-frequency hearing loss. Arch Otolaryngol 88: 242-250, 1968

16. Mårtensson B: Dominant hereditary nerve deafness. Acta Otolaryngol (Stockh) 52:270-274, 1960

17. Williams F, Roblee LA: Hereditary nerve deafness. Arch Otolaryngol 75:69-77, 1962

18. Konigsmark BW, Salman S, Haskins H, *et al*: Dominant midfrequency hearing loss. Ann Otol Rhinol Laryngol 79:42-54, 1970

19. Mohr J, Mayeray K: Sex-linked deafness of a possibly new type. Acta Genet (Basel) 10:54-62, 1960

20. Livan M: Contributo alla conoscenza dula sordità ereditarie. Arch Ital Otol 72:331-339, 1961

21. Paparella MM, Sugiura S, Hoshinot: Familial progressive sensorineural deafness. Arch Otolaryngol 90:44-51, 1969

22. Schuknecht HF, Ishii T: Hearing loss caused by atrophy of the stria vascularis. J Otol Jap 69:1825-1833, 1966

23. Schuknecht HF: Atrophy of the stria vascularis, a common cause for hearing loss. Laryngoscope 84:10, 1777-1821, 1974

24. Cawthrone TE, Hinchcliffe R: Familial perceptive deafness. Pract Otorhinolaryngol (Basel) 19:69-83, 1957

DISCUSSION

EUGENE L. DERLACKI, M.D. (Chicago, Illinois): I wanted to make just a couple of comments.

We did a study on a hundred cases at Northwestern University Medical School with the configurations which Dr. Paparella presented, with positive family histories, because of our bias toward the concept of cochlear otosclerosis.

Dr. Valvassori did the polytomography not knowing anything about the history of the patient, and I did the presumptive diagnoses from the otologic point of view. Our correlation rate, I am sorry to say, was not too high as far as identification by otologic diagnosis and radiographic diagnosis.

Nevertheless, we found that we had so-called positive x-ray findings in approximately 20% of the cases submitted as sensorineural unknowns in adults.

In considering another point along this line, we have studied patients who have been in a period of stable hearing whose x-rays were negative for evidence of cochlear otospongiosis. When the hearing went into a period of active degeneration, repeat x-rays showed the findings of active cochlear otospongiosis that have been well described by Valvassori in the past.

I do not like the term progressive in all of these cases, because many of those we have seen have been followed for years, and have remained at the same hearing level. This agreed both with the patient's subjective evaluation and our objective serial audiometry over a period of a number of years in patients with a strong genetic history.

Thank you, Mike, for a stimulating paper.

JACK L. PULEC, M.D. (Los Angeles, California): I enjoyed the paper very much and I was interested in two points.

One, the change in title and that is to what my question is directed.

We have been aware in the last few years of the importance of identifying the apparent hereditary progressive loss, sometimes fluctuating loss in children, because we find that the progressive and often total loss can often be prevented if an endolymphatic subarytenoid shunt is done early enough.

I was interested in your cases occurring apparently in young adults where there was no endolymphatic hydrops in any of the specimens that I saw, and although your audiometric patterns would be the same as these children that we search for, would you comment on whether there is any way you could differentiate these clinically with this type, obviously the type with stria vascularis degeneration might not be the type to respond to shunt surgery.

MICHAEL M. PAPARELLA, M.D. (closing): First as to Dr. Derlacki's comments, yes, indeed I would hope that we would all look at our patients with somewhat of a jaundiced eye. There seems little doubt in my mind that the patients under study indeed did *not* have otosclerosis as this was ruled out. What we did identify was a progression of a sensorineural hearing problem over time. I think by process of exclusion we are talking about genetic sensorineural hearing loss which, in our own practice, is not at all a rare problem, but a relatively common one. And, I would urge all of you to look for similar examples in your practice.

Jack, the patients we are referring to do not have cochlear hydrops. They do not have a fluctuant hearing loss. It is a steady progressive problem. Certainly any kind of surgery is to be abhorred for this group of patients.

We are talking about another situation in adults with a steady sensorineural hearing loss on a genetic basis.

PAGET'S DISEASE OF THE TEMPORAL BONE

ABSTRACT*

GEORGE T. NAGER, M.D.

BALTIMORE, MARYLAND

Osteitis deformans Paget is a fairly common, often progressive disease of bone, which may be considered as a heritable abiotrophy of the collagen matrix of bone. Recurrent episodes of bone resorption followed by exaggerated attempts at repair result in a structurally weakened, deformed skeleton of increased bone substance. Autopsy studies of unselected patients, older than 40 years, reveal an overall incidence of about 3 to 3.7%. The disease is rarely encountered under the age of 30 to 40. Men are more often affected than women, but the difference is slight.

Osteitis deformans appears in hospital practice more often as an incidental finding. A large percentage escapes clinical detection. Only about 15% of patients exhibit the advanced form of the disease with the well recognized skeletal changes, the striking deformities of the long bones, the progressive kyphosis with shortening of stature, and the enlargement of the skull.

Three phases may be recognized histologically: 1) an initial phase of osteoclastic resorption of existing bone; 2) a subsequent phase of osteoblastic regeneration of primitive bone; and 3) a final phase of "mosaic" bone replacing the original structure.

Whenever osteitis deformans affects the skull, the temporal bones are in general also involved. Whereas, the extent of the involvement varies to some degree with each case, the structural changes within a given pair of temporal bones are very similar. Osteitis deformans may cause alteration of position, increase in size and change in architecture of the petrous pyramid and other structures of the temporal bone. It may cause tortuosity and narrowing of the external and constriction of the internal auditory meatus, distortion of configuration of the cochlea, constriction of the tympanic cavity, relaxation of the tympanic membrane and impingement upon the middle ear ossicles. Paget's disease may give rise to distortion of the oval window with jamming and immobilization of the stapes and it may cause actual stapedial ankylosis. It may lead to severe distortion or even total obliteration of the round window niche and to marked elevation of the floor of the hypotympanum. Involvement of the tractus spiralis foraminosus, of the cochlear modiolus and of the macula cribrosa of the inferior and superior vestibular area may lead to concentric narrowing of the foramina and longitudinal canals with crowding and even strangulation of the nerve fibers in these locations.

The morphological changes encountered in the cochlea include varying degrees of atrophy of receptor cells, nerve fibers, ganglion cells and of the stria vascularis throughout all turns, increasing towards the end of the lower basal turn. Similarly, the vestibular

---

From the Otological Research Laboratory, Department of Laryngology and Otology, the Johns Hopkins University School of Medicine and Hospital.

This study was supported by Grant Number 5 R01-NS 02182-16 from the National Institute of Neurological and Communicative Disorders and Stroke, U.S.P.H.S.

* The complete manuscript was published as Supplement 22, Vol. 84, July-Aug., 1975, No. 4, Part 3, with *The Annals of Otology, Rhinology and Laryngology.*

labyrinth discloses partial atrophy of the first order neuron. It appears that the morphological changes in the cochlea and labyrinth are related to the extent of the bone transformation process, whereby, the actual mechanism for the sensorineural hearing loss and vestibular dysfunction still requires further clarification.

Temporal bones with widespread active Pagetoid bone transformation reveal a great increase in blood flow, evidence of arterio-venous shunting, often across large venous lakes, and marked enlargement of the jugular bulb.

Benign and malignant neoplasms may be observed in several instances. Neurinomas may originate from nerve fibers in the petrous pyramid, near the otic capsule. Malignant tumors of mesenchymal origin can be encountered in different areas of the petrous pyramid.

Impairment of hearing in Paget's disease is present in about 30 to 50%. It is sensorineural in nature and of cochlear origin. It is often associated with a low frequency conductive loss. Tinnitus and vertigo occur in about 20 to 25% of these patients.

OPERATIVE TREATMENT OF SURGICAL LESIONS WITH OBJECTIVE TINNITUS

PAUL H. WARD, M.D. RICHARD BABIN, M.D.
THOMAS C. CALCATERRA, M.D. H. R. KONRAD, M.D.
LOS ANGELES, CALIFORNIA

SUMMARY – This article discusses the importance of the evaluation and diagnosis of objective tinnitus (tinnitus heard by the patient and the physician). Intracranial arteriovenous communications and vascular anomalies are most frequently responsible for the tinnitus and auscultable bruits and are highly amenable to current surgical treatment. While the otolaryngologists may initially see these patients and be responsible for the diagnosis of their problem, the surgical correction of the intracranial lesions is usually the province of the neurosurgeon. Illustrative cases of extracranial causes are presented. Particular emphasis is placed on the diagnosis and treatment of venous hum. Formerly called cephalic bruit and essential objective tinnitus, venous hum is now a recognized nosological entity that is amenable to treatment by ligation of the internal jugular vein.

Tinnitus at a subliminal level is common to all of us. Ringing, roaring, hissing, or other noise sensations are experienced whenever we listen for them in quiet surroundings or place a seashell over our ear. The etiology of the tinnitus as a chief complaint often defies elucidation even after extensive medical evaluation. The small group of cases of objective tinnitus, that is, where the physician can also appreciate by ascultation the presence of this symptom or sign, is of great importance. Accurate diagnosis in these cases is essential since most objective tinnitus is amenable to therapy, and in some instances, failure to treat the cause appropriately can lead to progression of the disease responsible for the symptom. The successful treatment of the various causes of objective tinnitus depends upon a thorough understanding of the anatomy and physiology involved and may require the cooperative efforts of several disciplines, especially true in the vascular causes.

Objective tinitus in the broadest sense represents all noise produced by an individual's body which is loud enough to impinge on his consciousness. It differs from the more common intrinsic tinnitus in that it represents true sound wave energy, rather than just a sound sensation. Body sounds under normal circumstances are sublimated by many factors, including structural considerations in the middle ear and the skull, cochlear thresholds and adaptation, and the projection of sound energy away from the temporal bone. These mechanisms can break down in several ways: by an increase in the perception of a normal sound, by an increased intensity of normal sounds, or by the production of abnormal sounds. If either of the latter two occurs, a tinnitus results which may be documented by another observer, a phonocardiogram, or a tape recorder. It is amazing how little we are aware of the numerous body vibrations secondary to muscular activity, joint motion, respirations, voice, and vascular pulsations. All of these sounds in the close vicinity of the ear, comprise an ever-present baseline noise level. Remarkably sophisticated mechanisms have evolved in man which attenuate this high level of persisent noise input into the ear. Whether the failure to perceive this noise is due to peripheral factors or to central adaptation is not known.

From The Department of Surgery/Division of Head and Neck Surgery, The University of California School of Medicine, Los Angeles, California.
This work was supported in part by Grant USPHS #NS09823-04

The generation of objective tinnitus appears to be due either to increase in the loudness of normal sounds or to the production of abnormal sounds. The latter problem will be considered first.

The Production of Abnormal Sounds. The most common cause of objective tinnitus of the vascular type is an arteriovenous (A-V) malformation in the posterior fossa.[1] Usually branches of the occipital artery and transverse sinus are involved since there are numerous communications between these vessels. Frequently no history of trauma precedes their presentation. Branches of the internal carotid artery and vertebral artery may also produce A-V fistulae. Less common causes of arterial objective tinnitus include: vascular abnormalities in the middle fossa between the posterior branches of the middle meningeal artery and the greater petrosal sinus; cervical lesions between the internal maxillary artery and vein and cerebral angiomas; cervical and cerebral angiomas; and giant cell tumors of the mandible. Infrequent, but of serious importance, are the arteriovenous communications between the internal carotid artery and the cavernous sinuses, which almost always follow severe head trauma.

The pulsatile tinnitus in these cases is noted by the patient and physician and palpation often reveals a significant bruit. Headaches are a frequently associated complaint when the lesion is intracranial. Approximately 50% of the patients will have nonlocalizing neurologic signs, such as papilledema. In a small percentage of patients with pulsatile mass behind the ear, the tinnitus may be reduced by pressure over the lesion or by compression of the carotid artery. If the left to right shunt is sufficiently large, a high output failure syndrome may result. In such cases, pressure over the lesion may dramatically reduce the tachycardia that is part of the syndrome.

Elucidation of the underlying lesion responsible for the tinnitus and the planning of definitive therapy is dependent upon good selective angiography. If a single branch of the external carotid system is involved, ligation of this vessel and excision of the lesion should eradicate the symptoms. If the internal carotid also contributes to the tinnitus, the symptoms may be expected to return as the secondary system dilates and flow increases. If the vertebral system is involved as well, only extensive ligation of feeding vessels and excision of the communicating vessels can be expected to eliminate the problem. As a general rule, the vascular malformation at surgery is considerably more extensive than it appeared to be on arteriography. Complications of these lesions include high output cardiac failure, neurological defects, intracranial hemorrhage and bleeding diathesis secondary to intercapillary coagulopathy, and fibrinolysis.

Other less common causes of an objective tinnitus are atheroscleromatous plaque in the carotid arteries and Eagle's syndrome (elongated styloid process or calcified styloid-hyoid ligament). This latter condition was first implicated in a cephalofacial pain syndrome involving the distribution of either the external or internal carotids frequently following tonsillectomy.[2] More recently it has been described as a cause of a bruit in the same distribution and objective tinnitus, relieved by excision of the styloid process.[3]

In 1872 Polizer described a patient with pulsatile objective tinnitus associated with rhythmic contractions of the soft palate.[4] Since that time, objective tinnitus has been documented from myoclonic contractions of the tensor vili palatini, the levator vili palatini; the tensor tympani with associated movement of the tympanic membrane, and the salpingopharyngeus and superior constrictor muscles. Less frequently the orbicularis occuli, laryngeal musculature, and diaphragm are involved. Such contractions usually range from 60-200 Hz and thus may be confused with a vascular pulse. Patients are classically young, being in their first three decades of life; older patients within their fourth through eight decades have been reported.[4,5] They often had other associ-

ated significant neurologic problems. The vibrations responsible for the audible sounds appear to be produced by movement of the Eustachian tube orifice. The audible click in some patients is synchronous with the relaxation phase of the myoclonus, the closure at the tube orifice, and an increase in the intratubal manometric pressure.[6]

The etiology of palatal myoclonus has been ascribed to brainstem infarctions, trauma, multiple sclerosis, syphilis, malaria, and neuroses. Specific lesions have been described in the olivary tracts, reticular formation, dentate nucleus, posterior longitudinal bundle, and central tegmental fasciculi.[4,7] Unlike many involuntary movements, palatal myoclonus usually doesn't disappear with natural or barbiturate-induced sleep, coma, hemiplegia, phonation, or caloric stimulation.[8,9] It may disappear with deep inspiration. It may also temporarily disappear on opening the mouth widely, thereby making the diagnosis difficult for those unfamiliar with this entity. Muscle relaxants, decongestants, tranquilizers, psychotherapy, cervical traction, and hypnosis have all been employed with varying therapeutic response. Section of the levator veli palatini muscle and eliciting contraction of this muscle by blowing cold air on the cornea have successfully eradicated the click. Corneal reflexes have been previously shown to stimulate atonic contraction of the tensor tympani.

Increased Loudness of Normal Sounds. One of the most important causes of objective tinnitus that the otolaryngologist should become more familiar with is the venous hum. This entity is continually rediscovered and discussed extensively in the otolaryngology literature under the name of cephalic murmur or essential objective tinnitus (the *essential* implying no cause should be found).[10-14] Hentzer reported 13 out of 24 patients with vascular objective tinnitus were of this type.[14]

It has remained for others to better document and determine the probable etiology of the venous hum.[15-16] Venous hum occurs normally and can be heard over the fontanelle of infants, in the necks of many children, and in some adults. It may be more pronounced in states of increased cardiac output such as thyrotoxicosis, anemia, and pregnancy. In one case, a venous hum in the neck was the clue to an A-V fistula in the posterior fossa with its own separate bruit.[15] Although technically a continuous murmur, it is usually reinforced by arterial flow and appears to the observer and patient as a pulsatile sound synchronous with systole.[17] Venous hum of the neck is characteristically intensified by deep breathing and reduced by the valsalva maneuver. Turning the head toward the opposite side increases the hum. Two factors may be responsible for this. Ipsilateral contraction of the sternomastoid muscle opens the effective bore of the internal jugular vein, increasing return on that side. Furthermore, it has been shown that the hum may be due to the turbulent flow in the internal jugular vein as it bends around the transverse process of the atlas. This angulation is markedly increased as the head is held to the contralateral side.[16] The sound is decreased by turning the head to the ipsilateral side (reducing agulation and venous return) or by pressure on the neck too light to occlude the carotid artery but occluding the internal jugular vein.

Venous tinnitus may be differentiated from arterial bruits by its dependence on head position and sensitivity to light pressure. A normal cerebral arteriogram is essential to the definitive diagnosis in order to rule out other isolated or coexistent vascular anomalies. Another important negative study is venous O_2 saturation (which may be done at the time of a retrograde venogram) which may be normal or show a preponderance of cerebral venous drainage to the ipsilateral side. A new test of value used to predict the optimum level of obstruction to eradicate the tinnitus is shown in Figure 1. A Fogerty catheter with a balloon is used to perform the retrograde venogram. The balloon is inflated at different levels in the internal jugular vein in order to detect the optimal level for ligation.

Fig. 1. X-ray of retrograde internal jugular venogram with Fogerty catheter balloon inflated with opaque material. The catheter balloon can be inflated at different levels to determine the optimal level for ligation. In this patient the venous hum was controlled best when the balloon was inflated at the level of the second cervical vertebra.

While venous hums have been reported to spontaneously regress, none of the patients currently being followed in our series have experienced this phenomena. In patients with severe tinnitus, particularly when it is so loud that it keeps the companion awake, (as in one of the cases to be presented) the simple ligation of the jugular vein appears warranted. The dramatic decrease or cessation of the tinnitus and bruit following ligation is usually permanent although it has been reported to reappear in some patients.[14] The use of a prosthetic device which provides a constant light pressure on the jugular vein was reported in one case by Cary.[18] With or without therapy, the prognosis is better for this group of patients than that of the arterial group.

CASE REPORTS

The common intracranial arterial abnormalities which are responsible for objective tinnitus, while often diagnosed by the otolaryngologist, are usually within the surgical province of the neurosurgeon, so they will not be presented here. The following are informative and illustrative examples of some of the types of problem cases with extracranial objective tinnitus recently managed successfully and unsuccessfully as reported.

Case 1. A 16-year-old Caucasian female had been in good health all her life until approximately one year ago when she noted pain in the first molar tooth on the left and pulsatile tinnitus initially lasting for just a few seconds following vigorous exercise. She also noted bleeding of the peridontal tissue on this side of the mouth.

General physical examination was within normal limits. She had dilated vessels on the left anterior floor of the mouth. No pulsatile lesions were palpable. Auscultation revealed a loud continuous machinery-type bruit heard over the mastoid tip, angle of the mandible, and submental area. Examination of the ears was within normal limits. A panorex x-ray of the mandible showed extensive erosion of the mandibular canal on the left side (Fig. 2). This bruit was recorded by phonocardiography for illustrative purposes (Fig. 3).

Fig. 2. Panorex x-ray of patient with objective tinnitus caused by a large arteriovenous abnormality eroding the mandible on the left side.

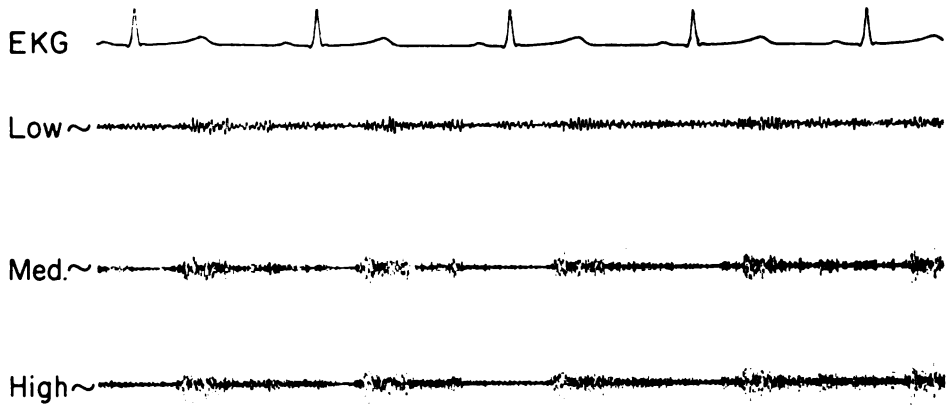

Fig. 3. Photograph of phonocardiograph of bruit emanating from A-V malformations in mandible of Case No. 1. Recording taken in front of left ear shows continuous bruit and the various low, medium, and high frequency components.

Bilateral external and left internal carotid arteriography showed a left mandibular lesion consistent with an A-V malformation with blood supply predominantly from the left facial artery and internal maxillary and minimal supply from the right facial artery. Following arteriography, the patient underwent embolization of both external facial arteries with Gelfoam.®* The left internal maxillary artery had an unfavorable origin and could not be embolized. The patient tolerated this procedure well and had immediate cessation of pulsatile tinnitus. The facial and mastoid bruit could no longer be heard. She did well for several weeks but there was a gradual return of the tinnitus and bruit. She had repeated arteriograms with three additional embolizations with Gelfoam,® followed by plastic spherules during the ensuing seven months after increase in the size of the malformation and bone destruction was noted. In view of the initial success in eradication of the tinnitus and bruit, it was elected to obliterate the vessels permanently with ferromagnetic Silastic®** embolization. This material is held in place by a powerful electromagnet until vulcanization occurs. This procedure was complicated by some of the material entering the tissues of the cheek with resulting mottling of the skin. The patient had several teeth extracted, and her bruit persists. Additional obliterative procedures are contemplated prior to surgical resection, if it becomes necessary.

Case 2. A 34-year-old, mildly obese, Caucasian female presented with a six-week history of pulsatile tinnitus in the left ear and a three-week history of an enlarging neck mass below and around the left ear. The patient related she had had sustained neck trauma during her most recent delivery (by forceps) but had previously noted only transient pain and a few prominent blood vessels on her left neck. She was five months pregnant at the onset of the tinnitus and had had six previous pregnancies, two full term without similar symptoms. There was no history compatible with heart failure or a coagulopathy.

Physical examination revealed a 5 x 7 cm soft mass lesion overlying the left mastoid and upper sternocleidomastoid muscle. There was a diffuse telangiectasia in the skin overlying the mass (Fig. 4). A thrill could be palpated and a loud systolic bruit could be auscultated over the mass and the left ear, which was diminished by pressure over the carotid. The tympanic membranes were clear and freely movable bilaterally and the remainder of the patient's examination was unremarkable. Her blood pressure was 106/78; pulse, 80 and regular; the hematocrit, 32%. After consultation with the cardiologist and obstetrician, a left carotid arteriogram was performed. On selective catheterization of the external carotid, a diffuse, large vascular blush was seen along the left aspect of the neck (Fig. 5). The venous phase-emptying channels and vertebral and internal carotid arteries were normal. Skull and cervical spine x-rays were normal. Open biopsy revealed a capillary hemangioma.

By the eighth month of gestation, the mass was 5 x 10 cm, a grade II/VI systolic ejection murmur had appeared at the carotid base, and the tinnitus was more severe. Four months postpartum, the mass was 4 x 5 cm, the telangiectasia had faded considerably, and the tinnitus was gone. The patient was last seen two and one-half years postpartum and with the continued decrease in the size of the mass, she declined elective removal.

Case 3. A 32-year-old female entered with a chief complaint that the ringing in her right

---

* The Upjohn Co., Kalamazoo, Mich.
** Dow-Corning Chem. Co., Medical Products Div., Midland, Mich.

Fig. 4. Photograph of patient with large 5 x 7 cm compressible vascular mass of neck.

ear kept her husband awake at night. The ringing had been present for 18 months and followed a blow to the right mastoid area by a baseball. After the accident the patient had a severe episode of vomiting at which time she stated that she heard a loud pop behind her right ear. The patient dated the onset of her tinnitus to both of these episodes. The patient described her noise as a loud, constant ringing noise which she could eliminate by rotating her head fully to the right or by direct pressure behind the right ear.

Physical examination showed the ears to be normal. There was a high-pitched, pulsating bruit, loudest over the upper one-third of the sternocleidomastoid muscle and the mastoid tip. It could be stopped by mild compression over the sternocleidomastoid muscle. It was exacerbated by turning the head to the opposite side and was diminished by turning the head to the ipsilateral side. Bilateral external carotid, right internal carotid, and right internal maxillary arteriograms showed no abnormalities. A right jugular venogram was performed and was within normal limits. The A-V O_2 difference was within normal limits.

The patient was taken to the operating room, where under general anesthesia a microphone was placed in the right external ear canal and the left neck surgically explored. Selective occlusion of the external carotid, internal jugular vein, and right facial vein were performed independently. Each vessel appeared to decrease the bruit slightly. It was

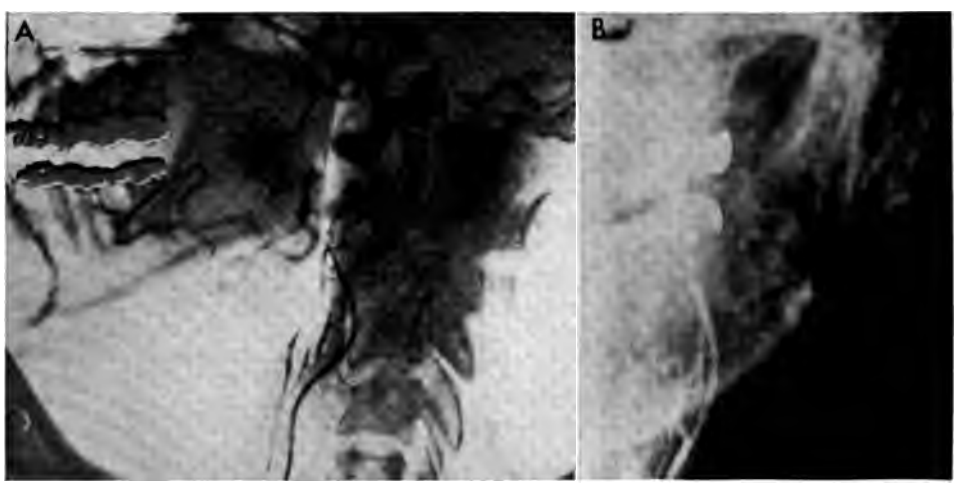

Fig. 5. Left lateral (A) and anterior posterior (B) arteriograms showing the vascular blush of the capillary hemangioma of patient (Case No. 2). Subtraction technique used in (A).

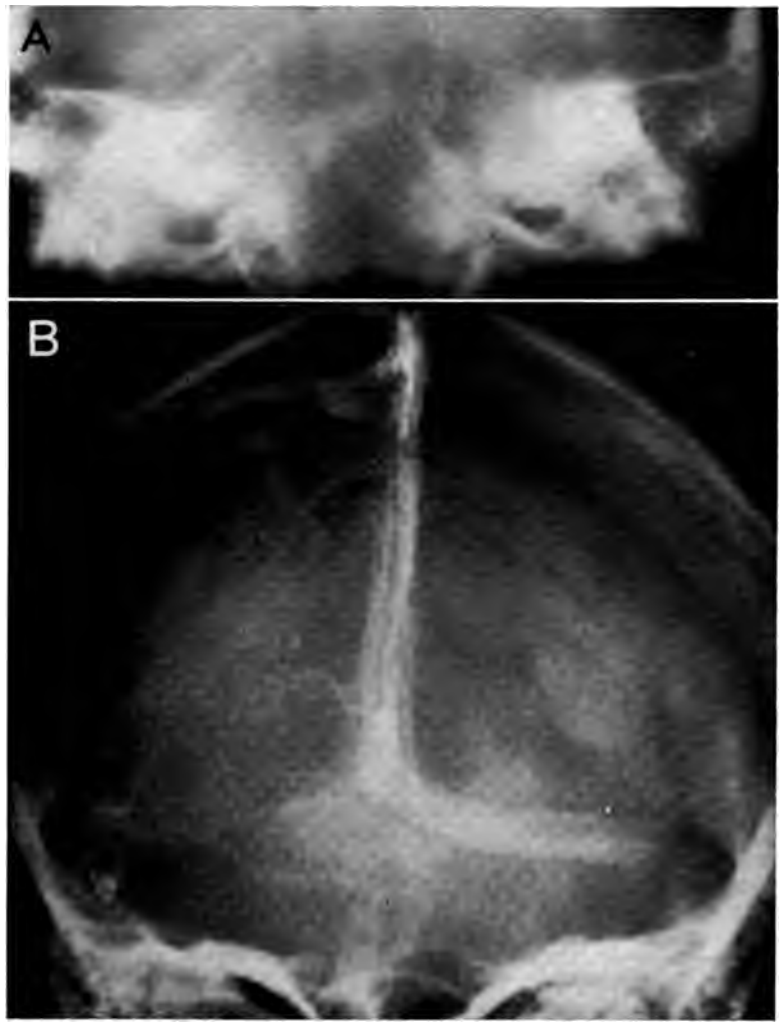

Fig. 6. Laminogram showing enlarged right jugular bulb (A) and retrograde venogram (B) showing dominant right venous drainage system (Case No. 4).

totally eradicated by ligation of the jugular vein. Postoperatively the objective component was no longer audible on auscultation. The patient continued, however, to have a minor subjective component. Two and one-half years after ligation she was doing well without complaints.

Case 4. A 40-year-old obese, Negro female was invovled in an automobile accident two years before her presentation, sustaining a fracture of her right arm and a ruptured spleen and liver. She did not receive any head trauma, and her postoperative course was complicated by pneumonia. Seven months thereafter, she noted the gradual onset of pulsatile tinnitus in her right ear. It was present first only at night. Later it became louder, and she learned that turning her head to the right stopped the noise. She began sleeping on her right side. The tinnitus was not affected by lying down. The patient denied ear infections, vertigo, or hypacusis. She had never been pregnant. The symptoms had gradually increased to the time of her presentation.

Physical examination was entirely normal except for a faint pulsatile sound present over the right mastoid and anterior neck. The tympanic membrane was normal and noted not to pulsate. The sound was eliminated by gentle pressure on the anterior neck or mastoid by turning the head to the right. It was increased when the head was turned to the left. An audiogram was essentially normal, and 75 dB of white noise was necessary to mask out the

subjective tinnitus. Mastoid tomograms were normal. Arteriograms were normal and retrograde venogram revealed a dominant right drainage system (Fig. 6). There was concern of possible side effects of ligating the only major vessel of venous return. The patient declined ligation and has continued to live with her symptoms over the past year. The tinnitus and bruit have persisted at essentially the same level.

Case 5. This 35-year-old obese, Negro female underwent a left partial nephrectomy in November 1970 following which she noted blurring of vision, and left-sided constant tinnitus. The tinnitus increased and decreased in pitch and intensity during the day, unrelated to any activity. Generally, when the patient was emotionally upset, the noise increased in intensity. She also had had left frontal headaches intermittently, lasting for up to twelve hours.

An evaluation at another medical center showed bilateral papillaedema which was thought secondary to pseudotumor cerebri. A retrograde right brachial cerebral angiogram was interpreted as normal. The patient was advised to lose weight and was treated with oral glycerol without success. She was followed as an outpatient where evaluation showed inconsistent pure tone audiogram responses. She was thought to have essentially normal hearing on the right and a mild sensorineural loss on the left of cochlear origin. Her past history was unremarkable.

Physical examination showed a Negro female in no distress. Examination of the eyes showed slight blurring of the optic discs bilaterally with normal vasculature. On examination of the ears the tympanic membranes were normal, the Weber was midline, and the Rinne was positive bilaterally. Examination of the head and neck by auscultation revealed a continuous bruit of variable pitch and intensity heard best over the left mastoid tip. The bruit disappeared with light compression over the left upper sternocleidomastoid muscle. Rotating the head to the right side would increase the intensity of the bruit, while turning to the left would decrease the tinnitus. When compression over the left sternocleidomastoid caused objective loss of the bruit, subjectively the patient could still hear the tinnitus, although it had markedly decreased in intensity. From day to day the pitch and intensity varied, and on one occasion, the bruit could not be heard except when the patient was taken to a quiet room. The remainder of the physical examination was normal.

The pure tone audiogram showed symmetrical, mild neurosensory hearing loss. Impedance audiometry was within normal limits. The aural reflex was present bilaterally to broad band noise at 69 and 73 dB sound pressure levels. On arteriography there was no opacification of the right jugular vein. The contrast material was noted to drain from the paracervical venous plexus. A prominent right inferior petrossal sinus was noted. There was no opacification of the right sigmoid sinus. Mastoid tomograms were within normal limits; jugular foramina tomograms showed the left foramina to be larger than the right, but otherwise, unremarkable. An electrocardiogram (EKG) showed possible left ventricular hypertrophy. The left internal carotid PO_2 was 70.5. The left jugular vein PO_2 was 34.4.

Following the above procedure, a Fogerty catheter was introduced into the internal jugular vein to the level of the sigmoid sinus; the balloon was inflated and caused the patient's tinnitus to disappear at the level of the first cervical vertebrae. It is therefore considered that this patient will be a surgical candidate whenever she elects to have surgery.

DISCUSSION

Tinnitus is a bothersome and disturbing symptom for the patient and a perplexing problem for the physician. Patients have been known to become so upset by this symptom that they have committed suicide. Appropriate evaluation of patients with objective tinnitus is imperative since many of the lesions responsible for the symptoms are amenable to surgical correction. The diagnosis and surgical correction of many intra- and extracranial arteriovenous malformations is now possible with risks that are less than the potential complications of the untreated lesion (high output failure, hemorrhage, *etc.*). Careful historical data, physical examination with auscultation and x-rays are important; however, the definitive diagnosis rests upon good selective arteriograms and retrograde venograms.

When the communicating vessels between the arterial system and the venous system are capillaries, there is evidence to suggest that there is some hormone dependence or response. The successful use of steroids to treat hemangiomas in other areas and the decrease in the size of the mass following termination of pregnancy (Case No. 4) supports this concept.

The delineation of venous hum as a nosological entity, formerly called cephalic murmur or essential objective tinnitus, is important for it is an easily treatable lesion. The symptoms and signs are classical with increase in the tinnitus on turning the head to the op-

posite side and decrease of the tinnitus on turning the head to the same side or on performing a valsalva maneuver. Light pressure over the jugular eradicates the auscultable bruit.

The use of a Fogerty catheter with a balloon during performance of the retrograde venogram and the obstruction of the internal jugular at different levels appears to be a worthwhile diagnostic test. Since the tinnitus or bruit is believed to be caused by eddy currents, this test may indicate the optimal level for ligation of the jugular. Thus far, we have treated these patients with simple ligation of the jugular vein which can be performed under local anesthesia. They have all been informed that if this is unsucessful or if the symptoms return, a clipping of the lateral sinuses through a mastoid approach may be worthwhile.

In only one patient was the balloon test suggestive that obstruction in the sigmoid or lateral sinus would be more effective, and this patient refused surgery. In the patient shown in Figure 2, however, the tinnitus stopped only with occlusion at the body of C_2 and below. While the tinnitus has been reported to subside spontaneously, it has not done so in her case or in several others who been followed up to two years.

The immediate and dramatic improvement experienced in patients following ligation of the internal jugular vein commends its use in patients with venous hum.

Request for reprints should be sent to Paul H. Ward, M.D., Professor of Surgery, University of Calif. School of Medicine, The Center for the Health Sciences, Los Angeles, California 90024.

REFERENCES

1. Arenberg IK, McCreary HS: Objective tinnitus aurium and dural arteriovenous malformations of the posterior fossa. Ann Otol Rhinol Laryngol 80:111-120, 1972

2. Eagle WW: Elongated styloid process. Archives Otol 67:172-176, 1958

3. Cordier G, Garnier H, Durupt L, *el al*: Les allongements anormaux de l'apophyse styloide temprale avec retentissement carotidien. La Presse Medicinale 21 Jun 70 n° 30 p 1547

4. Herrmann C, Crandall PH, Fang HC: Palatal myoclonus – A new approach to the understanding of its production. Neurology 7: 37-51, 1957

5. Bjork H: Objective tinnitus due to clonus of the soft palate. Acta Otolaryngol [Suppl] (Stockh) 116:39-45, 1954

6. Pulec JL, Simonton KM: Palatal myoclonus – A report of two cases. Laryngoscope 71:668-671, 1961

7. Heller MF: Vitratory tinnitus and palatal myoclonus. Acta Otolaryngol (Stockh) 55: 292-298, 1962

8. MacKinnon DM: Objective tinnitus due to palatal myoclonus. J Laryngol Otol 82: 369-374, 1968

9. Quarry JG: Unilateral objective tinnitus a case and a cure. Arch Otolaryngol 96:252-253, 1972

10. Hamburger PL: Head murmurs. Am J Med Sci 181:756-762, 1931

11. Inglauer S: Objective tinnitus aurium. Four cases. Arch Otolaryngol 18:145-151, 1933

12. Bredlau EA: Objective tinnitus aurium. Arch Otolaryngol 28:193-198, 1938

13. Engstrom H, Graf W: On objective tinnitus and its recording. Acta Otolaryngol [Suppl] (Stockh) 95:127-184, 1950

14. Hentzer E: Objective tinnitus of the vascular type. Acta Otolaryngol (Stockh) 66: 273-281, 1968

15. Hardison JE: Cervical venous hum: A clue to the diagnosis of intercranial arteriovenous malformations. New Engl J Med 278: 587-590, 1968

16. Cutforth R, Wiseman J, Sutherland RD: The genesis of the cervical venous hum. Am Heart J 80:488-492, 1970

17. Graf T, Moller T, Mannheimer E: The continuous murmur. Acta Med Scan [Suppl] 196:167-191, 1962

18. Cary FH: Symptomatic venous hum. New Engl J Med 264:869-870, 1961

EUSTACHIAN TUBE LYMPHATICS

JACK L. PULEC, M.D.
LOS ANGELES, CALIFORNIA

TOMOKAZU KAMIO, M.D.
TOKYO, JAPAN

MALCOLM D. GRAHAM, M.D.
LOS ANGELES, CALIFORNIA

SUMMARY — Serous otitis media is the most common cause of hearing impairment. The role of lymphatic obstruction in the pathogenesis of serous otitis media is significant. A method for removal of the human Eustachian tube specimen and two techniques for identification of Eustachian tube lymphatic capillaries are described. One involves the antemortem intratympanic installation of Berlin blue. The other utilizes electron microscopy. Lymphatic capillaries cannot be reliably differentiated from blood capillaries with the light microscope. With electron microscopy, lymphatic capillaries can be differentiated from blood capillaries by differences in the basement membrane. The lymphatic capillary has gaps in the basement membrane with large nuclei in the wall. A blood capillary has a continuous basement membrane and sometimes red blood cells can be identified in the lumen. Using these methods, Eustachian tube lymphatic capillaries in the human are described for the first time in this report.

Serous otitis media is the most common cause of hearing impairment, especially in children.[1,2] Despite the prominent role played by the lymphatics of the Eustachian tube in the pathogenesis of serous otitis media, they have not previously been demonstrated in the human. The gross and light microscopic anatomy of the human Eustachian tube has been well described.[3-10] Arnould[11] and Rouviére[12] described the lymphatics of the Eustachian tube which were presumed but not proved to be present. Robison[13-14] described how malignant tumors and infections of the nasopharynx, tonsil, and paranasal sinuses might cause middle ear effusion. He explained that their lymphatic drainage pathways converged on the lateral retropharyngeal nodes and that inflammation would cause blockage at this level, causing the lymphatics around the Eustachian tube isthmus to swell. Porta[15] and Ferriari and Zini[16] demonstrated the nasopharyngeal lymphatics around the Eustachian tube orifice in animals and man by utilizing injections of neoprene and latex. Lymphatic vessels in the middle ear and Eustachian tube of the guinea pig have recently been described by Haye[17] and Lim[9] using electron microscopy. The purpose of this paper is to describe two methods for the study of Eustachian tube lymphatic capillaries and to report for the first time their identification in the human.

METHODS AND MATERIALS

Temporal Bone Study. In order to study normal histology and the anatomic relationship of the Eustachian tube to surrounding structures and to establish a technique for the expedient removal of the Eustachian tube specimen along with the middle ear and a portion of the nasopharynx surrounding the tube orifice, 107 specimens were removed from fresh cadavers during necropsy.* With the skull cap and brain removed, incisions were

* The bones were removed and studied in the laboratories of the Los Angeles County Coroner, Dr. Thomas Noguchi.

From the Otologic Medical Group, Inc. and the Ear Research Institute, Los Angeles, California.

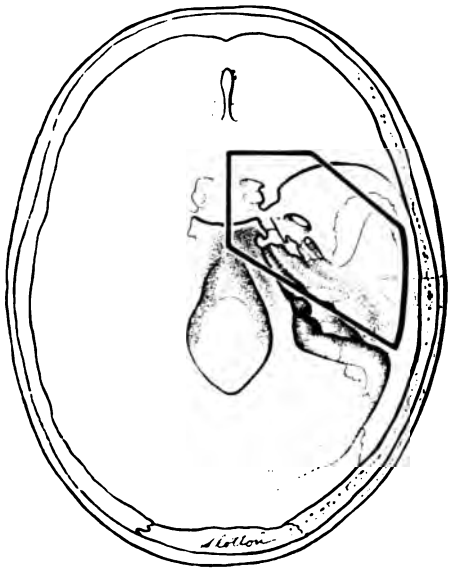

Fig. 1. Bone incisions for removal of Eustachian tube specimen with the temporal bone at necropsy.

developed (Fig. 1) which would provide a satisfactory specimen. We found it important that the anterior bony incision be at least 5 cm anterior to the anterior edge of the external auditory canal (EAC), which places it just anterior to the middle fossa. This cut, with a bone saw, is through the frontal fossa and through the posterior part of the orbit. A midline cut is made and extended back to the foramen magnum. A posterior cut through the posterior fossa in most cases extended through the skull, so that when the zygoma

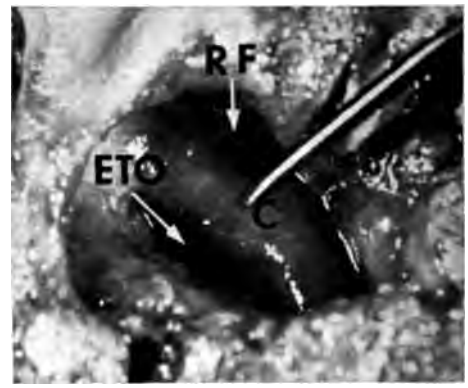

Fig. 3. Eustachian tube orifice (ETO) viewed from the nasopharynx. Rosenmueller's fossa (RF). Cartilage (C).

was transected the specimen included the entire mastoid. Ages at the time of death ranged from 7 weeks to 69 years. All bones were grossly normal and there was no history of otologic disease.

A variety of staining techniques were tried on the cadaver specimens without success, including the application of .5% hydrogen peroxide solution to the middle ear mucosa, the application of Berlin blue and India ink. Injection of the carotid arteries with Berlin blue was unsuccessful. Twenty-seven bones were dissected with the operating microscope in a search for the lymphatics as well as a study of anatomic relationships (Figs. 2A, B and 3). A method for removal of the mucous membrane from the entire length of the Eustachian tube was perfected in order to obtain specimens for light and electron transmission and scanning microscopy.

Fig. 2A and B. Gross specimen with Eustachian tube (ET) opened from above oriented to show the nasopharyngeal orifice (NPO) and malleus (M).

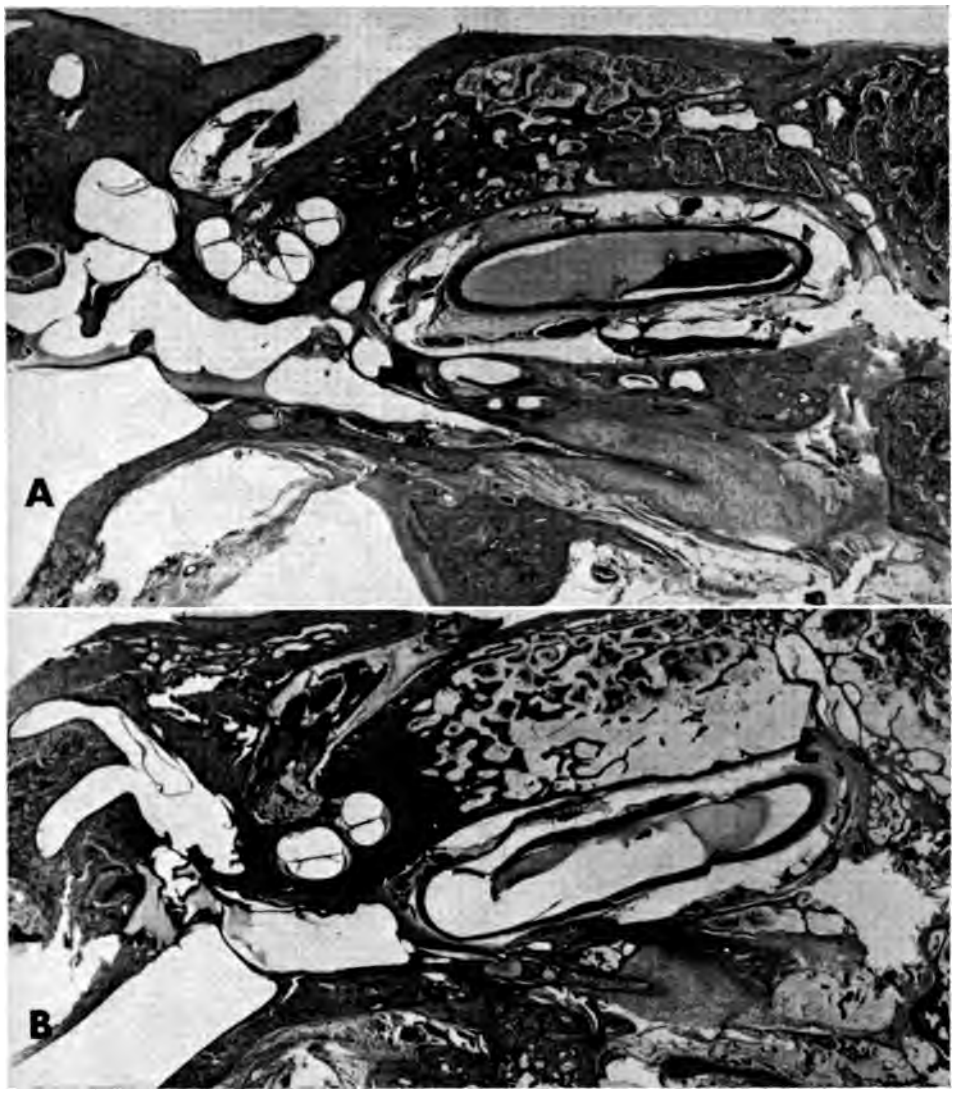

Fig. 4. Temporal bone specimen sectioned horizontally and longitudinally through (A) the protympanum and (B) the bony portion of the Eustachian tube. (H. and E. stain)

Three bones were placed in 10% formalin, decalcified, sectioned, and stained with H. and E. Sections were made horizontally and longitudinally through two Eustachian tube specimens (Figs. 4A, B, C. and D), and transverse to the long axis of the Eustachian tube in a third specimen (Figs. 5A and B).

Fifty-seven bones were dissected in search of the lymphatics using various dyes and stains. Twenty bones were placed in 2% buffered gluteraldehyde for future electron microscopic study.

Staining of Lymphatics and Electron Microscopic Study. A 60-year-old woman had been on a respirator for one full month after the removal of a large left acoustic neuroma. She had been completely unresponsive, had bilaterally dilated fixed pupils, and blood pressure which could not be kept at a normal level since the day of surgery. Her pulse became progressively weaker. Electroencephalogram (EEG) showed no activity. The family of the patient requested that no further unusual steps to prolong life be taken. Since

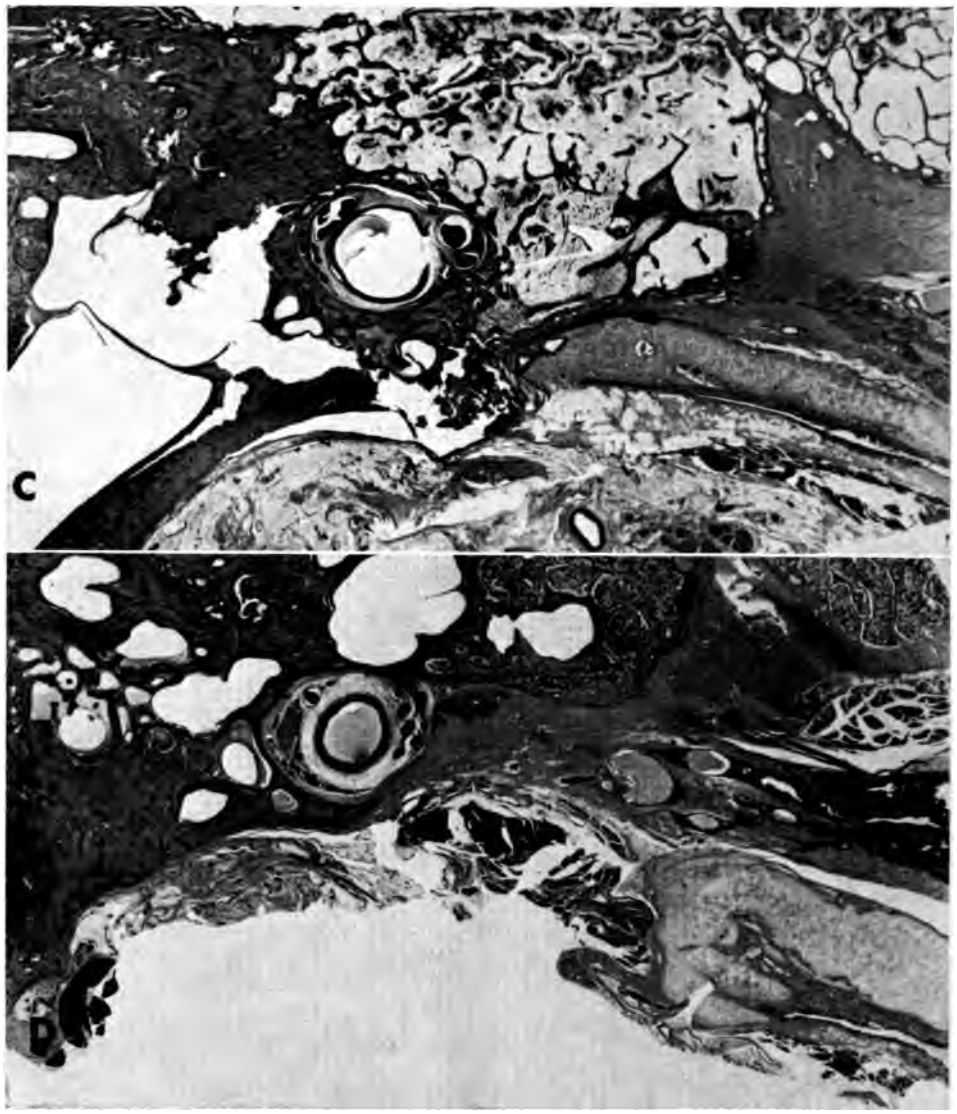

Fig. 4. Temporal bone specimen sectioned horizontally and longitudinally through (C) the fibrocartilaginous portion of the Eustachian tube and (D) the nasopharyngeal opening of the Eustachian tube. (H. and E. stain)

permission was granted for necropsy and examination of the ears, 2 ml of 2% Berlin blue in water was injected through the right tympanic membrane eight hours before death. The Eustachian tube specimen was removed at postmortem examination three hours after death, eleven hours after injection. Ten minutes' time was taken to remove the specimen from the cadaver and within another ten minutes the mucous membrane was dissected from the specimen. The membrane specimen was transected longitudinally. One half was placed in 10% formalin for the preparation of H. and E. stained slides and the other half was immediately placed in 2% buffered gluteraldehyde. It was then transferred to a 1% phosphate buffered osmium tetroxide solution for one hour, dehydrated in graded alcohol, and embedded in Epon.®* Thick and thin sections were prepared with an ultratome** using

* Shell Chemical Co., N. Y., N. Y.
** LKB Instruments, Inc., Rockville, Md.

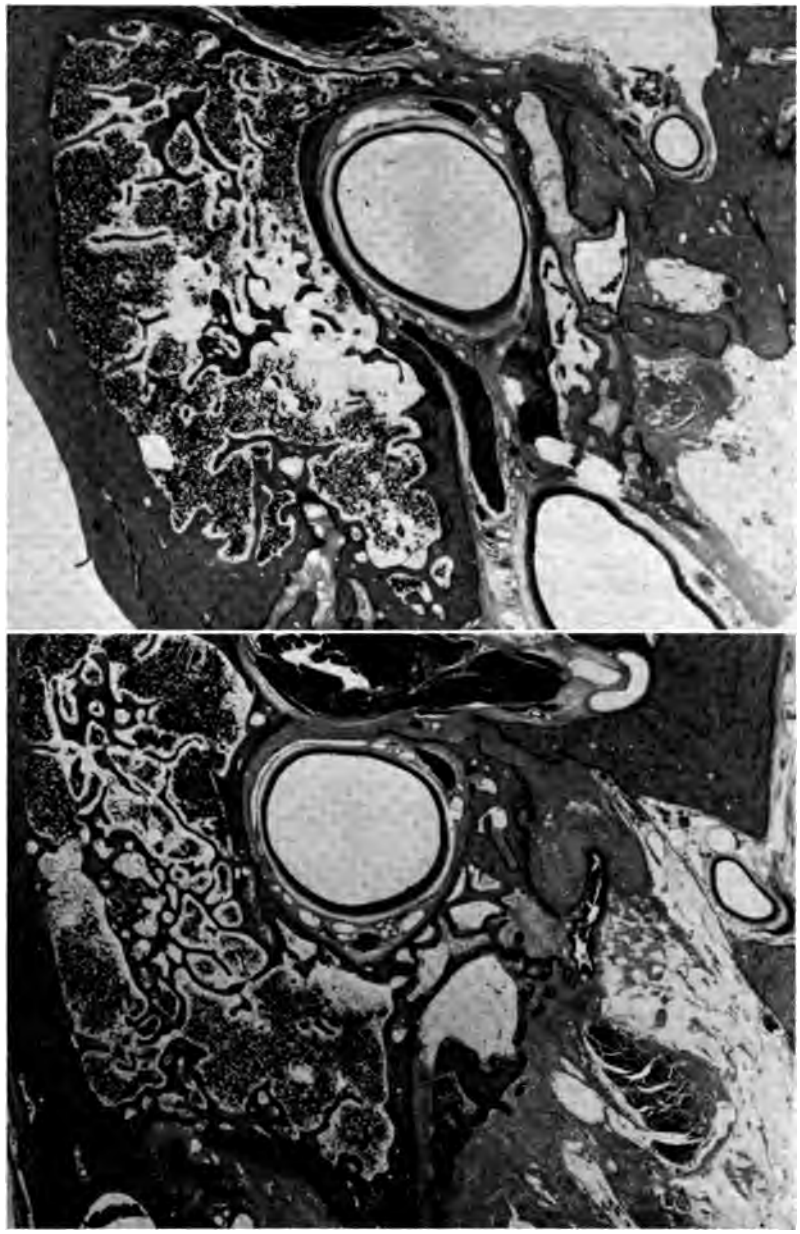

Fig. 5. Temporal bone specimen sectioned transversely through (A) the tubotympanum and carotid artery and (B) the nasopharyngeal orifice of the Eustachian tube and carotid artery. (H. and E. stain)

glass knives, transferred to carbon-coated Formvar membranes, stained with alcohol uranyl acetate and lead citrate, and studied under the transmission electron microscope.

RESULTS

Examination by light microscopy of the mucous membrane of the patient, injected with Berlin blue eight hours before death, revealed only one channel in the submucosa which was stained with the dye (Fig. 6). The specimen is from the nasopharyngeal end of the

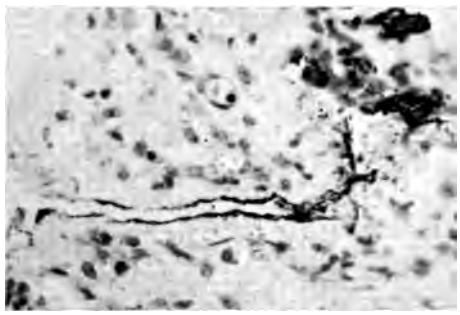

Fig. 6. Lymphatic channel in the submucosa of the nasopharyngeal end of the Eustachian tube stained by antemortem tympanic injection of Berlin blue.

tube and presumably shows a lymphatic vessel.

Specimens studied under the transmission electron microscope revealed the presence of blood capillaries (Fig. 7), as well as lymphatic capillaries (Figs. 8 and 9 A and B). Blood and lymphatic capillaries can be clearly differentiated, not only when red blood cells are seen in the blood capillary but specifically by differences in the basement membrane. Lymphatic capillaries are lined by large, flattened endothelial cells which sometimes have simple end-to-end junctions or overlap, or may have a series of interdigitations with various types of attachment devices between which intercellular gaps may occur. The endothelial cell lining is occasionally interrupted. By contrast, the basement membrane of the blood capillary is continuous and can be traced around the circumference without a gap.

DISCUSSION

Our interest in the lymphatics of the Eustachian tube was stimulated by the serendipitous observation that serous otitis media was regularly the result when Teflon®* paste was injected posterior to the Eustachian tube cartilage in dogs.[18] While doing an experiment to perfect the treatment for abnormally patent Eustachian tubes, it was found that injection of Teflon® paste anterior to the nasopharyngeal orifice in dogs would increase closure of the tube and greatly increase the resistance to the passage of air, but did not result in serous otitis media. Injection of 0.5 ml or more of paste immediately posterior to the nasopharyngeal Eustachian tube cartilage in dogs routinely produced

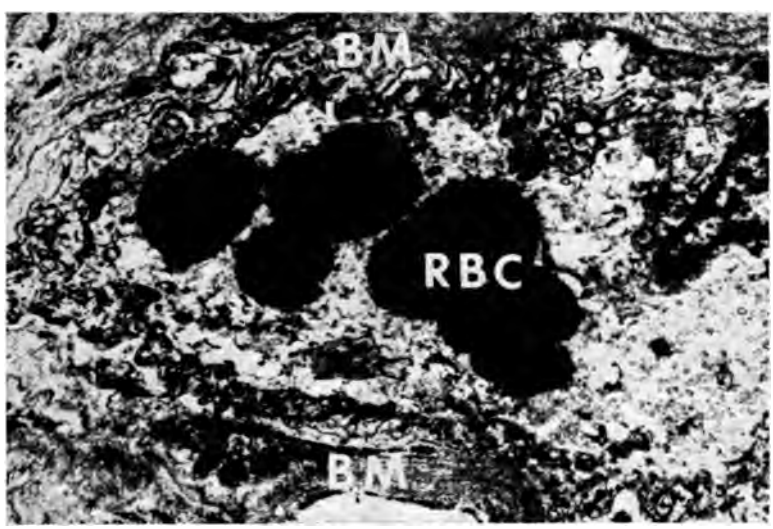

Fig. 7. Electron photomicrograph showing a blood capillary in the human Eustachian tube. The basement membrane (BM) is continuous without interruption. Red blood cells (RBC) are within the lumen. (X6600)

*E. I. DuPont de Nemours and Co., Wilmington, Del.

Fig. 8. Electron photomicrograph showing a lymphatic capillary in the human Eustachian tube. Note the large nuclei and gaps in the basement membrane (BM). (X6600)

serous otitis media without increasing the patency or resistance of the Eustachian tube. This observation was further defined and confirmed in a subsequent study.[19] This finding supported the view of Robison[13-14] that one pathogenesis of serous otitis media is lymphatic obstruction in the nasopharynx, specifically involving the lymphatics inferior and posterior to the nasopharyngeal Eustachian tube orifice. The common association, clinically, of serous otitis media with maxillary sinusitis, nasopharyngeal carcinoma, or after heavy radiation to that area would seem to support this thesis.

It would seem likely that serous otitis media associated with infected or inflamed tonsils or adenoid tissue would be the result of a similar mechanism of lymphatic obstruction, rather than the mechanism often casually explained that these tissues physically obstruct the tube orifice.

The possibility that serous otitis media can occur without tubal obstruction and without the production of any vacuum is proved by the observation of the occasional patient who has both serous otitis media and an abnormally patent Eustachian tube on the same side. When the otologist sees a definite fluid level with a conductive hearing loss and at the same time observes the tympanic membrane to move freely in and out with respiration, he usually finds that the patient complains primarily of autophony and fullness in the ear, characteristic of an abnormally patent Eustachian tube. The serous fluid disappears without treatment but the autophony and pressure usually remain.[20]

Obstruction of Eustachian tubal lymphatics may be instrumental as a mechanism of production of serous otitis media from several etiologies, such as inflammation from infected tonsils and adenoids or sinusitis, and from nasopharyngeal tumor, radiation, or allergy.[21] It would seem that knowledge of the normal anatomy of Eustachian tube lymphatics, as well as physiology and the nature of pathologic changes, should be known before routine understanding and effective therapy could be available for serous otitis media.

Despite descriptions in the literature[3,12] based on artists' conceptions of these structures, a good description of

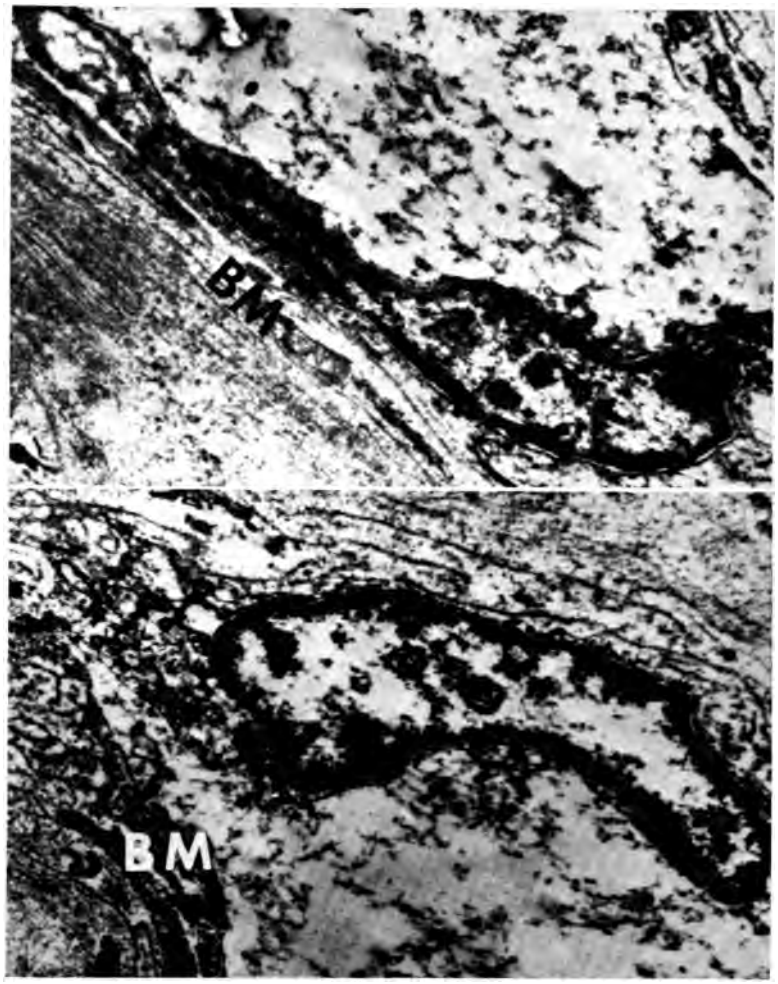

Fig. 9A and B. Electron photomicrograph enlarged view of nucleus within the wall of Eustachian tube lymphatic capillary shown in Figure 8. (X13,800)

the lymphatic drainage of the middle ear mucosa is not yet available. The apparent reason for the lack of this knowledge is quickly evident to one who attempts to study the lymphatics of the Eustachian tube. Most temporal bone specimens are either cores or portions of the bone with part of the Eustachian tube cut away. The deep-seated position within the skull, as well as the need to open widely into the nasopharynx and great vessels, require special techniques. Most human temporal bones cannot have antemortem injection as is possible with experimental animals. If one is to study the lymphatics of the Eustachian tube by injection techniques, timing of the injection as well as having minimal delay before fixation after death is important. In the living, lymphatics clear dye very quickly so that if sometimes death occurs even several minutes after a dye has been instilled, it may already be carried away into the lymphatic system and no longer be visible. If the patient swallows often before death, dye placed in the tympanum will be lost through the Eustachian tube. Large particles such as carbon in India ink do not seem to be absorbed by the middle ear mucous membrane, and it is not possible to

place a needle under the membrane to inject this material. The problem of reducing the time lag between injection, death, and acquisition was significantly improved by the development of a cooperative research effort with the County Coroner and in one case by paying careful attention to the timing of these procedures in a patient who was expected to succumb in the hospital. Since opportunities of this sort cannot be planned, the investigator must be thoroughly prepared and able to quickly remove and process the specimen. Care must be taken with the type of dye used. It cannot be toxic if injected in the living, and if it produces discoloration of the skin, it cannot be injected intra-arterially unless the cadaver is to be cremated.

Lymphatic capillaries cannot be reliably differentiated from blood capillaries with a light microscope.[22] The difficulties associated with staining methods are avoided with the electron microscope. Data exists concerning the ultrastructural differentiation of blood and lymphatic capillaries in other organs of the body.[22-24] Haye[17] and Lim[9] demonstrated lymphatic capillaries in the middle ears and Eustachian tubes of guinea pigs using horseradish-peroxidase and transmission electron microscopy. It remained for us in this study to obtain and fix material which would be reasonably free of artifact. We were successful in one case. We feel that these techniques will be useful to study by serial section the course and distribution of lymphatics within the Eustachian tube. Tissue from the same specimen will be studied by the scanning electron microscope in the future.

Request for reprints should be sent to Jack L. Pulec, M.D., Otologic Medical Group, Inc., 2122 West Third St., Los Angeles, California 90057.

ACKNOWLEDGMENTS—The authors are greatly indebted to Dr. Thomas Noguchi, Chief Medical Examiner-Coroner, County of Los Angeles, for his invaluable assistance in the acquisition of anatomic material and for the use of his laboratory; and to Messrs Lawrence E. Irwin and Robert O. Greer for their technical assistance in the Otologic Electron Microscopic Laboratories of the Ear Research Institute; and to Dr. F. H. Linthicum, Jr. for his assistance in the Eccles' Temporal Bone Laboratory of the Ear Research Institute.

REFERENCES

1. Hoople GD: Otitis media with effusion: A challenge to otolaryngology. Trans Am Acad Ophthalmol Otolaryngol 54:531-539, 1950

2. Harrison K, Watson TK: Long-term follow-up of chronic exudate otitis media (glue ears). Proc R Soc Med 62:456-460, 1969

3. Worms G. Colouma VV: Considerations sur la trompe fibro-cartilagineuse et la region pharyngo-tubaire. Societe d'Anthropoligie de Paris. V8, S.8, 1936

4. Kelemen G: The pharyngeal orifice of the Eustachian tube in the aged. Eye Ear Nose Throat Mon 34:809-812, 1955

5. Graves GO, Edwards LF: Eustachian tube. Arch Otolaryngol 39:359-397, 1944

6. Proctor B: Embryology and anatomy of the Eustachian tube. Arch Otolaryngol 86:51-62, 1967

7. Proctor B: Anatomy of the Eustachian tube. Arch Otolaryngol 97:2-8, 1973

8. Schuknecht HF, Kerr AG: Pathology of the Eustachian tube. Arch Otolaryngol 86: 45-50, 1967

9. Lim DJ: Functional morphology of the lining membrane of the middle ear and Eustachian tube: An overview. Ann Otol Rhinol Laryngol (Suppl 11) 83:5-26, 1974

10. Tos M: Development of mucous glands in the human Eustachian tube. Acta Otolaryngol (Stockh) 70:340-350, 1970

11. Arnould N: Contribution a l'etude des lymphatiques de l'appareil auditif. Arch Int Laryngol Otologie-Rhinologie 6:696-720, 1927

12. Rouviére H: *Anatomy of the Human Lymphatic System.* MJ Tobias (trans). Ann Arbor, Mich., Edwards Bros Inc. 1938

13. Robison JM: Subacute catarrhal otitis media and mastoiditis with effusion: A symptom and a clinical entity. Southern Med J 35: 815-824, 1942

14. Robison JM: Lymphangitis of the mucosa of the paranasal sinuses. Tex Med 40: 193-198, 1944

15. Porta CF: Personal communication

16. Ferrari C, Zini C: La vascolarizzazione linfatica del tessuto linfoide bucco-faringeo

(Dell'anello di Waldeyer). *Collana di Monografie de "L'ateneo Parmense."* Parma, No. 4, 1959

17. Haye R: The lymphatic capillaries of the middle ear mucosa in the guinea pig: Ultrastructure and permeability. Z Zellforsch Mikrosk Anat 145:785-189, 1973

18. Brookler KH, Pulec JL: Auditory tube patency after injection of the Teflon paste: An investigation in dogs. Arch Otolaryngol 90:60-64, 1969

19. Reiner CE, Pulec JL: Experimental production of serous otitis media. Ann Otol Rhinol Laryngol 78:880-887, 1969

20. Pulec JL, Hahn Jr FW: The abnormally patulous Eustachian tube. Otolaryngol Clin North Am 3:131-140, 1970

21. Pulec JL, Horwitz MJ: *Diseases of the Eustachian Tube. Otolaryngology.* Philadelphia, W. B. Saunders Co, 1973, vol 2, pp 75-92

22. Lauweryns JM: The blood and lymphatic microcirculation of the lung. Pathol Annu 6:365-415, 1971

23. Leak LV, Burke JF: Fine structure of the lymphatic capillary and the adjoining connective tissue area. Am J Anat 118:785, 1966

24. Lauweryns JM, Boussauw L: The ultrastructure of pulmonary lymphatic capillaries of newborn rabbits and of human infants. Lymphology 2:108, 1969

INTRODUCTION OF THE AWARD OF MERIT RECIPIENT

JOHN E. BORDLEY, M.D.

PRESENTED AT THE AMERICAN OTOLOGICAL SOCIETY DINNER, APRIL 11, 1975

It should be remembered tonight that the Award of Merit is the highest honor that the American Otological Society can confer. It is, in fact, one of the most important awards in our specialty in the world today. It is not given each year, but only when an outstanding candidate is found. It is not for research alone, but for the total contributions made to Otology. The award was established in 1948, by coincidence the very year that our awardee entered Otolaryngology.

Your Committee for the Award of Merit has felt an awesome responsibility. Our charge was to review the contributions of the many distinguished individuals in our field, and to decide if one was worthy of this great honor. In order to prepare for this decision, the Committee decided to do a computer analysis on the 20 previous awardees. From this analysis a profile was developed in order to give us guidelines for our pursuit of excellence.

We thought you would be interested in some of the data turned out in the computer printout designed to help our search. One of the most important finds is that, contrary to popular belief, not all of the awardees exhibited baldness. To prove this point I had intended to ask him to stand tonight, so that you all could see his splendid equipment, but I am sorry to report that the Chairman of the Ethics Committee got wind of this and sent word that his committee would consider any such exhibition by a member of the Society unethical and unfair to the other members, and worse, such an exhibition *might* alter the public image of our Society. Other pertinent information from our analysis concerns vital statistics. Interestingly, we found they were nearly identical for all of the previous awardees. The computer averages for these measurements are as follows: chest, 21 inches; middle, 52 inches; lower, 63 inches. We felt that these were very significant figures.

Our final selection of an awardee was considerably easier than we had anticipated. Actually the profile, as I will explain later, did not help us as much as we expected. The ease with which our choice was made, was because we quickly recognized a candidate of such outstanding qualifications and with such a record of contributions to Otology, that the Committee unanimously agreed that the individual completely qualified for the award.

Let us review our findings. Born, raised and educated in St. Louis, awarded a Master of Science degree and a Doctor of Philosophy degree by Washington University.

But, Mr. President, perhaps it is time for a sneak preview of our candidate. This picture was taken at the age of three, unfortunately it was that time in our country when mothers used to embarrass little boys by trying to dress them up like little girls. Many of our older members have undoubtedly destroyed a number of such pictures. Some of them seem to survive to haunt us.

Cute little fellow!

Our awardee entered Otolaryngology in 1948 as research assistant working on a problem in immunology; however, this interest soon changed to research on the anatomy, physiology, and neurology of the inner ear. This was further stimulated by a two year visit to the Karolinska Institute in Sweden as an NIH special trainee. Many of the papers reporting this research are now considered classics. The academic career kept pace with the research career and in 1962 our candidate was made a Research Professor in Otolaryngology at Washington University and an Associate at the Central Institute for the Deaf.

Our awardee has interests outside of the professional field. Such interests include wild flowers and have resulted in two trips to Egypt to study the civilization of the Pharaohs and a stay in the Galapagos Islands because of a long interest in bird watching.

Let us get back to our pictures. This one was taken at the time of graduation from grammar school at age 12 years. Mr. President, it's A GIRL! Our very first girl. Isn't it exciting – a girl.

Our next picture shows our awardee when she received her Ph.D. Mr. President, I said before that our profile was not much help but I am intrigued at what the computer's reaction will be when we attempt to put this year's vital statistics into our data bank.

To be serious, however, your Committee is anxious for the Society to understand that our choice was not made on the awardee's superb research alone. This was not her only contribution to Otology. During her career she has inspired countless young doctors to explore the delights of research. She has been a gentle and wise counselor, listening patiently and speaking softly with words of great wisdom to many of us facing perplexing questions in Otology. It is only proper then that we in Otology should express our deep appreciation to her for all these wonderful gifts by awarding her our highest honor.

Now Mr. President, here is our awardee, Catherine Smith, M.S., Ph.D., Professor of Otolaryngology at the University of Oregon School of Medicine, truly a great lady. May I have the honor to present her to you?

RESPONSE OF THE AWARD OF MERIT RECIPIENT

CATHERINE A. SMITH, Ph.D.

I really do not know what to say except that I am greatly honored by the award, and thank you very much. When I look out at the audience and see so many who have done as much and more than I for the profession, I feel very humble, and even more honored that the committee chose me.

AWARD OF MERIT RECIPIENTS

1949 George M. Coates, M.D.

1951 Barry J. Anson, Ph.D., and
Theodore H. Bast, Ph.D.

1952 Edmund P. Fowler, M.D.

1953 Julius Lempert, M.D.

1954 Stacy R. Guild, M.D.

1957 Georg von Békèsy, Ph.D.

1959 Ernest Glen Wever, Ph.D.

1960 Hallowell Davis, M.D.

1961 John R. Lindsay, M.D.

1962 William J. McNally, M.D.

1965 Anderson C. Hilding, M.D.

1966 Gordon D. Hoople, M.D.

1967 Merle Lawrence, Ph.D.

1968 Lawrence R. Boies, M.D.

1969 Sir Terence Cawthorne

1970 Senator Joseph Sullivan, M.B.

1971 Samuel Rosen, M.D.

1972 Howard P. House, M.D.

1973 Moses H. Lurie, M.D.

1974 George E. Shambaugh, Jr., M.D.

1975 Catherine A. Smith, Ph.D.

GUESTS OF HONOR

1949 Harris P. Mosher, M.D.

1950 D. Harold Walker, M.D.

1951 John Mackenzie Brown, M.D.

1952 Edmund P. Fowler, M.D.

1953 H. I. Lillie, M.D.

1956 Stacy R. Guild, Ph.D.

1958 Ralph A. Fenton, M.D.

1961 Julius Lempert, M.D.

1962 Philip Meltzer, M.D.

1963 William J. McNally, M.D.

1964 Kenneth M. Day, M.D.

1965 Senator Joseph A. Sullivan, M.B.

1966 Dean M. Lierle, M.D.

1967 Lawrence R. Boies, M.D.

1968 Sir Terence Cawthorne

1969 Gordon D. Hoople, M.D.

1970 John R. Lindsay, M.D.

1971 E. Glen Wever, Ph.D.

1972 Frank D. Lathrop, M.D.

1973 Moses H. Lurie, M.D.

1974 Harry Rosenwasser, M.D.

1975 John E. Bordley, M.D.

BUSINESS MEETING

APRIL 11, 1975

The Business Meeting of the One Hundred Eighth Annual Meeting of the American Otological Society, Inc. convened at eight-thirty-five o'clock in the Phoenix Ballroom of The Hyatt Regency Atlanta, Dr. Lester A. Brown, President of the Society, presiding.

PRESIDENT BROWN: I would like to declare the One Hundred and Eighth Annual Meeting of the American Otological Society is now in session. This meeting is for members only and if there are any guests I would like to ask that they wait outside until nine o'clock.

Our first order of business this morning is the election of new members and I shall call on our Secretary, Dr. Taylor, at this time.

SECRETARY-TREASURER G. DEKLE TAYLOR: Mr. President, guided by the vote of the membership, the Council recommends the following be elected to active fellowship in the Society:

Dr. Francis I. Catlin, sponsored by Dr. Bobby Alford; seconded by Dr. John Bordley.

Dr. Vijay S. Dayal, proposed by Dr. William J. McNally, seconded by Dr. Kenneth McAskile.

Dr. Richard E. Marcus, proposed by Dr. John Bordley, seconded by Dr. Victor Alfaro.

Dr. William W. Montgomery, proposed by Dr. Harold Schuknecht, seconded by Dr. Moses Lurie.

Dr. W. Hugh Powers, proposed by Dr. Harold Boyd, seconded by Dr. Howard House.

Dr. Roger E. Wehrs, proposed by Dr. Gunner Proud, seconded by Dr. Jack Hough.

Dr. Isamu Sando be elected to associate membership in the Society, proposed by Dr. William Hemenway, seconded by Dr. Harold Schuknecht.

Mr. President, I move that the above-named individuals be elected to membership in the Society in the appropriate category.

DR. SHIRLEY BARON: Second.

PRESIDENT BROWN: It is seconded by Dr. Shirley Baron. Is there any discussion? (No response.) Are you ready for the question? All in favor say "aye"; opposed "no." The motion is carried.

I am going to ask Dr. Taylor if he would have the newly elected members come into the meeting room now and join us and I will ask the new members' sponsors if they will meet the new members and bring them to the front of the room and ask them to line up in front of the platform facing toward the Society members. (Whereupon Secretary Taylor then escorted the newly elected members into the room for introduction.)

I will ask each one of the sponsors if he would introduce his new member, starting with Dr. McNally.

DR. WILLIAM J. MCNALLY: Mr. President, may I introduce my new member, Dr. Vijay Dayal of Toronto.

DR. HAROLD BOYD: Mr. President, may I introduce our new member, Dr. Hugh Powers from Los Angeles.

DR. GUNNER PROUD: Mr. President, I am pleased to introduce our new member, Dr. Roger E. Wehrs of Tulsa.

DR. BOBBY ALFORD: Mr. President, I have great pleasure in introducing our new member, Dr. Francis Catlin.

DR. JOHN BORDLEY: Mr. President, I have great pleasure in introducing our new member, Dr. Richard Marcus from Chicago.

DR. HAROLD SCHUKNECHT: Mr. President, I am pleased to present Dr. William Montgomery of Boston as an active member and Dr. Isamu Sando, currently of Denver, Colorado, as associate member.

PRESIDENT BROWN: Thank you. I wish to welcome each of you as new members in this Society, personally and on behalf of all the members whom you are about to join. I am sure at this moment you have some of the feelings that all of us had when we stood in a similar situation. I think it is a very high point in a man's professional career to be accepted by his peers in this capacity and we welcome you to this, the oldest ear society in the world. It has a great heritage and we look forward to your work to continue its leadership in this area.

So, I bid you welcome and my handshake is to extend the welcome of all the rest of the members.

We have some certificates for you and I will go along the line and present these.

(Whereupon President Brown then shook the hand of each newly elected member and presented him with his certificate of membership.) (Applause)

Now, if each of you will take seats as full members and join the rest of us.

The next item on the agenda is the election of a Nominating Committee and, according to the bylaws, a Nominating Committee of five members is nominated from the floor and is elected at the first business session.

Do I hear nominations?

DR. PAUL WARD: I nominate Dr. Francis Davison.

PRESIDENT BROWN: Next, do I hear another nomination?

DR. CLAUDE CODY: Dr. Walter Work.

PRESIDENT BROWN: Another nomination?

DR. LURIE: Dr. Gunner Proud.

DR. HARRILL: I would like to nominate Dr. Shirley Baron.

DR. BARON: I thank you but I cannot serve as I am on the Council.

PRESIDENT BROWN: Dr. Harrill!

DR. HARRILL: I would like to nominate Dr. Miles Lewis.

PRESIDENT BROWN: Dr. Moore!

DR. JAMES MOORE: Dr. Harold Boyd.

PRESIDENT BROWN: How many do we have, Mr. Secretary?

SECRETARY TAYLOR: That is five.

DR. BARON: I move the nominations be closed.

DR. BORDLEY: I second.

PRESIDENT BROWN: Any discussion? (No response.) All in favor say "aye"; opposed "no." The motion is passed.

These are our major items that we have to complete at our first business

meeting. Mr. Secretary, where do you wish the Nominating Committee to meet?

SECRETARY TAYLOR: Can I make a couple of announcements?

PRESIDENT BROWN: Yes, of course.

SECRETARY TAYLOR: By way of announcements, the Nominating Committee will meet with me after the group photograph and the group photograph will take place this morning right after the scientific session.

We will try not to keep you very long. Every year, somebody wants to know if you can buy these photographs. The cost of these will be $7.00 and if you will just let me know I will have them mailed to you with the bill.

Tonight is the President's Dinner. It is 21 miles to the Atlanta Athletic Club and Country Club, a big cab fee. We are going to provide buses leaving at six-fifteen so let me recommend that you all be at the Ivy Street entrance. That is as you go down on the elevator, just press the button for motor entrance at the rear of the hotel and the buses will be there at 6:15 ready to depart.

Dr. Brown is going to have an excellent program and I would urge you all to be there.

Another thing, we would like to have the final count by ten o'clock this morning so be sure and register at the registration desk and pick up your tickets.

We have a rear view screen, this is something new!

You will not see as well over in this direction, so let me urge all of you to sit towards the middle of the room or in the "No Smoking" area over on the left hand side.

For those that are going to present a paper and have slides we have a projection room. At the registration desk, take the aisle to the rear and there is a room called the Greco Room in the Spanish Suite, it is easy to find, you can put your slides in the carousel. The projectionist is right behind that screen. Take those to him and he will have everything set up for you. I think that is all, Mr. President.

PRESIDENT BROWN: Will there be anyone in the Spanish Suite to help them with the loading of the slides?

SECRETARY TAYLOR: Just the projector and the carousel. Nobody will help you, but everything is there for you.

PRESIDENT BROWN: I want to call your attention again to the announcement that Deke just made and that it was my mistake originally in saying the buses would meet us in front. I thought they would until I had the letter from the Marta Company saying they are not allowed to come to the front of the hotel and therefore you have to meet in the back on Ivy Street which is the street in back of the hotel.

Now, two things: The buses are supposed to start rolling at six-fifteen, not loading, but rolling. They will start at six-fifteen because although most of the traffic has died down by that time, that heavy afternoon traffic, it still takes quite awhile to get out to the Atlantic Club.

Now, when we leave there tonight, remember that the buses start rolling at ten-thirty, not loading, so I will call your attention to this as the program goes on tonight. We do not have sleeping facilities at the Country Club! (Laughter.) And, there is no other way – there's just no way! Are there any other announcements? (No response.) Is there any comment that anyone wishes to make please? (No response.)

It is now about ten minutes to nine. We will convene the scientific session promptly at nine.

(The meeting adjourned at eight-fifty o'clock.)

BUSINESS MEETING

APRIL 12, 1975

The second business meeting of the One Hundred and Eighth Annual Meeting of the American Otological Society, Inc. reconvened at eight-twenty o'clock, President Lester A. Brown presiding.

PRESIDENT BROWN: The business meeting will come to order. The first item of business this morning is the approval of the minutes from the previous business meetings as published in the Transactions of the Society.

DR. WESLEY BRADLEY: Mr. President, I move that the minutes which have been circulated be approved as published.

DR. ROBIN MICHELSON: Second.

PRESIDENT BROWN: The motion is made and seconded that we accept the minutes as distributed. Any discussion? (No response.) All those in favor say "aye"; opposed "no." (The motion carried.) The next item of business will be the report of the Secretary.

SECRETARY TAYLOR: Mr. President and Members:

The membership of the Society as of March 15, 1975 was as follows:

Active	113
Senior	31
Associate	24
Honorary	5
Emeritus	6
Total	179

Request for transfer to senior membership has been received from Dr. Howard P. House who became an active member in 1947; Dr. Raymond E. Jordan who became an active member in 1953; Dr. George Shambaugh, Jr., who became an active member in 1950; Dr. Walter P. Work who became an active member in 1953, and Dr. Jerome Hilger who became an active member in 1951.

These requests are recommended by the Council and they are presented to the membership at large for approval.

PRESIDENT BROWN: Gentlemen, you have heard the report, what is your pleasure?

DR. BARON: So moved.

PRESIDENT BROWN: Second?

DR. MICHELSON: Second.

PRESIDENT BROWN: Discussion? (No response.) All in favor say "aye"; opposed "no." (The motion carried.)

SECRETARY TAYLOR: Since the last annual meeting, the Society has lost through death the following members:

Dr. Francis L. Weille, elected to active membership in 1953.

Dr. Henry L. Williams, elected to active membership in 1939.

Dr. Barry J. Anson, elected to Associate membership in 1949.

PRESIDENT BROWN: Gentlemen, would you stand for a moment. (Whereupon the entire assemblage then stood in respectful silence for a few moments.) Thank you.

SECRETARY TAYLOR: Mr. President, the Council requested that I bring to the attention of the membership two matters. One has to do with absentee attendance.

> Article II, Section 8: Any active member who shall absent himself from three consecutive annual meetings without reason satisfactory to the Council shall be dropped from membership in the Society and notified to that effect by the Secretary. Any member so dropped from membership may be reinstated only by unanimous vote of the Council on presentation of valid justification for such reinstatement. This rule, however, shall not apply to members of twenty years or more standing.

Recently, we have had difficulty with this. There are quite a few people who have not been attending and the Council has asked me to ask members if you ever absent yourself from two consecutive meetings, you must request that you be excused in writing prior to a third absence.

The other item they requested I bring to your attention has to do with the election into this Society.

> This is Section 5 of Article VI which states: Any candidate opposed by eight active members shall be eliminated from the list of applicants for membership.

This means when these ballots come back to the Secretary's office, if there are eight negative votes of the entire membership that individual is not even brought up before the Council. They have requested that I let you know how much importance that negative vote has.

PRESIDENT BROWN: Dr. Shirley Baron, do you have a report from the ad hoc Committee relative to the finances?

DR. BRADLEY: Mr. President, I think you need an acceptance of the report of the Secretary, if that is the conclusion of his report.

SECRETARY TAYLOR: Yes, it was.

DR. BRADLEY: Then, I move it be accepted.

DR. BEN SENTURIA: Second.

PRESIDENT BROWN: All in favor say "aye"; opposed "no." (The motion carried.) It is accepted then. Dr. Baron!

DR. BARON: Dr. Brown, Dr. Taylor:

Dr. Dekle Taylor as the Treasurer informed the ad hoc committee, consisting of myself, Dr. Ben Senturia, and Dr. Dekle Taylor, that we were now operating in the red largely because of the increased expenses of the Transactions. It was felt that if we were to continue to operate as we are, it would be necessary to increase the dues. We felt that there were other ways we might reduce our expenses so a dues increase would not be necessary at this time. The following recommendations were made to and accepted by the Council at its mid-winter meeting: 1) Senior, Emeritus and Associate members will have the Transactions made available to them at a price of $7.50. It will be optional as to whether or not they order these. 2) Honorary members shall continue to receive their Transactions at no cost. 3) Reduction or deletion of contributions for this year: a) delete the National Federation of Health Science Liability contribution of $200;

b) reduce contribution to American Council of Otolaryngology to $500; c) reduce the contribution to Centurion Club of the Deafness Research Foundation to $500; 4) Every member attending the banquet will be billed a prorated expense for the banquet. The Society will pay for the guests; 5) The Society will continue to pay the expenses of future speakers at the discretion of the President of the Society. We will continue to pay for the Guest of Honor. It was suggested that the letter we obtain each year from the International Federation of Otolaryngological Societies should be sent to the members. 6) Delete further contributions to the Noise and Drug Pollution Committee. If they desire further funds it must go to the Council. This was a one time grant. 7) The Treasurer shall continue to pay for meals of members transacting business for the Society.

It was felt if the Council adopts these recommendations a dues increase will not be necessary. We will continue to have the Council dinner. Thank you, Mr. President.

PRESIDENT BROWN: Thank you, Dr. Baron. Gentlemen, you have heard the report of the ad hoc committee. Is there a motion to accept this report?

DR. BORDLEY: So moved.

DR. SENTURIA: Second.

PRESIDENT BROWN: Any discussion? (No response.) Dr. Baron said there will not be an increase in the dues this year, is that correct?

DR. BARON: Yes.

PRESIDENT BROWN: All those in favor say "aye"; opposed "no." (The motion carried.) Mr. Secretary, do you have the Treasurer's report now?

SECRETARY TAYLOR: Last year I was accused of making the slides so small nobody could read them, but I hate to tell you we had an economy move this year and they're worse!

We started out the fiscal year of 7/1/74 with a figure of $219.54 and this caused quite a bit of consternation and we knew at that time that we either had to raise the dues or make some changes.

In 1973, there was a deficit financing of $999. This improved in 1974 to $785.28.

The total income from 7/1/74 to 3/15/75 was $17,129.

Our disbursements to date have been $10,504.67 so at this time in the bank we have $6,404.79.

We have our Series "E" bond which was started out at $10,000 and it's now worth $13,072. We also have our savings certificate which is now worth $6,857.59.

I will send you each a copy of this in a letter after the meeting. One thing I do want to tell you when you get your bill in June or July and you are billed for that very elaborate banquet last night, I want you to understand that it is a change. Heretofore the Society has paid for that banquet. That concludes the report. Any questions that I can answer? (No response.)

AMERICAN OTOLOGICAL SOCIETY, INC.

TREASURER'S REPORT

July 1, 1974 - March 15, 1975

Receipts:	
Annual Dues: @ $100	$11,400.00
Initiation Fees: @ $100	500.00
Income from Banquet: @ $23.50 & $12.25	1,118.00
Income from "Transactions"	4,099.00
Gift	10.00
Canadian Exchange	2.00
Total Income	$17,129.00
Disbursements:	
Expenses of Editor-Librarian:	
Printing of "Transactions"	$ 5,036.51
Printing and Stationery	44.09
Postage	90.60
Expenses of Secretary-Treasurer:	
Printing and Stationery	729.10
Postage	147.74
Telephone	77.44
Secretarial Services	375.00
Mid-Winter Council Meeting Expense	2,398.11
Annual Meeting Expense to date	406.08
Contributions:	
American Council of Otolaryngology	500.00
Centurion Club – Deafness Research Foundation	500.00
International Federation of Otorhinolaryngological Society	100.00
Fee – Annual Report of Charitable Organization	100.00
Total Expenses	$10,504.67

Cash in Bank July 1, 1974	–$ 219.54
Receipts	17,129.00
	$16,909.46
Disbursements	10,504.67
Cash in Bank March 15, 1975	$ 6,404.79

9/19/62 Series E Bond $10,000 ($13,072.00)

10/13/72 Savings Certificate $6,002.17 ($6,857.59)

Respectfully submitted,

G. Dekle Taylor, M.D., Treasurer

PRESIDENT BROWN: Deke, there is one thing that I have never understood since the report of last year, and that is if you have deficit spending, does that mean deficit to the amount of income or deficit to the total in the treasury?

SECRETARY TAYLOR: That is the deficit to the income for that year. We did not have any in the bank though last year and we just held up the checks until some of the membership sent in some money, except for the bond and the savings certificate of deposit. We were that bad off.

PRESIDENT BROWN: We were next door to borrowing money.

SECRETARY TAYLOR: I was going to write you a letter next week. I think things will be very good now, if you do not complain about your banquet expense. We should be in good shape.

PRESIDENT BROWN: Is there a motion to accept this report?

DR. BORDLEY: So moved.

PRESIDENT BROWN: And, a second?

DR. BARON: Second.

PRESIDENT BROWN: Now, is there any discussion about this report? (No response.) All in favor say "aye"; opposed "no." (The motion carried.)

The report of the Editor-Librarian!

REPORT OF THE EDITOR-LIBRARIAN, APRIL 1975

Mr. President, in September 1974, 299 announcement letters regarding the availability of Volume LXII of the American Otological Society, Inc. were mailed. In November 1974, 545 copies of Volume LXII were published by the Society at a cost of $5,036.51. In December 1974, 485 copies were mailed directly by the publisher with a breakdown as follows: Senior members, 6; Emeritus members, 5; Associate members, 25; Honorary members, 5; Active members, 117; continuous subscribers, 255; noncontinuous subscribers, 72; for a total of 485.

Of the remaining 60 volumes, 16 have been sent to individuals ordering volumes since the original publication and distribution.

Receipts to date from the continuous and noncontinuous subscribers is $4,099.

As you heard from the Treasurer, the Transactions is our largest, by far, single expense. We hope in the next few months to crack the nut. We hope to get the last $1,000 so the Transactions is paying for itself, with the addition, you understand, of all active members getting the Transactions free, as part of their dues.

We are looking actively into ways of cutting costs of the Transactions. We obtained permission from the Council this week to cut pages. The printing costs, the binding costs have all gone up and are escalating every year, sometimes several jumps a year so we are looking at ways of cutting costs. For example, every five years now, instead of annually, we will list the past officers and the deceased members of the Society, which will allow us to cut the pages of the Transactions by ten to fifteen pages each year.

There is another thing we have noticed. In checking the archives of the Society, we are deficient in certain volumes. We did find a precious Volume I (1868) of the Society and we have it in our rare books section at the University. This beautiful little volume has just four pages, and we are going to publish it in the next issue of the Transactions. It is the wellspring of our Society.

We are lacking other volumes however and if you have your pencil in front of you, please write these down. We are missing Volumes for the years 1882, 1883, 1884, 1885, 1886, and 1887; 1919, 1921, 1928, 1944, and 1958.

Now, if any of you have these and are willing to surrender them so that the archives can be complete, I would very much appreciate it. I will also solicit these volumes from selected book dealers, libraries, widows of deceased members, and any place I can get them and any fair price you would want to put on them would be honored by the Council.

Respectfully submitted,

Brian F. McCabe, M.D., Editor-Librarian

PRESIDENT BROWN: Now, are you clear about what Brian said about publishing the list of the deceased members and past officers every five years?

And, I am asking the question because we want to know if that is satisfactory to members of the American Otological Society. Is there a motion to accept the report?

DR. MANSFIELD SMITH: So moved.

DR. WARD: Second.

PRESIDENT BROWN: Discussion? (No response.) All in favor say "aye"; opposed "no." (The motion carried.)

We are ready for the report of the Chairman of the Board of Trustees of the Research Fund, Dr. McLaurin! (Whereupon Dr. James W. McLaurin read the prepared report.)

REPORT OF THE CHAIRMAN OF THE BOARD OF TRUSTEES OF THE RESEARCH FUND

The Annual Meeting of the Trustees of the Research Fund of the American Otological Society was held March 1, 1975 in New York.

In attendance were Dr. J. McLaurin, Chairman, Dr. M. Schiff, Secretary, Dr. V. Goodhill, Dr. D. Hilding, Dr. M. Paparella, Dr. H. Tabb, and Dr. L. Brown, ex officio. Consultants in attendance were Dr. R. Thalmann, Dr. G. Weaver and Dr. M. Lawrence. Absent were Dr. G. Nager and consultant Mr. H. Marshall.

On Febrary 24, 1975, the principal account of the Research Fund shows a market value of $1,849,257 which represents a 25.2% decrease from last year at the same time. This with the 15.5% decrease in 1974 makes a total of 40.7% for the two years. Most of this loss is the result of the decline of the common stocks. Because of this decline it was thought it would be wise to interview other investment counsels. At the meeting, in addition to hearing from the Morgan Guaranty Trust Company, the Inverness Counsel, Inc., and Founders Capital Management Corporation were interviewed. It was then decided to turn the funds over to the Founders Capital Management Corporation.

Four requests for renewal of grants were received. Three of these were granted and one refused. No new research grant proposals were received.

The grants awarded totaled $32,610. Previously approved grants to be paid total $17,027 and approximately $12,000 will be needed for expenses which makes a total of $61,637. This will be well covered by the anticipated income of approximately $68,000 and it will not be necessary to draw from the accumulated income account or principal.

Dr. Victor Goodhill was elected Chairman of the Trustees for the forthcoming year. Dr. M. Schiff will continue as Secretary and Treasurer and Dr. D. Hilding was elected Secretary-Treasurer-elect. Dr. R. Gacek was elected Trustee to replace Dr. J. McLaurin, who retires this year.

Respectfully submitted,
James W. McLaurin, M.D., Chairman

PRESIDENT BROWN: Gentlemen, you have heard the report of this Research Fund and I would like to call your attention to one thing that Dr. McLaurin said – the funds of the Research Fund investments have been changed from one company to another. Now, is there any question about that? (No response.) Is there a motion to accept this report?

DR. WARD: So moved.

DR. SENTURIA: Second.

PRESIDENT BROWN: Discussion? (No response.) All in favor say "aye"; opposed "no." (The motion carried.)

The next report will be of the Representative to the American National Standards Institute, Inc., Dr. Tonndorf!

REPORT OF THE REPRESENTATIVE TO THE AMERICAN NATIONAL STANDARDS INSTITUTE, INC.

I would like to report on two standard activities that are of interest to Otologists: 1) the rewriting of the 1969 audiometer standards and, 2) the newly proposed standard on "Noise Exposure Criteria."

1. *Audiometer Standard.* The revised audiometer standard has cleared a number of points on which the old standard was unclear and ambiguous. For the first time, it will also contain some quality requirements for parts to be used in the construction of audiometers. Two years ago, I had personally made a survey among users of audiometers, asking for the frequency of breakdown of certain components and other appropriate comments, and the information obtained by that survey then provided a basis for quality requirements. The revised standard is out for voting by the S-3 Standards Committee and should soon be approved.

2. *The "Noise Exposure Criteria."* This proposed standard has been completely rewritten, because its original version was turned down two years ago by the S-3 Committee. A third draft of the rewrite has just been debated by the newly appointed Writing Group in Austin, Texas, and a final version is being prepared by me, as the Chairman of the Writing Group. It will be submitted for voting to the S-3 Standards Committee this summer. This standard will, in my opinion, fulfill a widely felt need.

Respectfully submitted,
J. Tonndorf, M.D.

PRESIDENT BROWN: You have heard the report by Dr. Tonndorf. Is there a motion to accept his report?

DR. WARD: So moved.

DR. SMITH: Second.

PRESIDENT BROWN: Any discussion? (No response.) All in favor say "aye"; opposed "no." (The motion carried.)

Next, a report of the American Board of Otolaryngology, Dr. Moore!

REPORT OF THE AMERICAN BOARD OF OTOLARYNGOLOGY

As one of your representatives to the American Board of Otolaryngology, I am privileged to report to you the following:

The year 1974 marked the 50th anniversary of the American Board of Otolaryngology. This occasion was celebrated on the evening of October 30, 1974 in the form of an anniversary banquet, held in Chicago, at "Darves 95th" in the John Hancock Center. The banquet was fully attended by the Directors, Senior Counselors of the Board and their wives. The banquet was a most festive occasion and a grand success, thanks to the special efforts of Wesley Bradley, Chairman of the dinner committee.

At the 1974 business meeting, the subject of recertification was fully discussed. At the present time it is the position of the Board that recertification should be on a voluntary basis and probably will be offered beginning in 1978.

The most recent certifying examination by the Board was held in Chicago in the Palmer House, October 29th through November 7th, 1974. Three hundred eighty-one candidates were examined. Slightly over 25% of these 381 candidates (97) were foreign medical school graduates. Approximately 72% (275) passed the examination and were certified as Diplomates of the American Board of Otolaryngology. Of the 97 foreign medical school graduates, 63, or approximately 65%, failed the examination. One hundred six candidates, or approximately 28% of the 381 total, failed the examination.

The deadline for receipt of applications for the 1975 certifying examinations of the American Board of Otolaryngology is May 1, 1975.

The 1975 certifying examination will be given in the Palmer House in Chicago, November 15 through November 21, 1975.

Respectfully submitted,

James A. Moore, M.D.

PRESIDENT BROWN: Is there a motion to accept this report?

DR. BORDLEY: So moved.

PRESIDENT BROWN: A second?

DR. BARON: Second.

PRESIDENT BROWN: Any questions? (No response.) All in favor say "aye"; opposed "no." (The motion carried.)

The next report is the Award of Merit report. Dr. Bordley!

DR. BORDLEY: Mr. President, in September 1974, the Award of Merit Committee met and very quickly and unanimously chose Catherine A. Smith. It was probably the pleasantest experience that committee, or the people on that committee, ever had. Thank you.

PRESIDENT BROWN: Catherine, stand up and take a bow! (Whereupon Dr. Catherine A. Smith then stood up to be recognized.)

The next report will be the report of the American College of Surgeons, Bev Armstrong!

REPORT OF THE BOARD OF GOVERNORS OF THE AMERICAN COLLEGE OF SURGEONS

The Board of Governors convened on Sunday, October 20, 1974. Dr. Claude E. Welch, President of the College, noted that Professional Standards Review Organizations continue to receive a lot of publicity. He observed that there had been a great change in PSRO since beginning to respect norms, criteria, and standards as guides in evaluating quality medical care. He does not expect PSRO to duplicate what is being done by other organizations and does not anticipate their becoming an over-riding system that supersedes the Joint Commission. After this note of optimism, he concluded that PSRO remains in a state of flux.

The importance of continuing education was stressed by Dr. Frank E. Stinchfield, Chairman of the Board of Regents. He believes voluntary participation to be far superior to a program induced by threats of recertification. He recommended the formation of a Department for Continuing Education and the cooperation of all surgical specialties in developing proposals for specific studies.

The American College of Surgeons is concerned over the medical liability problem that threatens to reach crisis proportions. A number of the programs considered by the Governors have been submitted to the Board of Regents for approval or possible future implementation.

Respectfully submitted,
B. W. Armstrong, M.D.

PRESIDENT BROWN: Thank you. This takes care of the reports. Our next order of business will be the report of the Nominating Committee, Dr. Davison!

DR. FRANCIS DAVISON: Dr. Brown and Fellow Members, your Nominating Committee, consisting of Drs. Davison, Work, Proud, Miles Lewis and Harold Boyd met yesterday and gave serious consideration to selecting good men to carry out the best interests of this Society in the next twelve months.

We would like to present for your consideration the names of: Victor Goodhill; Harold Schuknecht; Dekle Taylor; Brian McCabe; Wesley Bradley; Lester Brown; Cary N. Moon, Jr.; and Eugene Derlacki.

PRESIDENT BROWN: Gentlemen, you have heard the report of the Nominating Committee. What is your pleasure?

DR. BARON: Mr. President, I move that nominations be closed.

PRESIDENT BROWN: And, a second?

DR. LURIE: Second.

PRESIDENT BROWN: Discussion? (No response.) All in favor say "aye"; opposed "no." (The motion carried.)

DR. LURIE: I move the Secretary cast one ballot for the slate.

DR. BARON: Second.

PRESIDENT BROWN: All in favor say "aye"; opposed "no." (The motion carried.)

There will be a meeting of the Council immediately after the business session, before the scientific session, correct?

SECRETARY TAYLOR: Yes.

PRESIDENT BROWN: Is there any unfinished business? Dr. Taylor!

SECRETARY TAYLOR: We have two letters of appreciation for our contribution, one from the American Council of Otolaryngology and also the Centurion Club with the regret that we have cut our contribution to $500 from $1,000 and urged us to increase it in the future.

PRESIDENT BROWN: Gentlemen, you have heard this report, with regret and with hope. I do not believe this calls for any action. Unfinished Business! (No response.) New Business! Dr. Goodhill.

DR. VICTOR GOODHILL: Mr. President, Fellow Members: I should like to suggest under New Business the consideration of an honorary member of the American Otological Society. I believe we have not had an honorary membership in several years.

The name I am suggesting is Dr. Raphael Lorente de No.

Dr. Lorente was trained in laryngology and became interested in neural anatomy shortly after he finished a term as professor in otolaryngology in one of the Spanish medical schools. His work on the cochlear nucleus is a classic. He became one of the pioneers in what is now known as modern neurophysiology and he left the Deaf Institute in St. Louis and went to Rockefeller where he served until his retirement a year ago. He is now Visiting Professor of the Head and Neck Division at UCLA, having resumed his work on the cochlear nucleus and other areas dealing with inner ear anatomy and physiology.

What might not be known to the membership is the fact that he served for a number of years as a consultant on the Research Fund of this Society and I believe that it is appropriate at this point to suggest for consideration Dr. Lorente de No for honorary membership in this Society. Thank you, Mr. President.

PRESIDENT BROWN: This has already passed the Council and you have heard Dr. Goodhill's recommendation of honorary membership.

DR. MCCABE: So moved.

DR. LURIE: Second.

PRESIDENT BROWN: Any discussion? (No response.) All in favor say "aye"; opposed "no." (The motion carried). Have you anything further?

SECRETARY TAYLOR: Just one announcement about future meetings. It has been decided by the Secretaries that in the future, the meetings of the American Laryngological and the American Otological Society will take place at the beginning of the spring meeting. This next year, the Otological Society will meet on April 25 and 26 at The Breakers Hotel in Palm Beach, Florida. The banquet will be on the night of the 25th. The Laryngological will meet on Saturday preceding this and also on that Sunday so it is our hope in the future we will continue to do this rather than one meeting at the beginning of the week and one at the end of the week. We meet simultaneously and it will yet be decided whether the membership would rather have us alternate on who will meet first every year for two days or keep this one position all the time. We can discuss that at the next meeting.

In the letter that I will send to you when I return, I will include an application for your reservations at The Breakers Hotel and I urge you to send those in the day you get them. You can always cancel later if you are not going to come.

PRESIDENT BROWN: Will there also be an announcement of that second hotel that has been spoken of?

SECRETARY TAYLOR: Yes. The Colonnade Hotel is being considered. That is what he is talking about. We will let you know about that later.

PRESIDENT BROWN: Is there anything further that anyone wishes to take up this morning? (No response.)

I would like to ask for the members of the Council to come to the front of the auditorium. This ends the second business meeting. (The meeting adjourned at nine-five o'clock.)

(The business meeting was continued after termination of the Scientific Session.)

PRESIDENT BROWN: I want to thank you for this position of being your President of the Otological. We are getting ready to have a new President now and I have noticed one thing about this office, we have never had anyone to run for the office a second time and I do not know why that is. It may be that they just could not win anyhow!

But I do appreciate and wish to tell you that I regard this as the highest honor I have ever had or ever will have.

I appreciate the work of the speakers and I think that you noticed we have worked together to try and get the program done at a certain time, that was done, and in my opinion, it was accomplished with an excellent program and I am very thankful.

I wish to thank the projectionists for their hard work. We have had good equipment and they have done us a good job and I wish to thank them for that.

Now, if Dr. Senturia and Dr. Lurie would walk here with Dr. Goodhill, I do not think he needs holding up, but if you will walk up here with him, I would like to present you the President in 1975-76! (Whereupon newly elected President Victor Goodhill was then duly escorted to the podium.)

Ladies and gentlemen, I do want to say one thing. In addition to the great administrative work that Victor has done through the years, he has had tremendous experience in administration work, he may be the only person and if he is not we do not have but one other, who would be Dr. Fowler, Senior, who is at the same time President of the Otological and Chairman of the Otological Research Fund.

Now, those of you who have not kept up with that Fund, I think for a small organization like this to have a million and a half dollar research fund demands a great deal of observation and you can tell from the report that was made today with the change in investment companies from one to another, someone was doing a lot of thinking then.

In my one visit with that group, I feel that we need someone who can feel what the Otological needs and at the same time what the Research Fund needs and he certainly is the man to do it.

It is my duty, well, no, I started to say my duty, but it is really my pleasure to turn this gavel over to Victor. Here Victor, the gavel!

Dr. Victor Goodhill: Thank you, very very much. (Applause.) Thank you, very much, Lester. On behalf of all of us, I congratulate Dr. Lester Brown on this 1975 meeting.

He is a man of incomparable wit and charm and I knew that this would be present at the meeting and it was. He conducted it with a light heart and a light touch but with beautiful organization and the presentations were usually well done because he told people how to present them. He is going to be very hard to follow.

As my first task, very pleasant task, Lester, may I ask you to stand again! I would like to present this plaque:

American Otological Society, Inc.
Presented to Lester A. Brown, M.D., President
In Appreciation and Recognition of His Service to the Society, 1975

Lester! (Whereupon President Goodhill then presented the plaque to Dr. Brown, who was accorded a standing ovation.)

Dr. Brown: Thank you, Victor.

President Goodhill: Fellow Members, it is an awesome distinction to become the President of the American Otological Society.

The history of this Society is the history of scientific otology in America, but it is more; it is the history of honest confrontations and serious discussions.

Newness is not always progress!

The American Otological Society in this regard has been a model for America and indeed for international medicine.

It will be my privilege to serve as your President for the 109th Annual Meeting in 1976. This meeting, I shall repeat what has been said earlier, will be held at The Breakers Hotel, Palm Beach, Florida, April 25, Sunday morning and April 26, Monday morning.

The Annual Dinner will be held on Sunday evening, April 25. I hope to see all of you at this meeting. Have a good year! This concludes the 108th Annual Meeting. Thank you, very much. (Applause.)

(The meeting adjourned at eleven-fifty-two o'clock.)



BARRY J. ANSON

In Memoriam

BARRY J. ANSON

1894 - 1974

"We are like dwarfs seated on the shoulders of giants. If we see more and further than they, it is not due to our own clear eyes or tall bodies, but because we were raised on high and upborne by their gigantic bigness."

Bernard of Chartres, 1119 A.D.

This quotation was Barry Anson's favorite. That he truly believed it was typical of his kindness and humility. He believed himself, of course, the dwarf; but we, his legion of students, friends, and admirers know that in actuality, he was the giant and we, the dwarfs.

Barry Anson was in many respects a renaissance man. Besides being a renowned anatomist, he was a prodigious talent in the English language, an authority on the history of medicine, a chronicler of St. George and Ambroise Pare, and a world traveler. He also collected unicorns and oriental art.

It was a rare privilege to know Barry Anson. He was not only a kind, gentle and scholarly man but an indefatigable worker. At the age of 80 he was actively working on revisions of two of his surgical anatomy monographs and had commenced a new project on the vascularization of ossicular homografts. A basic scientist, he realized sooner than most that medical research is enriched by clinical relevance. A symbiotic relationship has developed between basic scientists and otolaryngologists the country wide. Barry fostered this and was a marvelous example of it. This is probably his greatest legacy.

BRIAN F. MCCABE, M.D.

WALTER PAGE COVELL, M.D.

WALTER PAGE COVELL, M.D.

1899 - 1974

It is with deep regret that we announce the death of Doctor Walter Page Covell on April 27, 1974. He passed away peacefully in his sleep. Dr. Covell was born in Corvallis, Oregon on December 22, 1899. He obtained his Bachelor of Science degree at Oregon State College in 1921, followed by a Master's degree in Zoology in 1923. He then transferred to the University of Minnesota and obtained a Ph.D. in Anatomy. He first came to Washington University in 1929 as an Assistant Professor in the Department of Anatomy. He always had an interest in research and its application to relieve human suffering and to better apply himself to this end he obtained a doctorate in medicine at the University of Chicago in 1933.

He studied temporal bone anatomy with Dr. Felix Nager in Zurich just prior to World War II and returned to this country as Assistant Professor of Research at U.C.L.A. in 1941. He returned to Washington University in 1945 where he stayed until his retirement from the position of Professor of Anatomy in Otolaryngology in 1967. During this time he was closely associated with the Central Institute for the Deaf. He published numerous papers on many different fields, but in the later years he was especially interested in morphologic changes of the inner ear occasioned by noise exposure.

Following his retirement he travelled widely and resided in Lisbon for a period of time before finally returning to California.

Dr. Covell was a most respected person in the Department of Otolaryngology at Washington University. He was always a friend to the numerous visitors and trainees who passed through the Department in the postwar years when Dr. Theodore Walsh was the Chairman of the Department. He went out of his way to seek out the visiting foreigners and made them welcome, often entertaining them in his own home. He gave excellent help and advice to the aspiring young scientists who worked with him and contributed so much to their development and maturation. He will be missed by so many.

MALCOLM H. STROUD, M.D.

FRANCIS L. WEILLE, M.D.

FRANCIS L. WEILLE, M.D.

1899 - 1974

Dr. Francis L. Weille entered Harvard Medical School in the autumn of 1921, arriving by train from the deep south, and went directly to the Medical School. He became so engrossed in his studies that he did not get to downtown Boston again until the holidays when he went to South Station to catch a train for home. In this way, the pattern for his lifestyle had been set.

At the close of World War II, Dr. Weille recognized that basic science should be brought into a teaching hospital, and he was most instrumental in bringing several basic science laboratories to the Massachusetts Eye and Ear Infirmary where he had received his training and where he did his major work. Among these were the Virology Laboratory, the Microcirculatory Laboratory, the Harold D. Walker Laboratory of Biochemistry, and the Eaton-Peabody Laboratory of Auditory Physiology.

Francis Weille was very active in the Boston Skating Club and quite a proficient figure skater in his own right. As a younger man, he did a great deal of horseback riding. He was an avid hunter, beginning such expeditions when living in Mississippi and later on in his beautiful country estate in New Hampshire. He would tramp as much as twenty miles through the woods looking for partridge. He spent much time skiing and golfing on his many trips to the Lake Placid Club, winter and summer, giving up his skiing when he reached the age of 65.

Despite Francis Weille's deep interest in medicine, particularly in the field of allergic rhinosinusitis, his wife was particularly impressed with his deep warmth, love of people, and awe of Nature — mountains, lakes, trees, sunsets — as well as his constant intellectual curiosity.

Only three years prior to his death, he was still one of the three busiest surgeons at the Massachusetts Eye and Ear Infirmary. His lifestyle could have been described as enigmatic, and his contributions meaningful to many people.

He will be missed by his unusually loyal patients and friends.

DANIEL MILLER, M.D.

HENRY LANE WILLIAMS, M.D.

HENRY LANE WILLIAMS, M.D.

1898 - 1974

At 2:00 A.M. on a snowy morning a solitary light went on in the study section of the Mayo Clinic Library. Bill Williams, reacting to the pain pattern of his ulcer and indulging a hobby, was preparing for a meeting.

Bill was a man of many hobbies, investing time, effort and often money in each. He supported several sporting goods shops and whether engaging in golf, fishing, hunting, or archery, his equipment was new, elaborate and of late design. He loved high speed driving, holding the unofficial record between Minneapolis and Rochester as well as the distinction of arrest on the 85 MPH Kansas Turnpike. His hobbies served his gregarious nature. He caught few fish but made the most of the camaraderie of the fishing camp. A period of residence in California while on active duty in the United States Navy introduced Bill to the fine art of wine tasting, and until interdicted by his ulcer, he took pride and pleasure in his selection of domestic vintages. A little known hobby was jazz music. Selections from his library of jazz classics provided a pleasant background for conversation in the Williams home.

Bill devoted his life to Oto-Rhino-Laryngology but showed signs of being a frustrated lawyer. He loved to argue, often for the sake of argument. These encounters with unsuspecting friends did not always occur by accident, and his success often resulted from prior research of the subject. In another favored diversion Bill would carefully set up a heated discussion, then sit back to enjoy the fireworks. The results were often both stimulating and educational.

Which brings us back to the solitary light in the study room. Bill's preparation for a meeting began with receipt of the program. While he read and retained a wide range of medical literature, he regularly reviewed program subjects in which he was interested, giving special attention to prior papers by the author. Arguments for or against the anticipated thesis were considered and documented. When at the call for discussion Bill lumbered to his feet from apparent slumber and shuffled to the podium, the Prosecution was prepared to summarize. His hobby had added a bit of salt and information to another meeting.

KINSEY M. SIMONTON, M.D.

MEMBERS
of the
American Otological Society
INC.

1974 - 1975

ACTIVE MEMBERS

1970	Dr. Bobby R. Alford	1200 Moursund, Houston, Tex. 77025
1964	Dr. Walter P. Anthony	321 N. Bailey Ave., Fort Worth, Tex. 76107
1960	Dr. Beverly W. Armstrong	1600 E. Third St., Charlotte, N.C. 28204
1969	Dr. H. A. Ted Bailey, Jr.	Medical Towers, Little Rock, Ark. 72205
1968	Dr. Hugh O. Barber	2075 Bayview Ave., Toronto 315, Ontario, Canada
1953	Dr. Shirley H. Baron	516 Sutter St., San Francisco, Calif. 94102
1965	Dr. Milos Basek	161 Ft. Washington Ave., New York, N.Y. 10032
1958	Dr. Richard J. Bellucci	162 E. 71st St., New York, N.Y. 10021
1970	Dr. Leslie Bernstein	Dept. of Otorhino. Univ. of Calif., Davis, Calif. 95616
1955	Dr. John E. Bordley	Johns Hopkins Hospital, Baltimore, Md. 21205
1963	Dr. Harold M. E. Boyd	1127 Wilshire Blvd., Los Angeles, Calif. 90057
1961	Dr. Wesley H. Bradley	1100 E. Genesee St., Syracuse, N.Y. 13210
1964	Dr. Seymour J. Brockman	469 N. Roxbury Drive, Beverly Hills, Calif. 90210
1953	Dr. Lester A. Brown	490 Peachtree St., N.E., Atlanta, Ga. 30308
1969	Dr. Richard A. Buckingham	434 Willow Road, Winnetka, Illinois 60096
1972	Dr. Ralph J. Caparosa	3600 Forbes Ave., Pittsburgh, Pa. 15213
1975	Dr. Francis I. Catlin	1200 Moursund, Houston, Tex. 77025
1973	Dr. J. Ryan Chandler	1700 N.W. 10th Ave., Miami, Fla. 33136
1958	Dr. Claude C. Cody, III	1010 Louisiana Ave., Houston, Tex. 77002
1969	Dr. D. Thane Cody	Mayo Clinic, Rochester, Minn. 55902
1966	Dr. James M. Cole	Geisinger Medical Center, Danville, Pa. 17821
1968	Dr. Wesley E. Compere, Jr.	5565 Grossmont Center Dr., La Mesa, Cal. 92042
1972	Dr. James A. Crabtree	1300 North Vermont Ave., Los Angeles, Cal. 90027
1961	Dr. John F. Daly	566 First Ave., New York, N.Y. 10016
1956	Dr. Francis W. Davison	Geisinger Medical Center, Danville, Pa. 17821
1975	Dr. Vijay S. Dayal	12 Harper Ave., Toronto, Ontario, Canada
1958	Dr. Eugene L. Derlacki	55 E. Washington, Chicago, Ill. 60602
1952	Dr. David D. DeWeese	3181 S.W. Sam Jackson Park Rd., Portland, Ore. 97201
1959	Dr. David A. Dolowitz	2000 So. 9th St., Salt Lake City, Utah 84105

1974 Dr. James A. Donaldson ....Otolaryngology Department, Univ. of Washington, Seattle, Wash. 98195

1971 Dr. Arndt J. Duvall ..... Dept. of Otolaryng., Univ. Hospital, Minneapolis, Minn. 55455

1957 Dr. J. Brown Farrior ..... 509 Bayshore Blvd., Tampa, Fla. 33606

1957 Dr. Meyer S. Fox ..... 2040 W. Wisconsin Ave., Milwaukee, Wis. 53217

1969 Dr. Richard R. Gacek ..... Dept. of Otolaryngology, Univ. of Mass. Medical School, Worcester, Mass. 01605

1973 Dr. Michael E. Glasscock, III ... 300 25th Ave., N. Nashville, Tennessee 37203

1959 Dr. Joseph L. Goldman ..... 1050 Park Ave., New York, N.Y. 10028

1959 Dr. Victor Goodhill .....469 N. Roxbury Drive, Beverly Hills, Calif. 90210

1973 Dr. Wilfred S. Goodman ..... Dept. of Otolaryng. Univ. of Toronto, Toronto, Ontario, Can.

1960 Dr. James A. Harrill .....3860 Reynolds Dr., Winston-Salem, N.C. 27104

1970 Dr. Irwin Harris .....469 N. Roxbury Dr., Beverly Hills, Calif. 90210

1973 Dr. Wiley H. Harrison ..... 55 E. Washington Street, Chicago, Ill. 60602

1972 Dr. William G. Hemenway .....1000 W. Carson St., Torrance, Cal. 90509

1955 Dr. Anderson C. Hilding .....Research Lab., St. Luke's Hosp., Duluth, Minn. 55805

1972 Dr. David A. Hilding ..... United Hospitals, 15 S. 9th St., Newark, N.J. 07107

1951 Dr. Jerome A. Hilger.....393 N. Dunlap, St. Paul, Minn. 55104

1970 Dr. Albert Hohmann ..... 393 N. Dunlap, St. Paul, Minn. 55104

1960 Dr. Jack V. Hough ..... 3400 N.W. 56th St., Oklahoma City, Okla. 73112

1947 Dr. Howard P. House ..... 2122 W. 3rd, Los Angeles, Calif. 90057

1964 Dr. William F. House ..... 2122 W. 3rd, Los Angeles, Calif. 90057

1953 Dr. Raymond E. Jordan .....740 Willowhead Dr., Naples, Fla. 33940

1954 Dr. Clair M. Kos..... 2440 Towncrest Dr., Iowa City, Iowa 52240

1949 Dr. Frank D. Lathrop.....R.F.D. #1, Pittsford, Vt. 05763

1963 Dr. Donald K. Lewis ..... 5 Emerson Place, Boston, Mass. 02114

1958 Dr. Miles L. Lewis, Jr. ..... 3600 Prytania St., New Orleans, La. 70115

1967 Dr. Fred H. Linthicum ..... 2122 West Third St., Los Angeles, Calif. 90057

1969 Dr. Ward B. Litton .....1630 Fifth Ave., Moline, Ill. 61265

1960 Dr. Karl Lowy .....187 S. Goodman St., Rochester, N.Y. 14607

1933 Dr. Moses H. Lurie.....483 Beacon St., Boston, Mass. 02115

1970 H. Edward Maddox, III ... 1600 Memorial Prof. Bldg., Houston, Tex. 77002

1975 Dr. Richard E. Marcus .....64 Old Orchard, Skokie, Ill. 60076

1956 Dr. Kenneth McAskile ..... 20 Wynford Drive, Don Mills, Ontario, Canada

1965 Dr. Brian F. McCabe .....University Hospitals, Iowa City, Ia. 52240

1959 Dr. Francis H. McGovern .....139 So. Main St., Danville, Va. 24541

1951 Dr. James W. McLaurin ..... 3888 Government St., Baton Rouge, La. 70806

1952 Dr. Ralph J. McQuiston.....20 N. Meridian St., Indianapolis, Ind. 46204

1974 Dr. Robin P. Michelson .....HSE 863 Univ. of Cal., San Francisco, Cal. 94143

1975 Dr. William W. Montgomery ..... 243 Charles St., Boston, Mass. 02114

1965 Dr. Cary N. Moon ..... 1000 E. High St., Charlottesville, Va. 22901

1952 Dr. James A. Moore.....525 E. 68th St., New York, N.Y. 10021

1962 Dr. Rufus C. Morrow .....Pine Haven Shore, Shelburne, Vt. 05482

1957 Dr. David Myers ..... 2401 Pennsylvania Ave., Philadelphia, Pa. 19130

1974 Dr. Eugene N. Myers .....Department of Otolaryngology, University of Pittsburgh, Pittsburgh, Pa. 15213
1968 Dr. George T. Nager ..... 4403 Bedford Pl., Baltimore, Md. 21218
1968 Dr. Ralph F. Naunton ..... 950 E. 59th St., Chicago, Ill. 60637
1968 Dr. Michael M. Paparella ..... Univ. Hospital, Minneapolis, Minn. 55455
1973 Dr. Claude L. Pennington ..... 800 First Street, Macon, Georgia 31201
1975 Dr. W. Hugh Powers ..... 2122 W. Third St., Los Angeles, Cal. 90057
1965 Dr. Bruce Proctor ..... 3535 W. 13 Mile Road, Royal Oak, Mich. 48072
1959 Dr. Gunner O. Proud ..... Univ. of Kansas Med. Cent., Kansas City, Kans. 66103
1969 Dr. Jack L. Pulec ..... 2122 W. Third St., Los Angeles, Cal. 90057
1958 Dr. J. H. Thomas Rambo ..... 150 E. 77th St., New York, N.Y. 10021
1972 Dr. Frank N. Ritter ..... 2675 Englave, Ann Arbor, Michigan 48103
1969 Dr. Mendell Robinson ..... 130 Waterman St., Providence, R.I. 02906
1967 Dr. Bernard J. Ronis ..... 2106 Spruce St., Philadelphia, Pa. 19103
1972 Dr. Max L. Ronis ..... 2106 Spruce St., Philadelphia, Pa. 19103
1945 Dr. Harry Rosenwasser ..... 115 E. 61st St., New York, N.Y. 10021
1974 Dr. Robert J. Ruben .....Albert Einstein College of Medicine, Rm. 3C37 VE, 1300 Morris Park Ave., Bronx, N.Y. 10461
1967 Dr. Wallace Rubin ..... 3333 Kingman St., Metairie, La. 70002
1967 Dr. Richard L. Ruggles ..... 10515 Carnegie Ave., Cleveland, O. 44106
1960 Dr. Joseph Sataloff ..... 1721 Pine St., Philadelphia, Pa. 19103
1972 Dr. William H. Saunders ..... University Hospital, Columbus, Ohio 43210
1967 Dr. Maurice Schiff ..... 7255 Girard Ave., LaJolla, Cal. 92037
1966 Dr. Woodrow D. Schlosser ... 2401 Pennsylvania Ave., Philadelphia, Pa. 19130
1957 Dr. Harold Schuknecht ..... Mass. Eye and Ear Infirmary, 243 Charles St., Boston, Mass. 02114
1951 Dr. Ben H. Senturia ..... 4949 Forest Park Blvd., St. Louis, Mo. 63108
1950 Dr. George Shambaugh, Jr. ..... 55 E. Washington St., Chicago, Ill. 60602
1967 Dr. John J. Shea ..... 1060 Madison Ave., Memphis, Tenn. 38104
1965 Dr. James L. Sheehy ..... 2122 W. 3rd St., Los Angeles, Calif. 90057
1961 Dr. Louis E. Silcox ..... 108 Lankenau Med. Bldg., Philadelphia, Pa. 19151
1973 Dr. Herbert Silverstein ..... 1849A Hawthorne St., Sarasota, Fla. 33579
1973 Dr. F. Blair Simmons ..... Stanford University Med. Center, Stanford, Calif. 94305
1952 Dr. Kinsey M. Simonton 960 Johnson Ferry Rd., Suite 320, Atlanta, Ga. 30342
1972 Dr. George T. Singleton ..... 1421 N.W. 47th Terr., Gainesville, Fla. 32601
1958 Dr. J. Brydon Smith .. 1 Medical Place, 20 Wynford Dr., Don Mills, Ont., Can.
1973 Dr. Mansfield F. W. Smith ..... 2120 Forest Avenue, San Jose, Calif. 95128
1973 Dr. James B. Snow, Jr. .... Univ. of Pennsylvania Hospital, 3400 Spruce Street, Philadelphia, Pennsylvania 19104
1961 Dr. Francis A. Sooy ..... #9 - 5th Ave., San Francisco, Cal. 94118
1967 Dr. Malcolm H. Stroud ..... 11318 Conway, St. Louis, Mo. 63131
1961 Dr. Harold G. Tabb ..... 1430 Tulane Ave., New Orleans, La. 70112
1965 Dr. G. Dekle Taylor ..... Marshall Taylor Doctors' Bldg., Jacksonville, Fla. 32207
1974 Dr. Nicholas Torok ..... 4250 Marine Dr., Chicago, Ill. 60613
1962 Dr. Jules G. Waltner ..... 161 Ft. Washington Ave., New York, N.Y. 10032
1972 Dr. Paul H. Ward ..... UCLA School of Medicine, Los Angeles, Cal. 90024
1975 Dr. Roger E. Wehrs ..... Suite 410, 6465 S. Yale, Tulsa, Okla. 74136

1972 Dr. William H. Wilson.....1855 Gaylord, Denver Colorado 80206

1964 Dr. Ben T. Withers ..... 904 Hermann Prof. Bldg., Houston, Tex. 77025

1971 Dr. Robert J. Wolfson .....1920 Chestnut St., Philadelphia, Pa. 19103

1953 Dr. Walter P. Work.....Univ. of Michigan Med. Ctr., Ann Arbor, Mich. 48104

1964 Dr. Wm. K. Wright ..... 540 Hermann Prof. Bldg., Houston, Tex. 77025

SENIOR MEMBERS

1969 (1944) Dr. Lawrence R. Boies.....Box 396, University Hospital, Minneapolis, Minn. 55455

1973 (1952) Dr. Greydon G. Boyd .....76 N.E. 51st Lane, Box 1226, Delray Beach, Fla. 33441

1966 (1944) Dr. Paul A. Campbell .....700 E. Hildebrand #401, San Antonio, Tex. 78212

1964 (1941) Dr. Norton Canfield .....229 Montowese St., Branford, Conn. 06405

1969 (1952) Dr. James E. Croushore.....561 N.E. Golden Harbour Dr., Boca Raton, Fla. 33432

1971 (1939) Dr. Joseph G. Druss .....1040 Park Ave., New York, N.Y. 10028

1967 (1945) Dr. Ben R. Dysart ..... 523 Vulcan Ave., Encinitas, Calif. 92024

1974 (1953) Dr. G. Slaughter Fitz-Hugh ....2003 Spottswood Rd., Charlottesville, Va. 22903

1962 (1939) Dr. Thomas C. Galloway..... 636 Church St., Evanston, Ill. 60201

1973 (1953) Dr. Aram Glorig .....5539 Farquhar Lane, Dallas, Texas 75209

1961 (1937) Dr. Henry M. Goodyear... 2012 Edgecliff Point, Cincinnati, O. 45206

1958 (1930) Dr. Robert J. Hunter..... 928 N. 63rd St., Philadelphia, Pa. 19151

1972 (1952) Dr. Arthur L. Juers.....1800 N. Federal Hgwy., Pompano Beach, Fla. 33062

1962 (1957) Dr. George Keleman ..... 2122 W. 3rd St., Los Angeles, Cal. 90057

1971 (1935) Dr. Dean M. Lierle.....University Hospital, Iowa City, Ia. 52240

1966 (1944) Dr. John R. Lindsay.....5801 Dorchester, Chicago, Ill. 60637

1953 (1930) Dr. Merrick F. McCarthy..... 960 Hollytree Dr., Cincinnati, O. 45231

1970 (1931) Dr. William J. McNally ..... 1509 Sherbrooke St. West, Montreal 25, Que., Can.

1973 (1952) Dr. Peter N. Pastore ....5503 Riverside Drive, Richmond, Va. 23225

1970 (1950) Dr. George L. Pattee...6973 B East Girard Ave., Denver, Colo. 80222

1969 (1945) Dr. Aubrey G. Rawlins.....384 Post St, San Francisco, Cal. 94108

1973 (1937) Dr. Samuel Rosen.....101 E. 73rd Street, New York, N.Y. 10021

1961 (1937) Dr. LeRoy A. Schall.....121 Winfield Rd., Princeton, N.J. 08540

1962 (1936) Dr. Harry P. Schenck..... 1235 Wyngate Rd., Wynnewood, Pa. 10906

1970 (1952) Dr. John D. Singleton.....6815 Wander Place, Dallas, Texas 75230

1971 (1947) Dr. Edwin A. Stuart.....1390 Sherbrooke St., W., Montreal 25, Que., Can.

1969 (1947) Senator Joseph A. Sullivan . 20 Wynford Dr., Don Mills, Ont. Can.

1968 (1956) Dr. G. Edward Tremble.....3940 Cote Des Neiges, Montreal 25, Que., Canada

1972 (1946) Dr. Edward H. Truex.....85 Jefferson St., Hartford, Conn. 06103

1961 (1940) Dr. Earl L. Wood..... 225 Ballantine Pkwy., Newark, N.J. 07104

1967 (1953) Dr. DeGraaf Woodman..... P. O. Box 560, Easton, Md. 21601

EMERITUS MEMBERS

1971 (1961) Dr. Olav E. Hallberg ..... 10709 Hutton Dr., Sun City, Ariz. 85351
1970 (1953) Dr. Fred Harbert ..... Jefferson Med. Coll. of Phila., Philadelphia, Pa. 19107
1969 (1952) Dr. Robert C. McNaught ... 15 Edgewater Rd., Belvedere, Cal. 94920
1962 (1952) Dr. Henry B. Perlman ..... 5448 E. View Park, Chicago, Ill. 60621
1971 (1956) Dr. Ernest E. Scharfe 1414 Drummond St., Montreal 25, Que., Can.
1973 (1957) Dr. John F. Tolan ..... 3419 47th Ave., N.E. Seattle, Wash. 98105

ASSOCIATE MEMBERS

1961 Raymond Carhart, Ph.D. ... Hearing Clinic, Northwest'n U., Evanston, Ill. 60201
1950 Hallowell Davis, M.D. ..... Central Institute for the Deaf, 818 S. Euclid, St. Louis, Mo. 63110
1965 Gosta Dohlman, M.D. ..... 100 College Street, Toronto, Ontario, Canada
1973 Cesar Fernandez, M.D. ..... 5819 S. Blackstone Ave., Chicago, Illinois 60637
1959 Ashton Graybiel, M.D. ..... Bayshore, Pensacola, Florida 32512
1957 William G. Hardy, Ph.D. ..... Johns Hopkins Hospital, Baltimore, Md. 21205
1972 Joseph E. Hawkins, Jr., Ph.D. ..... 4004 E. Joy Rd., Ann Arbor, Mich. 48105
1972 Vicente Honrubia, M.D. . 850 N. Beverly Glen Blvd., Los Angeles, Cal. 90024
1973 Makoto Igarashi, M.D. ..... Baylor College of Medicine, Houston, Texas 77025
1960 Walter H. Johnson, M.D. .. Dept. of Otolaryngology, U. of Toronto, Ont., Can.
1969 Nelson Y. S. Kiang, Ph.D. ..... 253 Washington St., Belmont, Mass. 02178
1959 Merle Lawrence, Ph.D. ..... University of Michigan Medical School, Kresge Hearing Research Institute, Ann Arbor, Mich. 48104
1973 David J. Lim, M.D. ..... University Hosp., 320 W. 10th Ave., Columbus, Ohio 43210
1956 Scott N. Reger, Ph.D. ..... 2 Knollwood Lane, Iowa City, Ia. 52240
1970 Walter A. Rosenblith, Ph.D. ..... 164 Mason Terrace, Brookline, Mass. 02146
1975 Isamu Sando, M.D. ..... Dept. of Otolaryngology, Univ. of Colorado School of Medicine, 4200 East Ninth Ave., Denver, Colo. 80220
1950 S. Richard Silverman, Ph.D. ..... Central Institute for the Deaf, 818 S. Euclid, St. Louis, Mo. 63110
1962 Catherine A. Smith, Ph.D. ..... Dept. of Otolaryng. U. of Oregon Med Sch., Portland, O. 97200
1971 Ruediger R. Thalmann, M.D. ..... 4466 West Pine, St. Louis, Mo. 63108
1961 Juergen Tonndorf, M.D. ..... College of Phys. and Surg. of Columbia University, 630 W. 168th St., New York, N.Y. 10032
1970 Galdino E. Valvassori, M.D. ..... 55 E. Washington St., Chicago, Ill. 60602
1974 Dr. Jack A. Vernon ..... 3181 S.W. Sam Jackson Park Rd., Portland, Ore. 97201
1971 W. Dixon Ward, Ph.D. ... Box 461 Mayo, U. of Minn., Minneapolis, Minn. 55455
1957 Ernest G. Wever, Ph.D. ... 110 Eno Hall, Princeton Univ., Princeton, N.J. 08540
1961 Dorothy Wolff, Ph.D. ..... Meadow Lakes Apt. 48-08U, Hightstown, N.J. 08520

HONORARY MEMBERS

1946 Sir Alex W. G. Ewing, Ph.D. ..... Univ. of Manchester, Manchester 13, England
1936 Harvey Fletcher, Ph.D. .. Brigham Young Univ., Science Bldg., Provo, U. 84601
1968 L. B. W. Jongkees, M.D. ..... Wilhelmina Gasthuis, Amsterdam, Netherlands
1952 Luzius Ruedi, M.D. ..... 16 Borsenstraasse, Zurich, Switzerland
1968 Horst Wullstein, M.D. ..... Director, Univ. Clinic HNO, Wurzburg, Germany
1975 Raphael Lorente de No, M.D. ... Div. of Head and Neck Surgery, UCLA School of Medicine, Los Angeles, Cal. 90024

INDEX

to the

TRANSACTIONS

of the

AMERICAN OTOLOGICAL SOCIETY
INC.

1975

INDEX OF AUTHORS

A

Abramson, Maxwell 80
Adour, Kedar K. 88
Asarch, Richard G. 80

B

Babin, Richard 132
Bergstrom, LaVonne 114
Boles, Roger 36
Brody, Sidney 67
Burgio, Paul A. 23

C

Calcaterra, Thomas C. 132

D

Doty, H. E. 88

F

Filipo, Roberto 67

G

Glasscock, Michael E. 54
Graham, Malcolm D. 141

H

Hanson, David G. 116
Hays, James W. 54
Hilsinger, Raymond 88
House, William F. 17
Hybels, Roger 36

I

Izumi, Soji 114

K

Kamio, Tomokazu 141
Konrad, H. R. 132

L

Lawrence, Merle 23
Leiberman, Alberto 114
Linthicum, Fred H., Jr. 67
Litton, Ward B. 80

M

Merzenich, Michael M. 18
Michelson, Robin P. 18
Murphy, James P. 54

N

Nager, George T. 130
Nuttall, Alfred L. 23

P

Paparella, Michael M. 116
Perkins, Rodney 42
Pulec, Jack L. 141

R

Rao, K. N. 116
Rice, Dale H. 36
Rubin, Wallace 64

S

Sando, Isamu 114
Sataloff, Joseph 51
Schindler, David N. 18
Schindler, Robert A. 18
Smith, Catherine A. 98
Smith, Mansfield F. W. 75

U

Ulvestad, Rolf 116

W

Ward, Paul H. 132
Wood, Raymond P. 114
Work, Walter P. 36

INDEX OF SUBJECTS

A

Acoustic Neuroma Surgery, Complications in (M. E. Glasscock III, J. W. Hays, J. P. Murphy) ... 54

Award of Merit
- Presentation of ... 151
- Previous Recipients of ... 153

B

Bone Resorption, Experimental Aural Cholesteatoma Causing (M. Abramson, R. G. Asarch, W. B. Litton) ... 80

Business Meetings
- April 11, 1975 ... 155
- April 12, 1975 ... 158

C

Cholesteatoma, Experimental Aural, Causing Bone Resorption (M. Abramson, R. G. Asarch, W. B. Litton) ... 80

Cochlea, Innervation of, in the Guinea Pig by Use of the Golgi Stain (C. A. Smith) ... 98

Cochlear Implant: Current Status, Abstract (W. F. House) ... 17

Cochlear Otospongiosis, Sensorineural Hearing Loss Due to: Theoretical Considerations of Etiology (F. H. Linthicum, Jr., R. Filipo, S. Brody) ... 67

Cochlear Potentials and Oxygen Associated with Hypoxia (M. Lawrence, A. L. Nuttall, P. A. Burgio) ... 23

Cochlear Prosthesis, Present Status and Future Development of (R. P. Michelson, R. A. Schindler, M. M. Merzenich, D. N. Schindler) ... 18

Communications ... 165

Complications in Acoustic Neuroma Surgery (M. E. Glasscock III, J. W. Hays, J. P. Murphy) ... 54

Conservative Management of Ménière's Disease: Furstenberg Regimen Revisited (R. Boles, D. H. Rice, R. Hybels, W. P. Work) ... 36

E

Ear Surgery, Reconstructive, Grafting Materials and Methods (R. Perkins) ... 42

Election of
- Council ... 165
- New Members ... 155
- Nominating Committee ... 156

Electronystagmography: A Review of 17 Years Experience (W. Rubin) ... 64

Eustachian Tube Lymphatics (J. L. Pulec, T. Kamio, M. D. Graham) ... 141

Experimental Aural Cholesteatoma Causing Bone Resorption (M. Abramson, R. G. Asarch, W. B. Litton) ... 80

F

Facial Paralysis, Idiopathic, Pregnancy, and the Menstrual Cycle (R. L. Hilsinger, Jr., K. K. Adour, H. E. Doty) ... 88

G

Genetic Sensorineural Deafness in Adults (M. M. Paparella, D. G. Hanson, K. N. Rao, R. Ulvestad) ... 116

Golgi Stain, Innervation of the Cochlea of the Guinea Pig by Use of (C. A. Smith) ... 98

Grafting Materials and Methods in Reconstructive Ear Surgery (R. Perkins) ... 42

Guest of Honor
- Introduction of ... 14
- List of Previous ... 154
- Remarks of ... 15

Guests ... 10

H

Histopathological Findings, Temporal Bone, in Trisomy 13 Syndrome, Abstract (I. Sando, A. Leiberman, L. Bergstrom, S. Izumi, R. P. Wood II) ... 114

Hypoxia, Cochlear Potentials and Oxygen Associated with (M. Lawrence, A. L. Nuttall, P. A. Burgio) ... 23

I

Implant, Cochlear: Current Status, Abstract (W. F. House) ... 17

Industrial Hearing Conservation and Otology (J. Sataloff) ... 51

In Memoriam
- Barry J. Anson ... 169
- Walter Page Covell ... 171
- Fraces L. Weille ... 173
- Henry Lane Williams ... 175

Innervation of the Cochlea of the Guinea Pig by Use of the Golgi Stain (C. A. Smith) ... 98

Introduction of
- Award of Merit Recipient ... 151
- Guest of Honor ... 14
- President-Elect ... 167

L

Lymphatics of Eustachian Tube (J. L. Pulec, T. Kamio, M. D. Graham) ... 141

M

Meetings
Business 155, 158
Sites and Dates, Future 166

Members
Active 176
Associate 180
Emeritus 180
Honorary 180
New, Election and Presentation of 155
Registration of 9
Senior 179

Ménière's Disease, Conservative Management of: Furstenberg Regimen Revisited (R. Boles, D. H. Rice, R. Hybels, W. P. Work) 36

Menstrual Cycle, Idiopathic Facial Paralysis, Pregnancy, and (R. L. Hilsinger, Jr., K. K. Adour, H. E. Doty) 88

N

Nominating Committee
Election of 156
Report of 165

O

Objective Tinnitus, Operative Treatment of Surgical Lesions with (P. H. Ward, R. Babin, T. C. Calcaterra, H. R. Konrad) 132

Officers 7

Open Mastoidectomy Ear, Reconstruction of: A Six Year Progress Report (M. F. W. Smith) 75

Operative Treatment of Surgical Lesions with Objective Tinnitus (P. H. Ward, R. Babin, T. C. Calcaterra, H. R. Konrad) 132

Otology and Industrial Hearing Conservation (J. Sataloff) 51

Otospongiosis, Cochlear, Sensorineural Hearing Loss Due to: Theoretical Consideration of Etiology (F. H. Linthicum, Jr., R. Filipo, S. Brody) 67

P

Paget's Disease of the Temporal Bone, Absract (G. T. Nager) 130

Photo of Members 5

Pregnancy, Idiopathic Facial Paralysis, Menstrual Cycle and (R. L. Hilsinger, Jr., K. K. Adour, H. E. Doty) 88

Present Status and Future Development of the Cochlear Prosthesis (R. P. Michelson, R. A. Schindler, M. M. Merzenich, D. N. Schindler) 18

Presentation of the Award of Merit to C. A. Smith, Ph.D. 98

Prosthesis, Cochlear, Present Status and Future Development of (R. P. Michelson, R. A. Schindler, M. M. Merzenich, D. N. Schindler) 18

R

Recipients of Award of Merit 153

Reconstruction of Open Mastoidectomy Ear: A Six Year Progress Report (M. F. W. Smith) 75

Reconstructive Ear Surgery, Grafting Material and Methods in (R. Perkins) 42

Report of
American Board of Otolaryngology 164
American College of Surgeons 165
American National Standards Institute, Inc. 163
Board of Trustees of the Research Fund 163
Editor-Librarian 162
Nominating Committee 165
Secretary-Treasurer 158

Review of 17 Years Experience in Electronystagmography (W. Rubin) 64

S

Scientific Session 13

Sensorineural Deafness, Genetic, in Adults (M. M. Paparella, D. G. Hanson, K. N. Rao, R. Ulvestad) 116

Sensorineural Hearing Loss Due to Cochlear Otospongiosis: Theoretical Considerations of Etiology (F. H. Linthicum, Jr., R. Filipo, S. Brody) 67

Surgery, Acoustic Neuroma, Complications in (M. E. Glasscock III, J. W. Hays, J. P. Murphy) 54

Surgical Lesions with Objective Tinnitus, Operative Treatment of (P. H. Ward, R. Babin, T. C. Calcaterra, H. R. Konrad) 132

T

Temporal Bone Histopathological Findings in Trisomy 13 Syndrome, Abstract (I. Sando, A. Leiberman, L. Bergstrom, S. Izumi, R. P. Wood II) 114

Temporal Bone, Paget's Disease of, Abstract (G. T. Nager) 130

Trisomy 13 Syndrome, Temporal Bone Histopathological Findings in, Abstract (I. Sando, A. Leiberman, L. Bergstrom, S. Izumi, R. P. Wood II) 114

DATE DUE

GAYLORD

PRINTED IN U.S.A.

3 1175 00305 9998

JAN 27 '78

026484

American Otological
Society.
Transactions.

Call Number:

W1
AM806
1975

Nº 026484

American Otological
Society.
Transactions.

W1
AM806
1975

ADV